

# A case report of variant scimitar syndrome

## Case Report

**Kazem Babazadeh (MD)**<sup>1</sup>  
**Hassan Zamani (MD)**<sup>2</sup>  
**Hamidreza Ghaemi (MD)**<sup>1</sup>  
**Forogh Aliakbarnia Omran (MD)**<sup>1\*</sup>

1. Non-Communicable Pediatric Diseases Research Center, Health Research Institute, Babol University of Medical Sciences, Babol, IR Iran.

2. Department of Pediatrics, Shahid Modarres Hospital, Shahid Beheshti University of Medical Sciences, Tehran, Iran.

### \* Correspondence:

**Forogh Aliakbarnia Omran (MD)**  
Non-Communicable Pediatric Diseases Research Center, No 19, Amirkola Children's Hospital, Amirkola, Babol, Mazandaran Province, 47317-41151, IR Iran.

**E-mail:** faano60@gmail.com

**Tel:** +98-11-32346963

**Fax:** +98-11-32346963

**Received:** 28 June 2017

**Revised:** 19 July 2017

**Accepted:** 14 Aug 2017

### Abstract:

**Background:** Scimitar syndrome (SS) or congenital pulmonary venolobar syndrome is a rare anomaly, most commonly including partial pulmonary venous drainage into the inferior vena cava, right lung hypoplasia, dextroposition of the heart, and anomalous systemic arterial supply from aorta or one of its branches to the right lung.

**Case report:** A 10-day-old female infant was referred to our hospital with systolic murmur and tachypnea. Initial chest x-ray suggested cardiomegaly and displacement of cardiac structures into the right hemithorax, and initial echocardiogram indicated patent ductus arteriosus, coarctation of aorta, atrial septal defect, ventricular septal defect in this infant who was diagnosed as having SS.

**Conclusions:** We can consider Scimitar syndrome for infants with tachypnea, cyanosis, intrauterine growth restriction (IUGR) and right lobe opacity in chest x-ray.

**Key Words:** Scimitar Syndrome, Pulmonary venous, Congenital Abnormality, Right lung hypoplasia, Coarctation aorta.

### Citation:

Babazadeh K, Zamani H, Ghaemi H.R, Aliakbarnia Omran F. A case report of variant scimitar syndrome. *Caspian J Pediatr Sep 2017; 3(2): 241-4.*

### Introduction:

Scimitar syndrome (SS) which is a rare, but well-described constellation of cardiopulmonary anomalies, accounting for 0.5-1% of chest x-ray (CXR) and it was first described by Chassinat in 1836<sup>[1]</sup>. SS or congenital pulmonary venolobar syndrome (CPVLS) is a rare and variable malformation of the right lung characterized by an abnormal right sided pulmonary venous drainage into the inferior vena cava, malformation of the right lung abnormal arterial supply and sometimes cardiac malformations such as atrial septal defect (ASD), coarctation of aorta (CA), ventricular septal defect (VSD) and patent ductus arteriosus (PDA)<sup>[1,2]</sup>. The incidence of the related congenital cardiovascular abnormalities is 75% among the infants and about 36% in the pediatric age group<sup>[3]</sup>. Hypoplastic right lung and right pulmonary artery which leads to displacement of cardiac structures into the right hemithorax and characteristically curved anomalous right pulmonary vein which drains into the inferior vena cava and resembles the curved Middle Eastern sword "scimitar"<sup>[4,5]</sup>. Different congenital thoracic abnormalities correlate with this specific type of partial anomalous pulmonary venous return<sup>[4,5]</sup>. Anomalies contain accessory diaphragm, absent or hypoplastic pulmonary artery, absence of inferior vena cava, anomalous systemic arterial supply to the right lung from aorta or one of its branches and bronchopulmonary sequestration, and ectopic kidney in addition to classic findings of SS<sup>[6,7]</sup>. About half patients with SS are asymptomatic or mildly symptomatic when the diagnosis is made despite the varying degrees of pulmonary artery hypertension. Cyanosis is unusual but tachypnea, respiratory distress and recurrent respiratory infections in older children are common<sup>[1,8]</sup>.

Although the diagnosis can be made on a CXR, further imaging is necessary to confirm the diagnosis and illustrate other related abnormalities.

We present the case of a female infant diagnosed in the newborn period, along with a brief review of literature.

### Case Report:

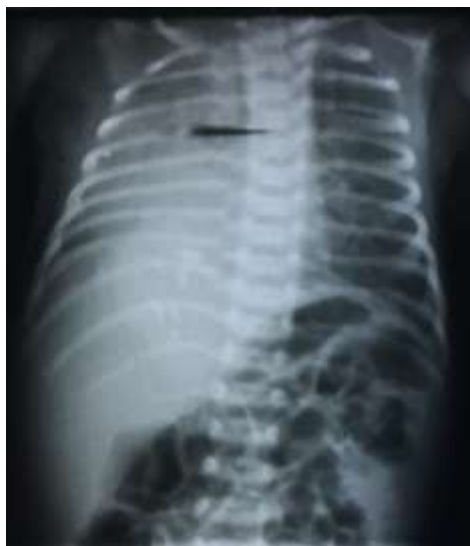A 10-day-old baby was born by caesarean section with a birth weight of 2950 grams of uncomplicated pregnancy.

She was admitted because of the systolic murmur and tachypnea. The initial CXR suggested cardiomegaly and displacement of cardiac structures into the right hemithorax (figure 1). Lab tests were normal. She was treated with oxygen and antibiotics. The initial

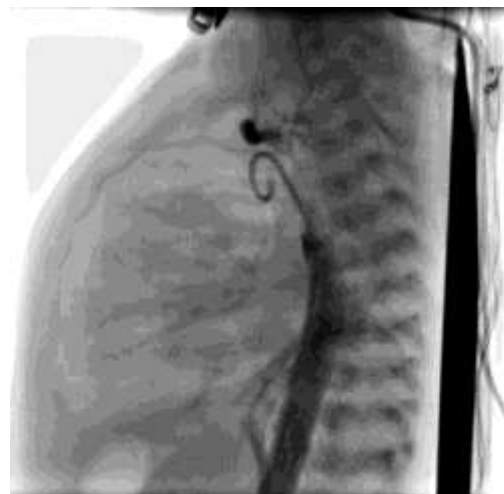echocardiogram showed PDA, CA (figure 2, 3), ASD, VSD, mild PH, TR, MR, and no PS. According to the finding of CXR, SS was diagnosed. Because of COA and PH diagnostic catheterization was performed which revealed SEVER COA, LVH, hypoplastic AO arch, PDA, muscular VSD.

Abdominal aorta angiography illustrated the: a) Bilateral ectopic kidney (right kidney was subdiaphragmatic and left kidney was pelvic) (fig 4), b) Anomalous right lower pulmonary artery (RLPA) originated from abdominal aorta (fig 5), c) Right lower lobe pulmonary sequestration, and d) Anomalous connection of the pulmonary vein that drains into inferior vena cava (IVC).

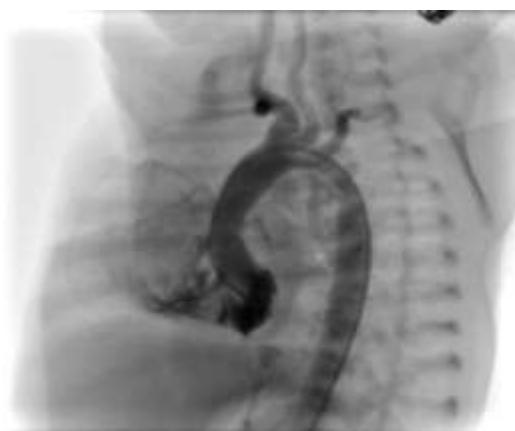The hypoplastic right lung and anomalous pulmonary vein confirmed the diagnosis of CPVLS, also known as syndromes.



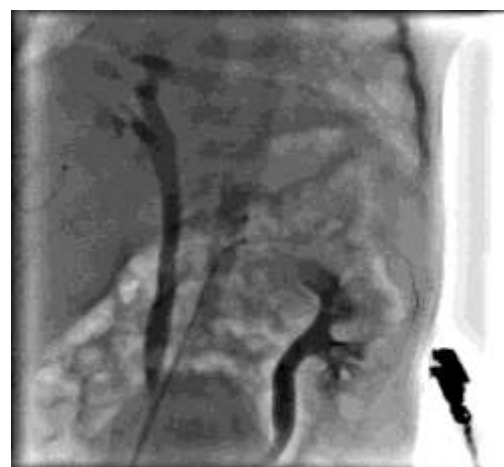
**Figure 1.** Chest radiograph illustrates the cardiomegaly and displacement of cardiac structures into the right hemithorax.



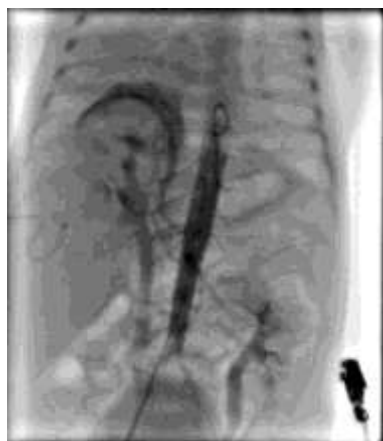**Figure 3.** PDA



**Figure 2:** Coarctation of aorta



**Figure 4.** Abdominal aorta angiography represents the bilateral ectopic kidney (right subdiaphragmatic kidney & left pelvic kidney)



**Figure 5. Anomalous right lower pulmonary artery originated from abdominal aorta**

## Discussion:

We report a patient with cyanosis, tachypnea and systolic murmur.

SS has different presentations based on the age at which the diagnosis is made [1, 6]. Infants usually have severe symptoms of respiratory failure. Cardiac failure and pulmonary hypertension are commonly associated problems. Recurrent respiratory infections and heart murmur may be the presentation [1]. Many of the typical manifestations such as COA, PDA, ASD, PH, right lung hypoplasia, ectopic kidney were present in the present case. Benjouad et al. presented a 6-month-old female infant with acute dyspnea and finally, SS was diagnosed for her [9]. In a study by Ergul et al., SS was diagnosed in a 15-month-old boy after examination for recurrent wheezing and respiratory distress [10].

Rukban et al. reviewed the patients with infantile SS and they found that the median age at presentation and at diagnosis was 14 days and 55 days, respectively and the major presenting symptom was tachypnea [11].

The age of presentation is very variable. In a series of 32 patients, over a period of 20 years, the median age at diagnosis was seven months [1]. Our case was 10-day-old and tachypnea was the first presentation. Classic appearance on CXR is the scimitar sign because the anomalous venous connection causes a curvilinear shadow near to the right heart border that resembles a curved Turkish sword [1]. However, in some patients, the scimitar vein is masked by the overlying cardiac shadow [1]. In this case, curve was seen in angiography. CINE MRI and 3D contrast-enhanced MR angiography provide a non-invasive diagnostic technique in the evaluation of anomalous pulmonary venous return [1, 12]. In this case, anomalous

RLPA originated from abdominal aorta and drainage pulmonary vein into IVC were observed in angiography.

In a case series, Mordue showed right pulmonary vein drainage into the junction of IVC and RA by catheterization [13]. There were also large systemic arterial collateral vessels from the abdominal aorta to the right lower lobe [13]. The case of the current study had bilateral ectopic kidney, while two other case reports stated the infants with SS associated with vertebral defects, anal atresia, cardiac defects, tracheo-esophageal fistula, renal anomalies, and limb abnormalities (VACTERL). It is suggested that the SS should be considered in the VACTERL evaluation [14, 15].

SS occurs more frequently in females and sometimes may be familial [15, 16].

Although there have been a few case reports on the left lung, this is still unknown why it mainly involves the right lung [16]. In general, infants with heart failure have more related anomalies and their prognosis is much worse [6]. The prognosis is better for older children either with or without surgery [6]. Studies based on anatomic material have indicated that the patients with an intact septum and with one pulmonary vein connected anomalously have an excellent prognosis and rarely present with cardiorespiratory symptoms. Treatment for symptomatic SS includes the surgical repair [2, 6]. Surgical repair rarely causes normal blood flow to the right of the lung, but destroys the left-to-right shunt [6].

Especially in neonates, the postoperative pulmonary venous obstruction is prevalent. Therefore, the therapeutic approach for patients with respiratory manifestations, SS and onset beyond the neonatal period should be conservative [6].

In this case, angiography was carried out and transcatheter COA angioplasty was successfully performed using heculink bulloon (size 5\*20 mm). She has been treated with medications (lasix, lanoxin and captopril) and followed by conservative treatment.

In Conclusions, We can consider Scimitar syndrome for infants with tachypnea, cyanosis, intrauterine growth restriction (IUGR) and right lobe opacity in chest x-ray.

## Acknowledgment:

We are grateful to the Clinical Research Development Committee of Amirkola Children's Hospital, Non-Communicable Pediatric Diseases Research Center of

Babol University of Medical Sciences for their contribution to this study.

**Funding:** This study was self-funded.

**Conflict of interest:** There was no conflict of interest.

## References:

1. Sehgal A, Loughran-Fowlds A. Scimitar Syndrome. *Indian J Pediatr* 2005; 72(3): 249-51.
2. Allen HD, Driscoll DJ, Shaddy RE, Feltes TF. Moss & Adams' Heart Disease in Infants, Children, and Adolescents II: Including the Fetus and Young Adult: Lippincott Williams & Wilkins; 2013: 816-817-822.
3. Gikonyo DK, Tandon R, Lucas RV, Edwards JE. Scimitar syndrome in neonates: report of four cases and review of the literature. *Pediatric cardiology*. 1986; 6(4):193-7.
4. Holt PD, Berdon WE, Marans Z, et al. Scimitar vein draining to the left atrium and a historical review of the scimitar syndrome. *Pediatr radiol* 2004; 34(5): 409-13.
5. Frydrychowicz A, Landgraf B, Wieben O, François CJ. Scimitar Syndrome Added Value by Isotropic Flow-Sensitive Four-Dimensional Magnetic Resonance Imaging with PC-VIPR (Phase-Contrast Vastly Undersampled Isotropic Projection Reconstruction). *Circulation* 2010; 121(23): e434-6.
6. Khalilzadeh S, Hassanzad M, Khodayari A-A. Scimitar syndrome. *Arch Iran Med* 2009; 12(1): 79-81.
7. Rokade ML, Ranavavare R, Shetty DS, Saifi S. Scimitar syndrome. *Indian J Pediatr* 2005; 72(3): 245-7.
8. Canter CE, Martin TC, Spray TL, et al. Scimitar syndrome in childhood. *American J Cardiol* 1986; 58(7): 652-4.
9. Benjouad I, Taam I, Ataouna KE, et al. Scimitar syndrome: about a case and review of the literature. *Pan Afr Med J* 2016; 25:37.
10. Ergul Y, Nisli K, Guler N, Aydogan U. A rare cause of recurrent wheezing and respiratory distress: Scimitar syndrome. *Turk Kardiyoloji Derneginin yayin organidir* 2011; 39(7): 595-8.
11. Al Rukban H, Al Ghaihab M, Tamimi O, Al-Saleh S. Clinical spectrum of infantile scimitar syndrome: A tertiary center experience. *Ann Pediatr Cardiol* 2014; 7(1): 29-33.
12. Ferrari VA, Reilly MP, Axel L, Sutton MG. Scimitar syndrom. *Circulation* 1998; 98: 1583-4.
13. Mordue BC. A case series of five infants with scimitar syndrome. *Advanc Neon Care* 2003; 3(3): 121-32.
14. Takawira FF, Omar F. Unusual variant of scimitar syndrome associated with an absent right pulmonary artery, stenosis of the inferior vena cava, hemi-azygous continuation and the VACTERL association: case report-online article. *Cardiovascular J Africa* 2013; 24(3): 3-6.
15. Fritz CJ, Reutter HM, Herberg U. Scimitar syndrome in a case with VACTERL association. *Cardiol Young* 2015; 25(3): 606-9.
16. Rutledge JM, Hiatt PW, Wesley Vick G, 3rd, Grifka RG. A sword for the left hand: an unusual case of left-sided scimitar syndrome. *Pediatr Cardiol* 2001; 22(4): 350-2.