

Central Nervous System Burkitt Lymphoma in a child (A case report)

Case Report

Hassan Mahmoodi Nesheli (MD) ^{1*}

1. Non-Communicable Pediatric Diseases
Research Center, Health Research
Institute, Babol University of Medical
Sciences, Babol, IR Iran.

* Correspondence:

Hassan Mahmoodi Nesheli,
Hematologist, Non-Communicable
Pediatric Diseases Research Center,
No 19, Amirkola Children's
Hospital, Amirkola, Babol,
Mazandaran Province, 47317-41151,
IR Iran

E-mail: mahmoodi86@yahoo.com

Tel: +98 1132346963

Fax: +98 1132346963

Received: 25 April 2015

Revised: 8 May 2015

Accepted: 6 June 2015

Abstract

Introduction: Burkitt lymphoma (BL) is rare, but an aggressive malignancy. Central nervous system Burkitt lymphoma (CNSBL) is very rare. CNS Burkitt's lymphoma is treated with high-dose chemotherapy and radiation. Radiotherapy in children younger than three years old may cause major CNS damage.

Case report: A three-year-old boy presented with painful proptosis of the left eye. He underwent adenoidectomy 2 months before admitted to our center. Sleep difficulty was not resolved after surgery. Microscopic study of paranasal sinus biopsy and IHC confirmed the diagnosis of Burkitt Lymphoma.

Conclusions: In any patients presenting with painful proptosis, BL should be considered. Adenoid hyperplasia should not be considered as a sole cause of sleep difficulty.

Keywords: Burkitt Lymphoma, Adenoid Hyperplasia, CNS Tumor, Non-Hodgkin Lymphomas

Citation:

Central Nervous System Burkitt Lymphoma in a child, (A case report). Mahmoodi Nesheli H. Caspian J Pediatr Sep 2015; 1(2): 77-81.

Introduction

Non-hodgkin lymphomas is an uncommon cancer in children younger than 5 year ^[1]. Burkitt lymphoma (BL) (a form of B-cell non-Hodgkin lymphoma) is rare, but an aggressive malignancy with a tendency to disseminate to the bone marrow and meninges ^[2]. Central nervous system involvement with non-Hodgkin lymphoma (NHL) occurs in about 12% of children with BL ^[3]. Primary central nervous system, Burkitt lymphoma, is very rare ^[4-7]. Burkitt's lymphoma was first discovered in equatorial Africa ^[1]. The most common places in the body for the disease to start in African children are the jaw, abdomen, but non African type Burkitt's lymphoma tends to start in the abdomen and bone marrow. BL can affect tonsils and adenoids, too ^[8-9]. The tumor is very aggressive and can grow rapidly and make large masses. The mass can press on other organs, causing a number of very serious fatal complications, including airway obstruction, arrhythmias ^[10], obstruction or perforation of the bowel, renal tract obstruction, superior vena cava obstruction. CNS BL can cause increased intracranial pressure, headaches, vision problems, nausea and/or vomiting. BL may be diagnosed by blood test, bone marrow aspiration and/or biopsy, lymph node biopsy, abdominal fluid analysis, pleural fluid analysis and rarely paranasal sinus biopsy. Chest x-ray, bone scan and other imaging study are necessary to determine the extent of disease to select the best treatment. CNS Burkitt's lymphoma is treated with high-dose chemotherapy and radiation ^[11].

Case presentation

A three-year-old boy presented with left neck region mass and painful proptosis of the left eye. He complained intermittent blunt headache for 1 month. He underwent surgery for adenoid hyperplasia about 2 months ago, because the patient had respiratory problem at the time of sleeping on that time. Brain MRI showed massive lesion in retro bulbar region extended to Para nasal sinus and temporal lobe. MRI indicated bone destruction in sella turcica region too (Fig 1).

Paranasal sinus biopsy was done for him. Microscopic study showed small round cell tumors, more suggestion was Rhabdomyosarcoma. The clinical aspect was compatible with Rhabdomyosarcoma (RMS), but immune histochemistry suggested the expression of CD 10 and a Ki-67 proliferation fraction of virtually more than 90% which were compatible with BL.

Bone marrow aspiration and biopsy were normal. CSF analysis was normal, too. Plain Chest X Ray, Chest CT scan and abdominal CT scan were normal. Intensive chemotherapy (BFM-90) and intrathecal (IT) chemotherapy were initiated. Chemotherapy reduced the neck region mass rapidly but deficits partially improved in the visual acuity and proptosis. Unfortunately, after 1 year intensive chemotherapy, CSF showed many blast cells.

Plain Chest X Ray, Chest CT scan and abdominal CT scan were normal again. Bone marrow aspiration, bone marrow biopsy and flow cytometry were normal again. The patient was treated with intrathecal three times a week and despite of his low age, radiotherapy was considered. Surprisingly control MRI became normal in compare with first assessment (Figure 2). CSF became normal again after treatment. The patient is in complete remission now.

Discussion

A few cases of Central Nervous System Burkitt Lymphoma (CNSBL) in children have been reported in English literature [12-16]. Many cases who reported in the literature were not younger than 5 years old, whereas our case was very young (3 years old). Our study like as other researches showed that in any patient presenting with painful proptosis and vision

loss or blunt headache, a diagnosis of BL should be considered [17, 18]. Burkitt's lymphoma is an important cause of childhood blindness in Nigeria and the orbital disease is mainly extra ocular [19].

In our patient, cranial nerve palsy including six and seven nerve palsy occurred as a cause of vision problem. Our study showed indicated that adenoid hyperplasia should not be considered as a sole cause of sleep difficulty and respiratory problem. Because of diagnostic and therapeutic difficulties of Non-Hodgkin lymphomas of the nasopharynx in children, the physician should be aware of nasopharyngeal problems. Lymphomas of nasopharynx and CNS BL in a child such as our patient cause diagnostic problems because of their early stage pseudo inflammatory manifestation. Special attention should be paid to perform imaging studies (MRI/CT), which are useful in reaching the proper diagnosis [20]. In one study, BL misdiagnosed as advanced retinoblastoma because of globe invasion and destruction [21].

The presentation of rhabdomyosarcoma was supposed to be in that study as our study. The correct diagnosis was obtained from the histology of the extenterated eye in both studies. Preoperative therapeutic trial was chemotherapeutic agents in such cases suggested to avoid unnecessary exenteration.

Although the treatment regimens are different including surgery, radiotherapy, and systemic and intrathecal chemotherapy, intensive short-course chemotherapy combining with intrathecal injection regimen are recommend to treat systemic BL [22], whereas for Central Nervous System Lymphoma (CNSL), the high-dose MTX-based chemotherapy regimen has been commonly used. Chemotherapy after using cranial radiotherapy improves median disease-free and overall survival of up to 30 to 40 months from the survival of 12 to 18 months [23].

Our case is in remission after radiotherapy. Moreover, a pediatric series of CNSL has reported that immunocompetent and immunodeficient children with CNSL may be cured with chemotherapy alone without CRT. However, treatment of young age patient is very difficult for drug toxicity and impossibility of radiotherapy. Our patient experienced many time hospitalization even mechanical ventilation due to drug toxicity and infections [24].

Today's, despite of progression of chemotherapy in Non-Hodgkin Lymphomas, CNS involvement or poor response to chemotherapy was worse prognostic factors; therefore, future studies addressing this

therapeutic challenge are warranted. Because of rapid progression of BL and considering that it responds well to treatment, if the disease is diagnosed at early stages,

a diagnostic work-up including a tissue biopsy should be initiated immediately after BL is suspected.

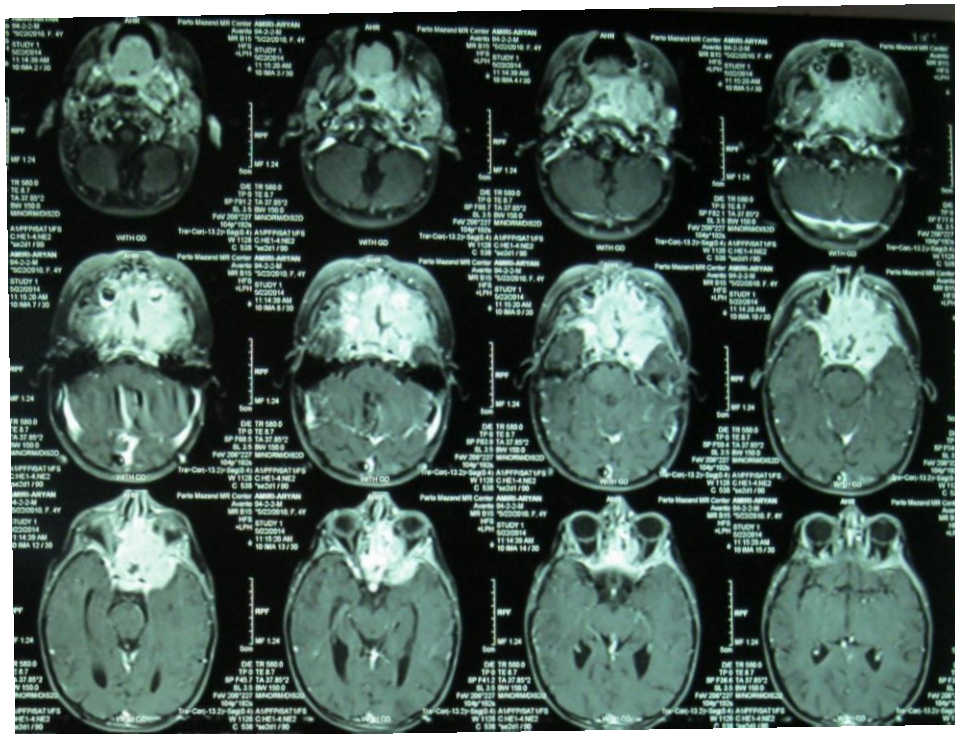


Fig 1: Brain MRI of patient with CNS BL

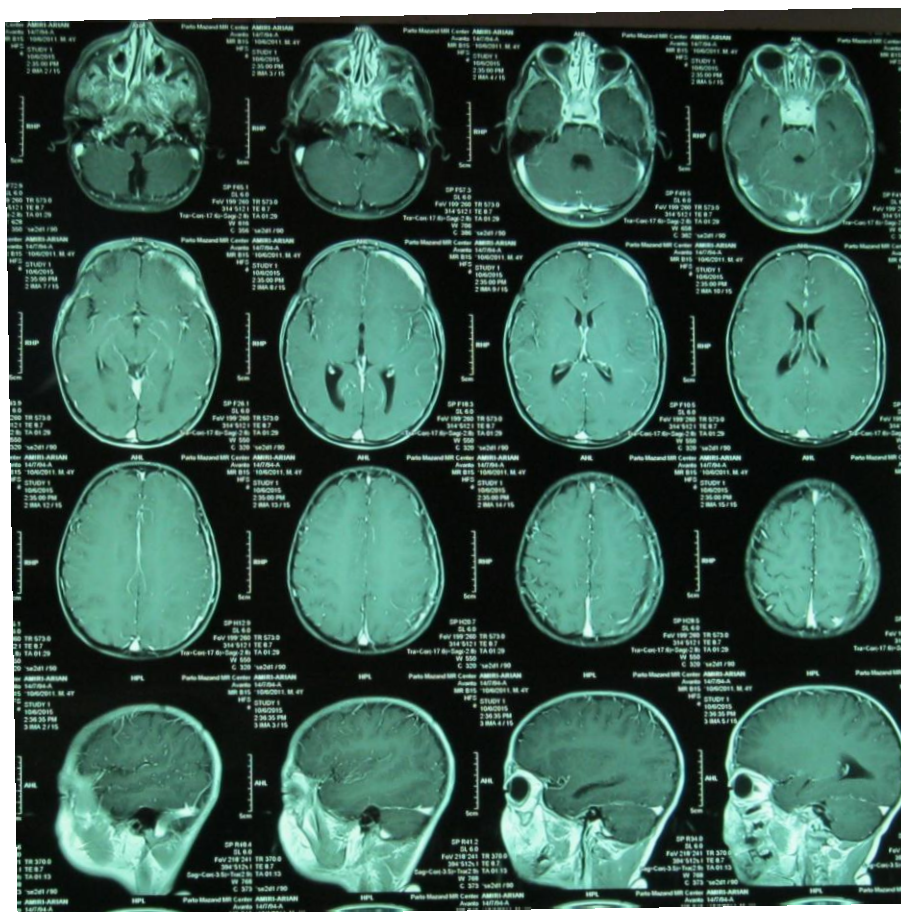


Fig 2: Brain MRI of patient with CNS BL after treatment

Acknowledgment

We are grateful to the Clinical Research Development Committee of Amirkola Children's Hospital, the Research Council and Non communicable Pediatric Diseases Research Center, Health Research Center Babol University of Medical Sciences for their support and cooperation with study.

Funding: This study was self-funded.

Conflict of interest: There was no conflict of interest.

References

1. Pizzo PA, Poplack DG. Principles and Practice of Pediatric Oncology: 6th ed Wolters Kluwer Health/Lippincott Williams & Wilkins; 2011: 722-3.
2. Non-Hodgkin's lymphoma, National Comprehensive Cancer Network (NCCN) clinical practice guidelines in oncology; V.1.2010: MS-21. Available at: <http://parto-rt.com/pdf/nhl.pdf>
3. Cairo MS, Sposto R, Perkins SL, et al. Burkitt's and Burkitt-like lymphoma in children and adolescents: a review of the Children's Cancer Group experience. *Br J Haematol* 2003; 120(4): 660-70.
4. Gupta R, Yadav JS, Yadav S, Wadood A. Orbital involvement in nonendemic Burkitt's lymphoma. *Orbit* 2012; 31(6): 441-5.
5. Giuliani GP, Sadaka A, Cortez MA, Paniagua A. Orbital Burkitt's Lymphoma: An Aggressive Presentation. *Case Rep Ophthalmol Med* 2012; 2012: 354043. Available at: <http://www.hindawi.com/journals/criopm/2012/354043/>
6. Carmody J, Misra RP, Langford MP, et al. Orbital sporadic Burkitt lymphoma in an adult diabetic African American female and a review of adult orbital cases. *Clin Ophthalmol* 2011; 5: 509-15. Available at: <https://www.dovepress.com/orbital-sporadic-burkitt-lymphoma-in-an-adult-diabetic-african-america-peer-reviewed-article-OPHTH>
7. Prall FR, Hink EM, Liang X, Durairaj VD. Rapid onset proptosis and vision loss as the initial presentation of Burkitt lymphoma. *Ophthalmic Surg Lasers Imaging* 2008; 39(4): 331-4.
8. Edelstein C, Shields JA, Shields CL, et al. Non-African Burkitt lymphoma presenting with oral thrush and an orbital mass in a child. *Am J Ophthalmol* 1997; 124(6): 859-61.
9. Philip T, Bergeron C, Frappaz D. Management of paediatric lymphoma. *Baillieres Clin Haematol* 1996; 9(4): 769-97.
10. Montanaro C, Loiacono F, Fragasso G, et al. Primary Cardiac Lymphoma in an Immunocompetent 71-Year-Old Man. *Tex Heart Inst J* 2015; 42(6): 561-4.
11. Yoon JH, Kang HJ, Kim H, et al. Successful treatment of primary central nervous system lymphoma without irradiation in children: single center experience. *J Korean Med Sci* 2012; 27(11): 1378-84.
12. Gu Y, Hou YY, Zhang XB, Hu F. Primary central nervous system Burkitt lymphoma as concomitant lesions in the third and the left ventricles: a case study and literature review. *J Neurooncol* 2010; 99(2): 277-81.
13. Kobayashi H, Sano T, Ii K, Hizawa K. Primary Burkitt-type Lymphoma of the central nervous system. *Acta Neuropathol* 1984; 64(1): 12-4.
14. Silfen ME, Garvin JH Jr, Hays AP, et al. Primary central nervous system lymphoma in childhood presenting as progressive panhypopituitarism. *J Pediatr Hematol Oncol* 2001; 23(2): 130-3.
15. Wilkening A, Brack M, Brandis A, et al. Unusual presentation of a primary spinal Burkitt's lymphoma. *J Neurol Neurosurg Psychiatry* 2001; 70(6): 794-7.
16. Monabati A, Rakei SM, Kumar P, et al. Primary Burkitt lymphoma of the brain in an immunocompetent patient. Case report. *J Neurosurg* 2002; 96(6): 1127-9.
17. Shehu BB. Primary central nervous system Burkitt's lymphoma presenting with proptosis. *Ann Trop Paediatr* 2003; 23(4): 319-20.
18. Alexander C, George C, Tinatin J, et al. Orbital Burkitt lymphoma: a case presentation. *BMC Ophthalmol* 2014; 14: 109. doi: 10.1186/1471-2415-14-109
19. Adeoye AO, Durosinmi MA, Adeodu OO, et al. Ocular manifestations of Burkitt's lymphoma: experience in Ile-Ife south western Nigeria. *West Afr J Med* 2007; 26(1): 48-52.
20. Zawitkowska-Klaczynska J, Dudkiewicz E, Stefaniak J, et al. Non-Hodgkin lymphomas of the nasopharynx in children--diagnostic and therapeutic difficulties. *Pol Merkur Lekarski* 2004; 17(101): 471-3.
21. McMoli TE, Ogunmekan AO, Odunjo EO. Orbital Burkitt's tumor presenting as advanced

- retinoblastoma. *J Pediatr Ophthalmol Strabismus* 1980; 17(3): 147-9.
22. Mead GM, Sydes MR, Walewski J, et al. An international evaluation of CODOX-M and CODOX-M alternating with IVAC in adult Burkitt's lymphoma: results of United Kingdom Lymphoma Group LY06 study. *Ann Oncol* 2002; 13(8): 1264-74.
23. Abrey LE, Yahalom J, DeAngelis LM, et al. Treatment for primary CNS lymphoma: the next step. *J Clin Oncol* 2000; 18(17): 3144-50.
24. Abla O, Sandlund JT, Blaser S, et al. Primary Central Nervous System Lymphoma in Children: A Report of 12 Cases. *Blood* 2004; 104(suppl): 901a.