

A case report of nephrotic syndrome with hemorrhage of intracerebral in cerebral venous thrombosis

Case Report

Ali Nikkhah (MD)¹
Roghayeh Akbari (MD)^{*2}
Hadi Sorkhi (MD)³

1. Non-Communicable Pediatric Diseases Research Center, Health Research Institute, Department of Pediatric neurology, Amirkola Children's Hospital, Babol University of Medical Sciences, Babol, IR Iran.
2. Department of Nephrology, Shahid Beheshti Hospital, Babol University of Medical Sciences, Babol, IR Iran.
3. Non-Communicable Pediatric Diseases Research Center, Health Research Institute, Department of Pediatric Nephrology, Amirkola Children's Hospital, Babol University of Medical Sciences, Babol, IR Iran.

* Correspondence:

Roghayeh Akbari,
Department of Nephrology, Shahid Beheshti Hospital, Babol University of Medical Sciences, Babol, 47317-41151, Iran.

E-mail: roghayeh.akbari@yahoo.com

Tel: +98 1132346963

Fax: +98 1132257899

Received: 20 April 2015

Revised: 6 May 2015

Accepted: 3 June 2015

Abstract

Introduction: Cerebral vein thrombosis is a rare complication of nephrotic syndrome (NS). We report a known case of NS with hemorrhagic thrombosis.

Case report: A boy with previous history of NS was admitted with headache and decrease of level of consciousness and his brain images were revealed hemorrhagic thrombosis

Conclusions: Cerebral vein thrombosis must be considered in patients with history of NS (especially in new cases and during of relapses) and prevention of hemoconcentration is very important to decrease thrombosis risk.

Keywords: Children, Nephrotic Syndrome, Thrombosis, Central Nervous System

Citation:

Nikkhah A, Akbari R, Sorkhi H. A case report of nephrotic syndrome with hemorrhage of intracerebral in cerebral venous thrombosis. *Caspian J Pediatr Sep 2015; 1(2): 73-76.*

Introduction

Nephrotic syndrome (NS) is defined by heavy proteinuria, hyperlipidemia, hypoalbuminemia, and generalized edema. It is a common nephrologic disorder in childhood [1-2]. One of the major problems in this disorder is hypercoagulopathy and increased risk of thrombosis [3-5]. About ten percent of adult and about 5% of children with N.S have a history of thrombosis [6]. The cause of thrombosis is related to an imbalance of coagulations and anti-coagulations factors. The risk is increased by thrombocytosis, hemoconcentration, hyperviscosity, decrease of physical activity, use of corticosteroids and diuretics [7-10]. The risk of vein thrombosis is more than arterial one [11]. The rate of cerebral venous vessels thrombosis is rare complication especially in children. Because of nonspecific sign and symptom of central nervous system (CNS) thrombosis in children with NS, the diagnosis may be occurred with delay. Therefore, any child with NS and CNS manifestations must be considered as CNS thrombosis [12-13]. For this reasons, we report a 12 year old boy with relapse of NS and CNS manifestations with diagnosis of CNS thrombosis.

Case presentation

An 8 year old boy with history of nephrotic syndrome since 3.5 years old has presented with generalized edema, several times vomiting, decrease of urine output, fever, headache (since 3 days ago) and decrease level of consciousness. At the time of admission, his temperature and blood pressure were 38.5^{oC} and 70/105 mmHg, respectively. He had abdominal tenderness and pitting edema of lower extremities. He was on remission one week before admission, but after an upper respiratory infection, urinalysis was showed 3 + protein and then treatment with prednisolone was started.

After admission, urinalysis showed 3+ protein, blood urea nitrogen and creatinine were 20 mg/dL and 0.58 mg/dL, respectively. He had hemoconcentration (hemoglobin: 17g/dL, hematocrit: 52.5%). Serum sodium (136 mEq/L) and potassium (3.8 mEq/L) were normal. PT and PTT were in normal ranges.

He was admitted with impressions of pseudotumor cerebri and bacterial infection. Then antibiotic (cefotaxim) was recommended and serum for correction of hypovolemia was started. The ophthalmologic exam didn't show edema of pupil and he had normal exam. An emergency non-contrast Computed tomography scan (CTS) of brain was done and it revealed hyperdense shadow in posterior fossa and suggested sagittal sinus of hemorrhage or thrombosis (Fig 1). Then Magnetic resonance imaging (MRI) of brain was performed and showed left occipital sinuvenous thrombosis (Fig 2).

The patient had no neurologic focal signs and there was not any abnormal neurologic exam. The conservative management was done with correction of water and electrolytes continue of antibiotics. Dose of dexamethasone was decreased to 4mg/kg/BID and conservative management was done for him. He did not have any increase in creatinine in period of admission and his headache was alleviated after two days of admission. He was well one week after admission and discharged with neurologic and nephrologic flow up.

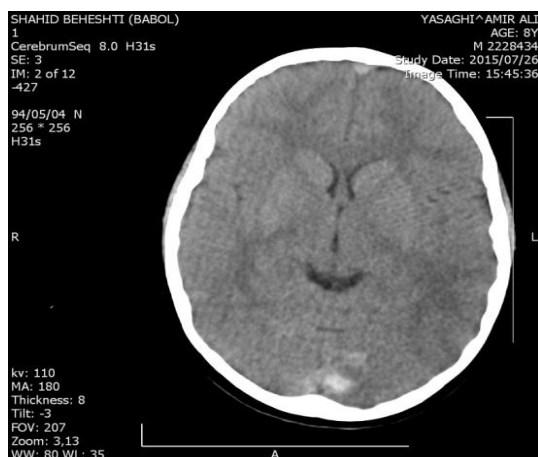


Fig 1: Brain CTS of patient with hemorrhagic thrombosis and nephrotic syndrome

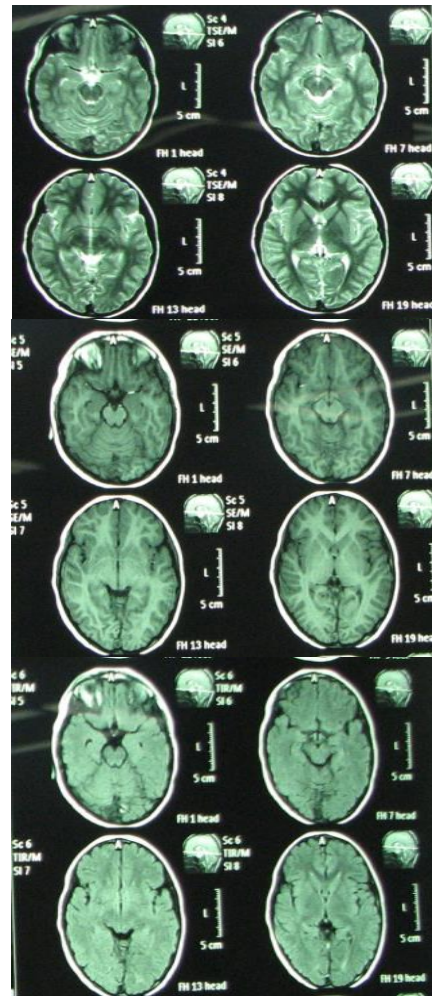


Fig 2: Brain MRI of patient with hemorrhagic thrombosis and nephrotic syndrome

Discussion

Decrease of intra vascular volume due to edema of nephrotic syndrome, vomiting and fever may causes of hemoconcentration (hemoglobin: 17 gr/dL) in this patient and increase the risk of thrombosis. Thrombosis of cerebral vessel is very rare in nephritic syndrome especially in children [13]. The risk of thrombosis is higher in new cases and during relapse for decrease of intravascular volume [14]. The other factor suggested to increase the risk of thrombosis is hypercoagulability [13, 15-16]

Decrease serum level of low molecular weight coagulation factors (factors IX, XI) resulting from increase urine loss has been reported [16-17]. Of course, serum level of high molecular precouagulation factors (factor V, VII, VIII, X) and fibrinogen were increased. The low plasma level of antithrombin III more than 70% of normal was reported by Kauffmann [13]. This

factor has a urinary loss and its plasma level may be related to serum albumin level. Increase platelet activation and then thromboembolic complication have been reported in children with new cases or relapse of nephrotic syndrome [18-19]. The other factor that was suggested to play a role in increase thrombosis is protein Z (PZ). PZ is a single chain vitamin K – dependent glycoprotein. Therefore, PZ deficiency was reported in nephrotic syndrome and might increase the risk of thrombosis. [20-22]

The clinical presentation of cerebral venous thrombosis may be different in signs and symptoms. Our patient had low level of consciousness and severe headache. However, he did not have neurological exam abnormality that probably may be due to small lesion. He had occipital lobe involvement that was very small.

Central vein thrombosis may be seen with early diagnosis and treatment [23-24]. The first investigation is CTS and then MRI and MRV (Magnetic Resonance Venography) [25].

In our patient, the CTS indicated hyperdense lesion in posterior sagittal sinus and thrombotic hemorrhage in left occipital lobe. In addition, in his brain MRI, a small thrombotic hemorrhage was seen in occipital lobe (fig 1, 2). Our patient was treated by dexamethasone and correction of hypovolemia and his condition was better and he was discharged without any neurologic deficit. There is controversy on anticoagulant therapy in children with NS and thrombosis [9]. Heparin is recommended for these patients and may be safe in children [26]. Because antithrombin III is decreased via urinary loss and increase catabolism, the replacement of these factors may be helpful [27].

In conclusion, cerebral vein thrombosis must be considered in any patients with the history of NS and especially in new cases and during of relapses, and the prevention of hemoconcentration is very important to decrease the thrombosis risk.

Acknowledgment

We are grateful to the Clinical Research Development Committee of Amirkola Children's Hospital, the Research Council and Non communicable Pediatric Diseases Research Center, Health Research Center Babol University of Medical Sciences and Kidney Transplantation ward for their support and cooperation with study.

Funding: This study was self-funded.

Conflict of interest: There was no conflict of interest.

References

1. Eddy AA, Symons JM. Nephrotic syndrome in childhood. *Lancet* 2003; 362(9384): 629-39.
2. Sorkhi H, Alavi E, Bijani A. Corticosteroid response in children with nephrotic syndrome, Amirkola Children Hospital, 1994-2001. *J Babol Med Sci* 2002; 4(3): 39-43
3. Hogg RJ, Portman RJ, Milliner D, et al. Evaluation and Management of Proteinuria and Nephrotic Syndrome in Children: Recommendations From a Pediatric Nephrology Panel Established at the National Kidney Foundation Conference on Proteinuria, Albuminuria, Risk, Assessment, Detection, and Elimination. *Pediatr* 2000; 105(6): 1242-9.
4. Zaffanello M, Franchini M. Thromboembolism in childhood nephrotic syndrome: a rare but serious complication. *Hematol* 2007; 12(1): 69-73.
5. Kayali F, Najjar R, Aswad F, et al. Venous thromboembolism in patients hospitalized with nephrotic syndrome. *Am J Med* 2008; 121(3): 226-30.
6. Mehls O, Andrassy K, Koderisch J, et al. Hemostasis and thromboembolism in children with nephrotic syndrome: differences from adults. *J Pediatr* 1987; 110(6): 862-7.
7. Yun YW, Chung S, You SJ, et al. Cerebral infarction as a complication of nephrotic syndrome: a case report with a review of the literature. *J Korean Med Sci* 2004; 19(2): 315-9.
8. Ozkayin N, Mir S, Kavakli K. Hypercoagulability risk factors in children with minimal change disease and the protective role of protein-C activity. *Int Urol Nephrol* 2004; 36(4): 599-603.
9. Singhal R, Brimble KS. Thromboembolic complications in the nephrotic syndrome: pathophysiology and clinical management. *Thromb Res* 2006; 118(3): 397-407. Epub 2005 Jun 28.
10. Citak A, Emre S, Sâirin A, et al. Hemostatic problems and thromboembolic complications in nephrotic children. *Pediatr Nephrol* 2000; 14(2): 138-42.
11. Andrew M, Brooker LA. Hemostatic complications in renal disorders of the young. *Pediatr Nephrol* 1996; 10(1): 88-99.
12. Fluss J, Geary D, deVeber G. Cerebral sinovenous thrombosis and idiopathic nephrotic syndrome in childhood: report of four new cases and review of

- the literature. *Eur J Pediatr* 2006; 165(10): 709-16. Epub 2006 May 12.
13. Gangakhedkar A, Wong W, Pitcher LA. Cerebral thrombosis in childhood nephrosis. *J Paediatr Child Health* 2005; 41(4): 221-4.
 14. De Mattia D, Penza R, Giordano P, et al. Thromboembolic risk in children with nephrotic syndrome. *Haemostasis* 1991; 21(5): 300-4.
 15. Llach F, Koffler A, Finck E, Massry SG. On the incidence of renal vein thrombosis in the nephrotic syndrome. *Arch Intern Med* 1977; 137(3): 333-6.
 16. Kanfer A, Kleinknecht D, Broyer M, Josso F. Coagulation studies in 45 cases of nephrotic syndrome without uremia. *Thromb Diath Haemorrh* 1970; 24(3): 562-71.
 17. Kendall AG, Lohmann RC, Dossetor JB. Nephrotic syndrome. A hypercoagulable state. *Arch Intern Med*. 1971 Jun;127(6):1021-7.
 18. Tkaczyk M, Baj Z. Surface markers of platelet function in idiopathic nephrotic syndrome in children. *Pediatr Nephrol* 2002; 17(8): 673-7. Epub 2002 May 17.
 19. Wasilewska AM, Zoch-Zwierz WM, Tomaszewska B, Biernacka A. Platelet-derived growth factor and platelet profiles in childhood nephrotic syndrome. *Pediatr Nephrol* 2005; 20(1): 36-41. Epub 2004 Oct 13.
 20. Ozkaya O, Bek K, Fişgin T, et al. Low protein Z levels in children with nephrotic syndrome. *Pediatr Nephrol* 2006; 21(8): 1122-6.
 21. Al-Shanqeeti A, van Hylckama Vlieg A, Berntorp E, et al. Protein Z and protein Z-dependent protease inhibitor. Determinants of levels and risk of venous thrombosis. *Thromb Haemost* 2005; 93(3):411-3.
 22. Vasse M, Guegan-Massardier E, Borg JY, et al. Frequency of protein Z deficiency in patients with ischaemic stroke. *Lancet* 2001; 357(9260): 933-4.
 23. Masson C, Colombani JM. Cerebral venous thromboses. *Presse Med* 1999; 28(28): 1547-52.
 24. Torres RA, Torres BR, de Castilho AS, Honorato R. Venous sinus thrombosis in a child with nephrotic syndrome: a case report and literature review. *Rev Bras Ter Intensiva* 2014; 26(4): 430-4
 25. Lafitte F, Boukobza M, Guichard JP, et al. MRI and MRA for diagnosis and follow-up of cerebral venous thrombosis (CVT). *Clin Radiol* 1997; 52(9): 672-9.
 26. de Saint-Martin A, Terzic J, Christmann D, et al. Superior sagittal sinus thrombosis and nephrotic syndrome: favorable outcome with low molecular weight heparin. *Arch Pediatr* 1997; 4(9):849-52.
 27. Zaffanello M, Brugnara M, Fanos V, Franchini M. Prophylaxis with AT III for thromboembolism in nephrotic syndrome: why should it be done? *Int Urol Nephrol* 2009; 41(3): 713-6.