

## Maternal Blood Hemoglobin Electrophoresis for Detecting Fetal Hemoglobin in Severe Fetomaternal Hemorrhage: A Case Report

Hossein Ghorbani <sup>1</sup>, Mohsen Haghshenas Mojaveri <sup>2</sup>, Samira Pournajaf <sup>3</sup>,  
Zahra Akbarian-rad <sup>3\*</sup>

1. Clinical Research Development Unit of Rouhani Hospital, Babol University of Medical Sciences, Babol, Iran.

2. Clinical Research Development Unit of Amirkola Children's Hospital, Babol University of Medical Sciences, Babol, Iran.

3. Non-Communicable Pediatric Diseases Research Center, Health Research Institute, Babol University of Medical Sciences, Babol, Iran.

\*Corresponding Author: Dr. Zahra Akbarian-rad;

Address: Non-Communicable Pediatric Diseases Research Center, No 19, Amirkola Children's Hospital, Amirkola, Babol, Mazandaran Province, 47317-41151, IR Iran.

Tel-Fax: +98 1132346963

E-mail: zhr\_akbarian@yahoo.com

### Article Info.

#### Article type:

#### Case Report

Received: 7 Sep. 2025

Revised: 26 Nov. 2025

Accepted: 7 Dec. 2025

Published: 10 Dec. 2025

#### Keywords:

Anemia, Neonatal;

Electrophoresis;

Fetal Hemoglobin;

Fetomaternal Transfusion;

Kleihauer-Betke Test

### ABSTRACT

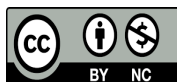
**Background and Objective:** Massive form of fetomaternal hemorrhage (FMH) is a rare event in pregnancy, and it is a crucial cause of severe neonatal anemia at birth. The standard test for detecting fetal red cells in maternal blood is the Kleihauer-Betke test (KBT). In this case, we detected fetal hemoglobin (HbF) by electrophoresis of the maternal blood.

**Case Report:** A male neonate with gestational age 37<sup>+6</sup> weeks was born by cesarean section (C/S) due to decreased fetal activity that occurred since 16 hours before delivery and a non-reactive non-stress test (NST). The baby received positive pressure ventilation due to no breath and hypotonia at birth. The baby's skin was severely pale, with no signs of edema, ecchymosis, petechiae, hepatosplenomegaly, or ascites. An emergency complete blood cell count (CBC) revealed a hemoglobin (Hb) level of 3.1 g/dL and a hematocrit of 11.1%. After transferring the patient to the neonatal intensive care unit, blood transfusion was performed according to protocol. As the KBT was not available, we detected HbF in the maternal blood by Hb Electrophoresis (HbF=5.3%). The baby was discharged in good clinical condition, and there was no clinical problem for his mother.

**Conclusion:** Maternal blood Hb electrophoresis can be helpful for the diagnosis of FMH if an expert in KBT is not available.

#### Cite this Article:

Ghorbani H, Haghshenas Mojaveri M, Pournajaf S, Akbarian-rad Z. Maternal Blood Hemoglobin Electrophoresis for Detecting Fetal Hemoglobin in Severe Fetomaternal Hemorrhage- A Case Report. *Caspian J Pediatr* June 2025; 11: e14.



## Introduction

The passage of fetal red blood cells (RBCs) into the maternal circulation is known as fetomaternal hemorrhage (FMH), and it was first described by Weiner in 1948 [1]. The frequency of blood transfusions increases with gestational age and peaks at birth [2]. FMH occurs in 96% of pregnancies and in most of them is less than 1ml [3]. Massive FMH is defined as the transfusion of blood exceeding 150 ml, which is a very rare occurrence [4]. Fetal anemia presents when the volume of transfusion exceeds 25-30 mL [1].

Fetal anomalies, multiple fetuses, and intrauterine demise are risk factors for FMH. Maternal causes of FMH, such as placenta previa or abruption, umbilical vein thrombosis, trauma, or obstetric intervention, are the main reasons for this problem. [5, 6]. Fetal outcome depends on the volume of transfused blood and the presence of acute or chronic blood loss. [2]. Reduced or absence of fetal movement is the most common presenting symptom in cases of massive FMH [1-3, 5, 7].

Maternal symptoms such as transfusion reaction (chills, fever, and nausea) may present in some cases of massive FMH [2]. Non-stress test (NST) or cardiotocography (CTG) may show a nonspecific deceleration, and a sinusoidal pattern would be seen in fetal anemia [2]. Other findings in CTG may include late deceleration, absent acceleration, and fetal tachycardia. However, CTG and biophysical profile (BPP) may be normal if the fetus compensates for the transfusion [8]. Peak systolic velocity (PSV) in the middle cerebral artery (MCA) can aid in monitoring fetal anemia. Indeed, a decrease in hemoglobin (Hb) in the fetus is associated with an increase in MCA-PSV [8, 9].

Keilhauer–Betke acid elution test (KB) is a blood test used to measure the amount of fetal hemoglobin (HbF) transferred from a fetus to a mother's bloodstream. This test requires a skilled and experienced person to perform it accurately and report the results correctly. Flow cytometry and high-performance liquid chromatography (HPLC) are other ways for detecting fetal RBC in maternal circulation [10-12]. Hemoglobin electrophoresis (HE) is a simple, low-cost, and more available test for detecting Hb types in the circulation, but there are

limited studies on the use of HE to detect HbF in maternal blood [13]. In this presenting case, we used HE for the diagnosis of FMH because we didn't have access to a skilled person to administer the standardized test.

## Case Presentation

**Maternal history:** A 27-year-old primigravid female with gestational age 37<sup>+6</sup> weeks was admitted in labor due to a history of decreased fetal activity since 16 hours before admission, and a non-reactive NST. She received good prenatal care (PNC) and showed no evidence of anemia before pregnancy (Hemoglobin=12.5, Hematocrit=37.5, RBC=4.34, MCV=86.4, MCH=28.8, MCHC=33.3). There was no history of vaginal bleeding and trauma before admission. Emergency cesarean section (C/S) was down, and a male baby was born.

**Delivery Room and Resuscitation:** The neonate received positive pressure ventilation due to the absence of spontaneous respiration and hypotonia. He started breathing after 20 seconds, and the Apgar score was 8 of 10 at 5 minutes. The baby was severely pale, and he had respiratory distress (nasal flaring, subcostal muscle retraction, and grunting). The amniotic fluid was clear, and no sign of placental abruption. The placenta was normal macroscopically.

**Assessment and management:** The baby was admitted to the neonatal intensive care unit (NICU) and supported by nasal continuous positive airway pressure (nCPAP) and oxygen supplement because of a respiratory distress score of 5 at the first hour of birth. Heart rate 150 bpm and blood pressure 70, 40 mmHg. In physical examination, the skin appeared severely pale, with no signs of edema, ecchymosis, or petechiae. No signs of hepatosplenomegaly or ascites were noted on physical examination.

We requested an emergency complete blood cell count (CBC), peripheral blood smear, and retic count. The blood group and Rh status of the mother and baby were determined.

Other requested tests were: blood culture, C-reactive protein (CRP), serology of TORCH, chest radiography, abdominal and pelvic sonography, cardiac echocardiography, and maternal blood HE.

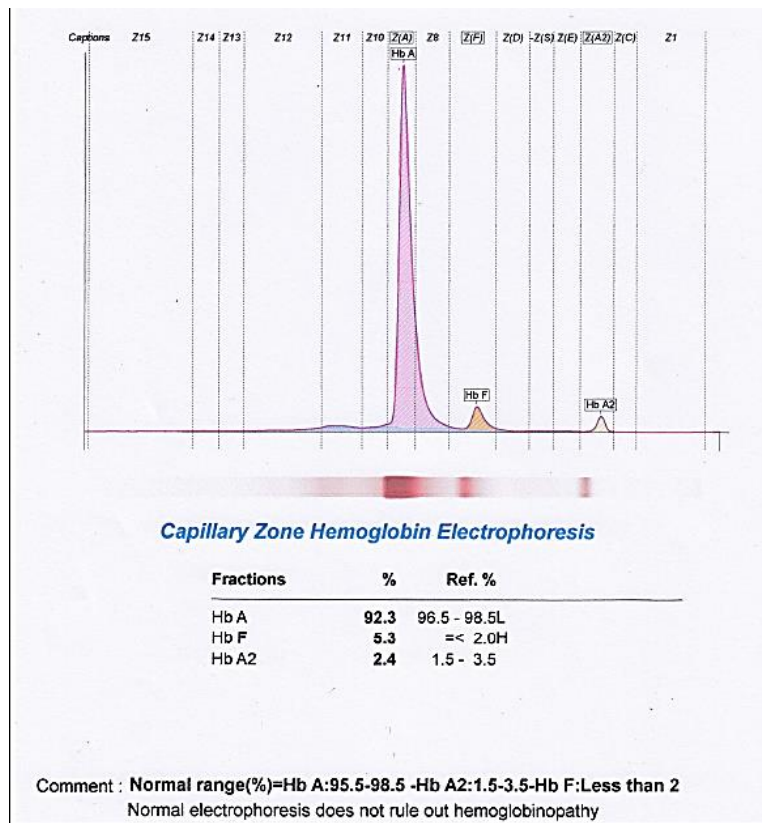
Laboratory findings: An emergency CBC revealed a Hb level of 3.1 g/dL and a hematocrit of 11.1%. Other lab findings are summarized in Table 1.

Treatment and follow-up: Packed RBC 10ml/kg was transfused, and a repeated dose was given 8

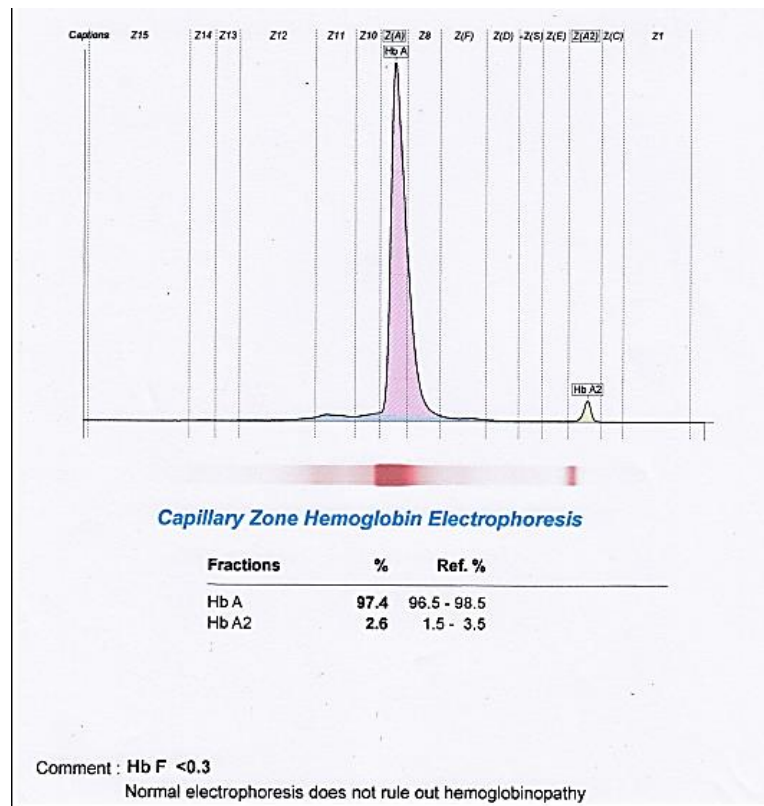
hours later. The baby had good progress, and we discontinued respiratory support after 48 hours. He was discharged from the NICU with an Hb of 11.8 g/dL. He was followed at the outpatient clinic and had good growth and development.

**Table 1. Laboratory findings of the infant and his mother**

Lab test	Result
CBC & peripheral smear	Hb:3.1g/dl, HCT:11.1%, RBC:0.95×10 <sup>6</sup> /μl, WBC:17260/μl, NRBC:10.5%, MCV:116.8 fl, MCV:11.1 fl, MCH:32.6pg, MCHC:27.9%, PLT:145000/μL Reticulocyte count < 5%, Reticulocyte production (maturation) index (PRI): 1.48
Direct coombs:	Negative
Umbilical arterial blood gas analysis	PH: 7.19, PaCO2:46.8 mmHg, Hco3: 17.8 mEq/L, PaO2:27.8 mmHg, BE: -10.3
CRP(C-reactive protein)	1 mg/L
Blood culture	No bacterial growth
Blood group and Rh	Neonate :B <sup>+</sup> , Mother: AB <sup>+</sup>
Imaging	Chest radiography: normal, with no signs of cardiomegaly. Abdominal and pelvic sonography: no free fluid and no hepatosplenomegaly or any other organomegaly cardiac echocardiography: a small-sized ductus arteriosus and a large PFO were shown, and no pericardial effusion.
TORCH serology	Negative
Hemoglobin Electrophoresis of Maternal blood	9 January 2024 (Hb A: 92.3%, Hb F: 5.3%, Hb A2: 2.4%) (Figure 1) 20 May 2024 (Hb A: 97.3%, Hb F: ≤ 0.3%, Hb A2: 2.6%) (Figure 2)



**Figure 1. Hemoglobin electrophoresis of maternal blood on the second day after delivery(9 January 2024) showing elevated HbF (5.3%) compared to baseline (Hb A: 92.3%, Hb A2: 2.4%).**



**Figure 2. Hemoglobin electrophoresis of maternal blood about four months after delivery (20 May 2024), showing dropped HbF (Hb A: 97.3%, Hb F: ≤ 0.3%, Hb A2: 2.6%)**

## Discussion

Massive FMH is a rare phenomenon [1, 2]. To date, no established, reproducible risk factors have been identified [14]. Although FMH can be one of the etiologies of late fetal demise, several reports have documented fetal mortality related to FMH, with a reported incidence ranging from 1.6% to 11% in such cases [15].

In this case, an emergency cesarean section was performed due to decreased fetal activity and abnormal CTG. Decreased fetal movement is among the most common clinical manifestations of massive FMH and has been reported in approximately 25% of antenatal histories in the literature [2, 4, 7].

The newborn was apneic and depressed at birth and required positive pressure ventilation. Hb and hematocrit (Hct) were measured within the first hour of life due to marked pallor. Severe anemia was documented (Hb =3.1 g/dl, HCT=11.1%) in the absence of placental abruption, hydrops fetalis, or any history suggesting chronic pregnancy pathology, pointing toward acute blood loss.

Causes of anemia include decreased RBC production, RBC destruction, and blood loss. Reticulocyte count rises in chronic blood loss or RBC destruction; in this case, the reticulocyte count was <5% despite severe anemia, supporting an acute, severe blood loss event.

The infant was not hydropic, and no specific causes of chronic fetal anemia, such as Parvovirus B19 infection, were seen. There was no history of ABO or Rh incompatibility; the mother's blood group was AB Rh+, arguing against incompatibility as a cause.

The Kleihauer-Betke (KB) test is widely used to estimate FMH but has limitations. The presence of F-cells can yield false-positive results or overestimate the magnitude of FMH. Elevated F-cell levels, presenting as FMH, have been reported in the setting of maternal HbF-related conditions, such as hereditary persistence of HbF (HPFH), HPFH/sickle trait, and thalassemia, in mothers with elevated HbF. In such cases, an alternative quantitative method for FMH assessment is advised [5, 16].

HPLC and flow cytometry are additional methods for detecting fetal Hb in maternal circulation. There is limited data on the use of HE to detect fetal Hb. While some evidence suggests higher accuracy than KB testing, neither method can determine the timing of the bleed (acute vs. chronic) or its exact onset in all cases [2,17].

### Limitations

In this case, due to technical difficulties and the lack of an available expert, KB testing could not be performed, and flow cytometry was unavailable at our center; therefore, HE was used for diagnosis. HbF in the maternal circulation on the second day after delivery was 5.3% (Figure 1), despite the mother having no known hemoglobinopathy. To confirm that the HbF rise was due to transfer from fetal blood, HE was repeated four months later, and the maternal HbF level had decreased to <0.3% (Figure 2).

### Conclusion

FMH can occur during pregnancy; however, massive transfusion is a rare event, with decreased fetal activity as one of its key presenting features. Therefore, when a decision is made to terminate a pregnancy due to perceived fetal movement diminution, it is prudent to assess the newborn's Hb level and maternal HbF. If FMH is suspected, maternal HE can be used for diagnosis when standard tests are not feasible.

### Acknowledgments

The authors would acknowledge the support of Babol University of Medical Sciences. They also express their gratitude to the Clinical Research Development Unit of Rouhani Hospital.

### Ethical Considerations

The Ethics Committee of Babol University of Medical Sciences, Iran (approval number: [IR.MUBABOL.HRI.REC.1404.002](https://doi.org/10.30472/cjped.v11i1.1404)), approved the study.

### Funding

There was no financial support for this research.

### Conflict of interest

There is no conflict of interest.

### References

1. Li P, Shu H, Lin P, et al. Case Report: Fetomaternal hemorrhage and its association with pronounced neonatal anemia. *Front Pediatr* 2024; 12: 1423786.
2. Gică N, Botezatu R, Demetrian M, et al. Severe Neonatal Anemia Due to Spontaneous Massive Fetomaternal Hemorrhage at Term: An Illustrative Case with Suspected Antenatal Diagnosis and Brief Review of Current Knowledge. *Medicina (Kaunas, Lithuania)* 2021; 57(12).
3. Bhargava V DS, Mahajan V, Jain SK. Silent Feto-Maternal Bleed as a Cause of Severe Neonatal Anemia. *J Pediatr Child Care* 2016; 2(1): 3.
4. Park HC, Park SK, Choi MS. Neonatal Severe Anemia Due to Massive Fetomaternal Hemorrhage. *Perinatol* 2019; 30(1): 40-5.
5. Al Farsi AJ AA, Ali HA. Severe Neonatal Anemia Due to Feto-maternal Hemorrhage, The Lowest Cord Hemoglobin Values Probably Ever Reported in the Neonatal Literature. Case report. *World Wide J Multidisciplinary Res Develop* 2023; 9(5): 9-14.
6. Solomon N, Playforth K, Reynolds EW. Fetal-maternal hemorrhage: A case and literature review. *AJP report* 2012; 2(1): 7-14.
7. Christensen RD, Lambert DK, Baer VL, et al. Severe neonatal anemia from fetomaternal hemorrhage: Report from a multihospital health-care system. *J Perinatol: Offic J California Perinatal Associat* 2013; 33(6): 429-34.
8. Mari G, Deter RL, Carpenter RL, et al. Noninvasive diagnosis by Doppler ultrasonography of fetal anemia due to maternal red-cell alloimmunization. Collaborative Group for Doppler Assessment of the Blood Velocity in Anemic Fetuses. *New England J Med* 2000; 342(1): 9-14.
9. Eichbaum M, Gast AS, Sohn C. Doppler sonography of the fetal middle cerebral artery in the management of massive fetomaternal hemorrhage. *Fetal Diagn Therap* 2006; 21(4): 334-8.
10. Boller MJ, Moore GS, Hung YY, et al. Fetomaternal hemorrhage: evaluation of recurrence within an extensive integrated healthcare system. *American J Obstetric Gynecolog* 2021; 225(5): 540. e1-8.

11. Dupre AR, Morrison JC, Martin JN, et al. Clinical application of the Kleihauer-Betke test. *J Reproductive Med* 1993; 38(8): 621-4.
12. Medearis AL, Hensleigh PA, Parks DR, Herzenberg LA. Detection of fetal erythrocytes in maternal blood post partum with the fluorescence-activated cell sorter. *American J Obstetric Gynecolog* 1984; 148(3): 290-5.
13. Stanic Z, Stanisic L, Fureš R, et al. Fetomaternal Hemorrhage: Can We Use Hemoglobin Electrophoresis as a Diagnostic Tool? *Zeitschrift Geburtshilf Neonatolog* 2020; 224(3): 150-2.
14. Akorsu EE, Acquaye JK, Benneh AA, et al. Fetomaternal hemorrhage among pregnant women in Accra, Ghana. *International J Gynaecolog Obstetric: Official Organ Inter Federat Gynaecolog Obstetric* 2019; 146(3): 333-8.
15. Carles D, André G, Pelluard F, et al. Pathological Findings in Feto-maternal Hemorrhage. *Pediatric Developmental Pathology: Official J Societ Pediatr Patholog* 2014; 17(2): 102-6.
16. Kim YA, Makar RS. Detection of fetomaternal hemorrhage. *American J Hematolog* 2012; 87(4): 417-23.
17. Popescu MR, Panaitescu AM, Pavel B, et al. Getting an Early Start in Understanding Perinatal Asphyxia Impact on the Cardiovascular System. *Front Pediatr* 2020; 8: 68.