

Nephrocalcinosis and Recurrent Hematuria in a boy with Lowe Syndrome: A Case Report

Mohsen Akhavan Sepahi^{1,2*}, Mohammad Hossein Akhavan Sepahi³

1. Department of Pediatric Nephrology, School of Medicine, Qom University of Medical Sciences, Qom, Iran
2. Clinical Research Development Unit, Hazrat-e Masoomeh Hospital, Qom University of Medical Sciences, Qom, Iran
3. Department of Dentistry, School of Medicine, Dentist Student, A.I. Yevdokimov Moscow State University of Medical and Dentistry Sciences, Moscow, Russia

*Corresponding Author: Dr. Mohsen Akhavan Sepahi;

Address: Department of Pediatric Nephrology, School of Medicine, Qom University of Medical Sciences, Qom, Iran.

Tel: +98 2536651802

Fax: +98 2536651801

E-mail: akhavansepahimm@gmail.com

Article Info.

Article type: Case Report

Received: 17 Dec. 2023

Revised: 14 July 2024

Accepted: 27 Aug. 2024

Published: 27 Aug. 2024

Keywords:

*Congenital Cataract,
Intellectual Disability,
Kidney Stone,
Lowe Syndrome,
Proteinuria*

ABSTRACT

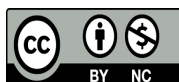
Background and Objective: Lowe syndrome (LS) is a very rare syndrome characterized by the triad of intellectual disability, cataracts, and proximal renal tubule dysfunction due to a mutation of the oculocerebrorenal (OCRL) gene encoding the OCRL-1 protein. This case report describes an LS boy with a different familial complication.

Case Report: We report a 7-year-old boy presented with failure to thrive (FTT), congenital cataract, leg deformity, genu varus, short stature, renal tubular acidosis (Fanconi syndrome), mental retardation and normal glomerular filtration rate who was diagnosed with LS 6 years ago. This family includes the parents and 4 sons, the eldest and the youngest are normal, and the second and third children in the family have persistent microscopic hematuria.

Conclusion: The present case study shows that nephrocalcinosis caused by Lowe syndrome could leads to recurrent microscopic hematuria.

Cite this Article:

Akhavan Sepahi M, Akhavan Sepahi MH. Nephrocalcinosis and Recurrent Hematuria in a boy with Lowe Syndrome: A Case Report. *Caspian J Pediatr* March 2024; 10: e7.



Introduction

Lowe syndrome (LS) or oculocerebrorenal syndrome (OCRL) is a very rare disease that affects several different organs. Normally, the lifespan of LS is no more than fourteen decades, and prenatal diagnosis is necessary to prevent the birth of an affected fetus [1-3]. This syndrome is a sex-linked disorder with the triad of renal tubular dysfunction, mental retardation and cataracts, but connective tissue, gonads, musculoskeletal system and skin are also affected [4-6]. Other features include arthritis, recurrent pathological fractures, nontender joint swelling, debilitating palmar and plantar fibrosis, focal nodules, bone erosions, growth retardation, behavioral problems, severe hypotonia, mental retardation and renal tubular dysfunction with slowly progressive renal insufficiency [1, 2, 7-9]. Some mutations in the OCRL gene stop the production of various enzymes caused by this gene. OCRL types are also observed in LS and Dent disease type 2 [2, 5-7]. Dent disease is an X-chromosome-dependent inherited tubulopathy with proximal renal tubular acidosis, nephrocalcinosis, renal calculi, hypercalciuria and LMW proteinuria. Dent patients have no extrarenal manifestations other than rickets [3, 8]. Because hematuria is a long-term risk factor for chronic kidney disease, and its persistence is a symptom of progressive kidney disease. The best way to prevent the progression of kidney disease is to investigate the cause of hematuria in these patients and treat it. This case report investigated the etiology of hematuria in LS. The possible mechanisms of the causes of hematuria are not defined, but further research is needed to find the cause, avoid misdiagnosis, and reduce the complications.

Case presentation

This case report describes an LS boy (7 years old) who presented with failure to thrive (FTT), congenital cataract, foot deformity and genu varus, mental retardation, short stature, proximal renal tubule dysfunction and normal glomerular filtration rate for the last 6 years.

One of the sons in the family moved to Sweden with his father as a refugee. He was recently

diagnosed with LS (Dent disease type 2) by genetic testing. The mother must be a carrier because she has 3 affected brothers, one of whom has died. The family has economic problems and is not insured in Iran. No genetic tests were carried out on the members of the family living in Iran. The family has 4 boys. The eldest and youngest are healthy. The mother must be a carrier of illness, as 3 uncles are sick. Unfortunately, one of them passed away with the same symptoms as the boy. The third son has a genu varus, is of short stature and has cataracts as we believe he has LS. The second son, who lives in Sweden, underwent genetic testing and was found to have a homozygous OCRL1 gene mutation, but was considered pathologic due to a diagnosis of Dent's disease type 2. The patient was born with a low birth weight and had growth and learning delays. The patient's weight was 14 kg (less than the 25th percentile), but he had normal vital signs but there were no signs of fever, edema, lymphadenopathy or organomegaly. The results of cardiovascular, respiratory and other physical examinations were unremarkable (Figure 1, 2). The hemoglobin was 12.7 g/dL, the total leukocyte count was $6.5 \times 10^9/L$ (69% neutrophils), and the platelet count was $188 \times 10^9/L$, respectively. The serum analysis included: Blood urea nitrogen 18.5 mg/L, creatinine 0.82 mg/L, sodium level 137mg/dL, potassium level 2.5 mg/dL, vitamin D level 20 ng/mL, calcium level 8.5mg/dL, phosphorus level 3.2mg/dL, albumin 3.6gr/dL, normal lipid profile, and venous blood gases with acidic pH and low bicarbonate levels. Urine laboratory tests included the following: Urinalysis (PH: 5.5, WBC: 1-2, RBC: 18-20, SG: 1.007), urine culture: negative, 24-hour urine test (protein: 95 mg/dl, creatinine: 450mg/ dl), random urine (creatinine: 36 mg/ dl, calcium 8 mg/dl, Na: 75mg/dl, K: 25mg/dl). The renal ultrasound indicated nephrocalcinosis. According to the results of the tests, Fanconi syndrome (proximal renal tubular acidosis) was diagnosed. The patient was treated with K-citrate, Vit D, hydrochlorothiazide and phosphate Sandoz. The possible cause of hematuria in this study is nephrocalcinosis, which was confirmed by ultrasound. The cause of hematuria in Fanconi syndrome can be nephrocalcinosis, small

kidney stones, and structural disorders of the kidney, but in this study, the possible cause of hematuria is nephrocalcinosis confirmed by ultrasound.

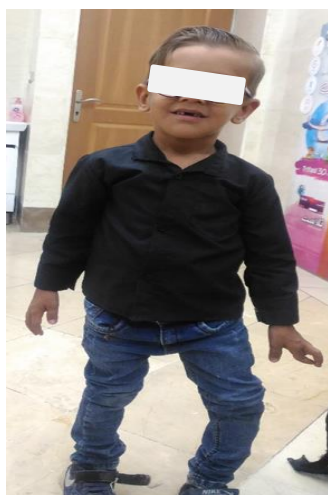

Fig. 1. Leg deformity, genu varus and short stature of patient




Fig 2. Congenital Cataract of patient

Discussion

In the present case, nephrocalcinosis caused by LS led to recurrent microscopic hematuria. Although kidney problems in LS do not occur at the onset of birth, many boys with this syndrome have kidney problems, including hypercalciuria and nephrocalcinosis, by the age of one year [1]. To date, no recurrent transient hematuria has been reported in patients with LS and nephrocalcinosis. Nephrocalcinosis or a stone is present in approximately one-half of LS patients [2, 9, 10]. The

cause of nephrocalcinosis and nephrolithiasis is not hypercalciuria or age, but hypercalciuria resulting from tubular dysfunction or a complication of therapy [2, 9-13]. Metabolic disorders, anatomical abnormalities, and environmental and nutritional factors are among the causes of kidney stones in children [14-17], and in this patient, proximal renal tubular acidosis (Fanconi syndrome) is the most important cause of stone formation. These cases are unusual for some reasons. First, the development of transient microscopic hematuria of urinary sediment with nephrocalcinosis is rare in LS, and there are no similar reports in the recent literature. Second, hypercalciuria has been reported as a cause of nephrocalcinosis and nephrolithiasis. Third, patients had intermittent microscopic hematuria during the course of this disease. The best way to prevent disease progression in congenital kidney disease is to control its complications, prevention and treatment. However, the severity factors of LS are still not clearly defined [8], so further studies on this syndrome are recommended, especially larger and multicenter studies.

The limitations of this study were as follows: 1- The small number of patients studied in only one family and one center. 2- The review of patient records was not complete, and genetic testing, radioisotope scan, and voiding cystourethrography were not performed.

Acknowledgments

The authors would like to thank the Department of Clinical Research and Development, Hazrat-e Fatemeh Masoumeh Hospital, Qom University of Medical Science.

Funding

This study was self-funded.

Ethical approval

This study was approved by the Ethics Committee (Ethical code: IR.MUQ.REC.1402.227).

Conflicts of Interest

The authors have no conflicts of interest.

References

1. Ma X, Ning K, Jabbehdari S, et al. Oculocerebrorenal syndrome of Lowe: Survey of ophthalmic presentations and management. *Eur J Ophthalmol* 2020; 30(5): 966–73.
2. Bokenkamp A, Ludwig M. The oculocerebrorenal syndrome of Lowe: an update. *Pediatr Nephrol* 2016; 31(12): 2201–12.
3. Yamamoto K, Hasegawa Y, Ohata Y, et al. Complete oculocerebrorenal phenotype of Lowe syndrome in a female patient with half reduction of inositol polyphosphate 5-phosphatase. *CEN Case Rep* 2020; 9(2): 95–100.
4. Chen KJ, Wu HR, Chao MC, et al. Genotype and phenotype studies of Lowe syndrome in three families in Taiwan. *Pediatr Neonatol* 2021; 62(3): 327–8.
5. Foreman JW. Fanconi Syndrome. *Pediatr Clin North Am* 2019; 66(1): 159–67.
6. Egot M, Lasne D, Poirault-Chassac S, et al. Role of oculocerebrorenal syndrome of Lowe (OCRL) protein in megakaryocyte maturation, platelet production and functions: a study in patients with Lowe syndrome. *Br J Haematol* 2021; 192(5): 909–21.
7. Preston R, Naylor RW, Stewart G, Bierzynska A, Saleem MA, Lowe M, et al. A role for OCRL in glomerular function and disease. *Pediatr Nephrol* 2020; 35(4): 641–8.
8. Mohsen Akhavan Sepahi, Mohammad Reza Razavi. An Update on the Oculocerebrorenal Syndrome of Lowe: A Review Article. *J Compr Ped* 2022; 13(2): 117326.
9. Bockenhauer D, Bokenkamp A, van't Hoff W, et al. Renal phenotype in Lowe Syndrome: a selective proximal tubular dysfunction. *Clin J Am Soc Nephrol* 2008; 3(5): 1430–1436.
10. Bokenkamp A, Bockenhauer D, Cheong HI, et al. Dent-2 disease: a mild variant of Lowe syndrome. *J Pediatr* 2009; 155(1): 94–9.
11. Raja KA, Schurman S, D'Mello RG, et al. Responsiveness of hypercalciuria to thiazide in Dent's disease. *J Am Soc Nephrol* 2002; 13(12): 2938–44.
12. Krieger NS, John Asplin, Ignacio Granja, et al. Chlorthalidone with potassium citrate decreases calcium oxalate stones and increases bone quality in genetic hypercalciuric stone-forming rats. *Kidney Int* 2021; 99(5): 1118–26.
13. Sliman GA, Winters WD, Shaw DW, Avner ED. Hypercalciuria and nephrocalcinosis in the oculocerebrorenal syndrome. *J Urol* 1995; 153(4): 1244–6.
14. Akhavan Sepahi M, S Shahmoradi, Shervin Rashidinia, Seyed Amir Hejazi. Metabolic and anatomic abnormalities associated with pediatric nephrolithiasis. A cross-sectional study. *Int J Pediatr* 2017; 5(5): 4833–8.
15. Akhavan Sepahi M, Sharifian M, Mohkam M, et al. Biochemical Risk Factors for Stone Formation in Healthy School Children. *Acta Medica Iranica* 2012; 50 (9): 814–8.
16. Sharifian M, Dalirani R, Mohkam S, et al. Spontaneous resolution of vesicoureteral reflux (VUR) in Iranian children: A single center experience in 533 cases. *Nephro-Urology Monthly* 2011; 3(3): 191–5.
17. Mohsen Akhavansepahi, Bibi Leila Hoseini, Yaser Tabarai. Screening of hypercalciuria among children with persistent asymptomatic hematuria. *J Biostat Epidemiol* 2017; 3(3/4): 106–10.