

Evaluation of Cardiac Findings in Pediatric Patients with Acute Ischemic Stroke: A Brief Report and Review of Current Literature

Mohammad Reza Khalilian^{1*}, Reza Azizi Malamiri², Tahmineh Tahouri¹,
Mohammad Ghazavi³

1. Department of Pediatrics, School of Medicine, Shahid Beheshti University of Medical Sciences, Tehran, Iran.

2. Department of Pediatric Neurology, Golestan Medical Educational and Research Center, Ahvaz Jundishapour University of Medical Sciences, Ahvaz, Iran.

3. Department of Pediatrics, Kashan University of Medical Sciences and Health Services, Kashan, Iran.

*Corresponding Author: Dr. Mohammad Reza Khalilian;

Address: Modarres Hospital, Yadegar-e Emam Expt, Sadat Abad St., Tehran, 34383-19987, Iran.

Tel: +98 21 22074087,

Fax: +98 21 22074101,

E-mail: khalilianomid@yahoo.com,

khalilian-m@sbmu.ac.ir

Article Info.

Article type:

Short Communication

Received: 18 June 2022

Revised: 28 Oct 2022

Accepted: 30 Oct. 2022

Published: 7 March 2023

Keywords:

Cardiac Disease,

Children,

Ischemic Stroke

ABSTRACT

Background and Objective: A stroke is defined as an impairment of cerebral blood flow that results in neurologic symptoms and has ischemic and hemorrhagic forms. The ischemic type is more common in children. Congenital and acquired heart diseases are common causes of ischemic stroke in children. The aim of the present study was to describe the cardiac findings in pediatric patients younger than 14 years who were admitted with acute ischemic stroke.

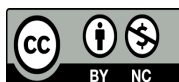
Methods: This cross-sectional study was conducted to evaluate the cardiac findings in 21 patients under 14 years of age admitted with acute ischemic stroke to Golestan General Hospital, Ahvaz, Iran, over a 5-year period between 2013 to and 2018. All patients underwent a thorough cardiac examination that included electrocardiography as well as echocardiography and, if necessary, contrast echocardiography. Patients also underwent MRI of the brain and hematologic laboratory tests. Descriptive data were analyzed using SPSS 23.

Findings: Out of 21 patients, 5 (23.8%) had abnormal echocardiography, whereas 16 (76.2%) patients had normal echocardiography. The patients with normal echocardiography underwent contrast echocardiography, which was positive for patent foramen ovale in only one patient. Of the total of 5 patients with abnormal echocardiography, 2 patients had congenital heart disease, 2 patients had dilated cardiomyopathy, and one patient had left atrial myxoma.

Conclusion: In any pediatric patient with acute stroke, cardiac causes should be considered as the main risk factor, and a thorough cardiologic examination would be necessary.

Cite this Article:

Khalilian MR, Azizi Malamiri R, Tahouri T, Ghazavi M. Evaluation of Cardiac Findings in Pediatric Patients with Acute Ischemic Stroke: A Brief Report and Review of Current Literature. *Caspian J Pediatr* March 2023; 9: e9.



Introduction

A stroke, or cerebral vascular accident, is defined as an impairment in cerebral blood flow which leads to neurological symptoms. There are two types of strokes: ischemic and hemorrhagic. Hemorrhagic stroke is a result of bleeding from a ruptured cerebral artery, while obstruction in the cerebral arteries, and with lower frequency in the cerebral veins, is the main cause of ischemic stroke. In pediatric patients, as in adults, ischemic strokes are more frequent than hemorrhagic ones. The prevalence of stroke is approximately 1.2 to 13 cases per 100,000 children under the age of 18 [1]. The main causes of stroke in children are metabolic and hematologic disorders (such as protein C, S, and Antithrombin III deficiency or other coagulation defects, polycythemia, thrombocytopenia), nutritional deficiencies, homocystinuria, neurofibromatosis, fibromuscular dysplasia, malformation of intracranial vessels, infection or trauma in the central nervous system, vasculitis, and cardiac disease [2]. Clinical presentations could be very mild and consist mainly of headaches, seizures, hemiplegia, and loss of consciousness [3]. Congenital heart disease is the most common congenital malformation with a prevalence of 1 case per 100 live births [4]. One of the most common causes of stroke in children, in particular ischemic stroke, is both congenital and acquired heart diseases, such that up to 30% of strokes in pediatric patients are due to heart diseases [5], and the incidence of acute ischemic stroke is about 132 cases per 100,000 children with heart disease, which is much higher than the overall prevalence of stroke in children [6].

There are multiple risk factors for stroke in children with cardiac heart disease including the right to left shunting or the presence of a univentricular heart, which can lead to paradoxical embolism, infective endocarditis with vegetation formation, cardiomyopathy and dyskinesia of the ventricle or atrium, arrhythmia, valvulopathy or prosthetic valves, and an increase in systemic venous pressure. About 25 to 30% of strokes occur following interventions such as cardiac mechanical circulatory support, cardiac catheterization, and cardiac surgery [6, 7].

The purpose of the present study was to describe the cardiac findings in pediatric patients under 14 years of age with acute ischemic stroke who were admitted in to Golestan General Hospital, Ahvaz, Iran.

Methods

Design and participants

This prospective cross-sectional study was conducted to evaluate the cardiac findings in pediatric patients with acute ischemic stroke. A total of 21 patients under 14 years old with acute ischemic stroke who were admitted to Golestan General Hospital, Ahvaz, Iran, for 5 years between 2013 and 2018 were enrolled in the study. Inclusion criteria were that patients with acute ischemic stroke were included in the study and patients with hemorrhagic stroke were excluded from the current study.

Data collection

All children were examined by a pediatric neurologist, and echocardiography was conducted by a pediatric cardiologist. Stroke was diagnosed on the basis of the brain CT. All patients with acute ischemic stroke underwent a thorough cardiac examination, which included electrocardiography and echocardiography and, if necessary, contrast echocardiography. Brain MRI was performed in all patients. Basic demographic data were also collected from all parents who participated in the data collection.

Evolution laboratory parameters

Hematologic laboratory tests, including complete blood count with differential, platelet count, prothrombin time (PT), partial thromboplastin time (PTT), and international normalized ratio (INR), were also performed for the patients.

Results

Out of the 21 patients who entered the study, 12 (57.2%) were female and 9 (42.8%) were male. The patients were aged between 1 and 11 years (mean

4.78±3.52 years). 5 patients (23.8%) had abnormal echocardiography; whereas 16 patients (76.2%) had normal echocardiography. For those with normal echocardiography, contrast echocardiography was performed, which was positive in a single patient in favor of a patent foramen oval. Of the 5 patients with abnormal echocardiography, two had congenital heart disease, 2 had dilated cardiomyopathy, and one had left atrial myxoma. Of the patients with congenital heart disease, one had an atrioventricular septal defect and one had repaired tetralogy of Fallot. None of the patients had any evidence of irregular heart rhythm or arrhythmia on their electrocardiogram.

The blood tests requested for the patient at the time of admission, including complete blood count with differential, platelet count, prothrombin time (PT), partial thromboplastin time (PTT), and international normalized ratio (INR), were all normal. Brain imaging shows that 17 of the 21 patients suffered a stroke in the right hemisphere.

Outcome at the time of discharge

Regarding the short-term outcome of patients until the discharge, 15 (10.8%) cases demonstrated seizures and used anticonvulsant drugs (including one case of grade III and fourteen cases of grade II). In 4 cases (2.9%), ventriculoperitoneal shunting was performed (including two cases of grade III and two cases of grade IV). There were 3 cases (2.2%) of death, including one grade III and two grade IV of IVH.

Discussion

In our study, the prevalence of cardiac disease in acute ischemic stroke was 23.8%, which was similar to other studies in this area. In the acute ischemic stroke cohorts in children, the reported prevalence of the cardiac disease varies from 10% to 31% [6,8].

Reviewing the literature revealed that in pediatric patients, ischemic strokes are more common in patients of aged 1 to 14 years [9]. In our study, none of the patients were under one year old. However, children over 15 years old were not admitted to the pediatric ward according to the policies of Golestan hospital. As a result, it was not

possible to estimate the prevalence of stroke in this age range in our study.

In the current study, the prevalence of ischemic strokes in females (57.2%) was higher than in male patients (42.8%). However, previous studies have reported a higher prevalence of ischemic stroke in males [9]; this discrepancy in the prevalence of strokes by gender may be due to the small sample size in the current study.

There is an increased risk of acute ischemic stroke in those with cardiac disease, especially in children with cyanotic congenital heart disease. About one-third of acute ischemic strokes in pediatric patients with cardiac disease occur in the peri-procedural period. However, the prevalence of spontaneous acute ischemic stroke in these patients is three times greater than what happens following the procedures [10]. In the current study, all the acute ischemic strokes occurred spontaneously in patients with cardiac disease, which was consistent with the findings of previous studies.

In our study, of the 16 patients who did not have cardiac disease in the initial transthoracic echocardiography, only one had a patent foramen oval on contrast echocardiography with an agitated saline solution. In adult patients, the standard diagnostic technique for diagnosis of a patent foramen ovale is contrast transesophageal echocardiography [11]. However, since there were no limitations to the visualizing of the atrial septum in our patients, transesophageal echocardiography was not required in this study. According to previous studies, the risk of acute ischemic stroke in pediatric patients with isolated atrial septal defect or patent foramen ovale is 10 times greater in comparison with children without any cardiac disease [4]; the prevalence of patent foramen ovale in adult patients with cryptogenic stroke is up to 46% [12]. Although the development of stroke in patent foramen ovale patients is probably multifactorial, the two main mechanisms of stroke in these patients are paradoxical embolism as well as atrial arrhythmias such as atrial fibrillation [11]. However, closure of the patent foramen ovale is not currently recommended in young adults who do not have an increased risk of thromboembolism [13].

Of all 5 ischemic stroke patients with cardiac disease in on echocardiography, 2 patients had dilated cardiomyopathy. Of our two patients with dilated cardiomyopathy, both had a clot in their left atrium. It is now clear that the risk of thromboembolism and, in particular, ischemic stroke is increased in patients with dilated cardiomyopathy. The pathogenesis of thromboembolism in these patients is related to the increase in platelet activity, arrhythmia, and blood stasis as a result of decreased ventricular wall motion as well as cardiac output and enlarged ventricles [14].

One patient out of a total of 21 acute ischemic stroke patients in our study had a left atrial myxoma. Myxoma is a rare cardiac tumor in children that is commonly located in the area of the fossa ovalis in the left atrium. Although most cases of atrial myxoma are benign, they can also cause thromboembolic complications such as ischemic strokes or embolization of extremities, kidneys, and coronary arteries [15].

The pathogenesis of thrombosis in congenital heart disease patients is multifactorial. Endothelial injury secondary to chronic hypoxemia and resultant erythrocytosis, increase in tissue factor expression and fibrin deposition, and impaired fibrinolytic system, can all lead to thrombosis formation in these patients [16]. Of our two patients with congenital heart disease, the first patient had a repaired tetralogy of Fallot. Although this patient had normal blood tests at the time of admission, a stroke may have occurred due to secondary blood changes to cyanotic heart disease, which existed before the repair of the heart defect. The second patient had an atrioventricular septal defect (AVSD), and therefore, the occurrence of a stroke in him was not surprising due to the presence of a shunt at the atrial and ventricular levels.

Arrhythmias such as atrial fibrillation can increase the risk of ischemic strokes by up to 5 times [17]. However, none of our patients had an arrhythmia on their electrocardiogram at or before admission.

Limitations

The current study was single-center and limited in size, and the results could not be representative of subgroups of patients with acute ischemic stroke.

Conclusion

A thorough cardiologic examination would be necessary for any pediatric patient with acute stroke, and cardiac causes should be considered as the main risk factor.

Acknowledgments

The authors are grateful to all parents and patients for their participation in this study.

Ethical approval

The study was conducted in accordance with the Data Protection Act and according to the ethical guidelines of the Declaration of Helsinki and was approved by the Ethics Committee at the Ahvaz University of Medical Science in Iran (GP-93059).

Funding

This research did not receive any grants from funding agencies in the public, commercial, or non-profit sectors.

Authors Contributions

Design of the work: Mohammad Reza Khalilian and Reza Azizi Malmiri; Writing original draft: Mohammad Reza Khalilian; Writing-review & editing: Tahmineh Tahouri, Mohammad Ghazavi, and Mohammad Reza Khalilian; Data acquisition: Mohammad Reza Khalilian; Supervision: Mohammad Reza Khalilian.

Conflict of interest

The authors declared no conflicts of interest.

References

1. Tsze DS, Valente JH. Pediatric stroke: a review. *Emerg Med Int* 2011; 2011: 734506.
2. Sachdev A, Sharma R, Gupta D. Cerebrovascular complications in pediatric intensive care unit. *Indian J Crit Care Med* 2010; 14(3): 129-40.

3. Pappachan J, Kirkham FJ. Cerebrovascular disease and stroke. *Arch Dis Child* 2008; 93(10): 890-8.
4. Mandalenakis Z, Rosengren A, Lappas G, et al. Ischemic stroke in children and young adults with congenital heart disease. *J Am Heart Assoc* 2016; 5(2): e003071.
5. Vázquez-López M, Castro-de Castro P, Barredo-Valderrama E, et al. Ischaemic stroke in children with cardiopathy: An epidemiological study. *Neurologia* 2017; 32(9): 602-9.
6. Sinclair AJ, Fox CK, Ichord RN, et al. Stroke in children with cardiac disease: report from the International Pediatric Stroke Study Group Symposium. *Pediatr Neurol* 2015; 52(1): 5-15.
7. Chung MG, Williams KP, Wilson JL, et al. International Pediatric Stroke Study Investigators. Arterial Ischemic Stroke Secondary to Cardiac Disease in Neonates and Children. *Pediatr Neurol* 2019; 100: 35-41.
8. Asakai H, Cardamone M, Hutchinson D, et al. Arterial ischemic stroke in children with cardiac disease. *Neurology* 2015; 85(23): 2053-9.
9. Gorchynski J, Herrick J, Cortes E. Acute ischemic stroke in a pediatric patient. *West J Emerg Med* 2008; 9(4): 225-7.
10. Chung MG, Williams KP, Wilson JL, et al. International Pediatric Stroke Study Investigators. Arterial Ischemic Stroke Secondary to Cardiac Disease in Neonates and Children. *Pediatr Neurol* 2019; 100: 35-41.
11. Sun YP, Homma S. Patent Foramen Ovale and Stroke. *Circ J* 2016; 80(8): 1665-73.
12. Miranda B, Fonseca AC, Ferro JM. Patent foramen ovale and stroke. *J Neurol* 2018; 265(8): 1943-9.
13. Khan R, Chan AK, Mondal TK, Paes BA. Thrombosis and Hemostasis in Newborns (THIN) Group. Patent foramen ovale and stroke in childhood: A systematic review of the literature. *Eur J Paediatr Neurol* 2016; 20(4): 500-11.
14. Deng Y, Chen Z, Hu L, et al. Decreased eGFR is associated with ischemic stroke in patients with dilated cardiomyopathy. *Clin Appl Thromb Hemost* 2019; 25: 1076029619866909.
15. Wu Y, Fu XM, Liao XB, Zhou X. Stroke and peripheral embolisms in a pediatric patient with giant atrial myxoma: Case report and review of current literature. *Medicine* 2018; 97(30): e11653.
16. Ali H, Sarfraz S, Sanan M. Tetralogy of Fallot: Stroke in a Young Patient. *Cureus* 2018; 10(5): e2714.
17. Bertaglia E, Blank B, Blomström-Lundqvist C, et al. Atrial high-rate episodes: prevalence, stroke risk, implications for management, and clinical gaps in evidence. *Europace* 2019; 21(10): 1459-67.