

Successful Removal of Large Gastric Bezoar with Gastroduodenoscope: A Case Report in a 7-Year-Old Child

Sanaz Mehrabani¹ , Mohammadreza Esmailidooki² , Omid Reza Jamshidvand^{3*} ,
Vanooshe Nezafati³ , Firuzeh Esmailzadeh¹ 

1. Non-Communicable Pediatric Diseases Research Center, Health Research Institute, Babol University of Medical Sciences, Babol, IR Iran.
2. Clinical Research Development Unit of Amirkola Children's Hospital, Babol University of Medical Sciences, Babol, IR Iran.
3. Student Research Committee, Babol University of Medical Sciences, Babol, Iran.

* **Corresponding Author:** Dr. Omid Reza Jamshidvand;

Address: Non-Communicable Pediatric Diseases Research Center, Health Research Institute, Babol University of Medical Sciences, No 19, Amirkola Children's Hospital, Amirkola, Babol, Mazandaran Province, 47317-41151, IR Iran.

Tel.: +98 1132346963

E-mail: o.jmv@yahoo.com

Article Info.

Article type: Case Report

Received: 22 Oct. 2022

Revised: 10 Dec. 2022

Accepted: 15 Jan. 2023

Published: 5 March 2023

Keywords:

Bezoar

Child

Gastroduodenoscopy

Treatment

ABSTRACT

Background and Objective: Bezoar is a mass or indigestible substance that accumulates in the gastrointestinal tract, especially in the stomach. The formation of gastric bezoars (especially phytobezoars) is rare in children; however, when they are formed, they present a therapeutic challenge due to their hard composition and consistency as well as their large size.

Case Report: A 7-year-old boy with an abdominal mass was investigated in this case report. The patient had eaten a lot of persimmons and pomegranates in the past. Gastroduodenoscopy revealed a large phytobezoar in the stomach, which was removed and treated using a gastroduodenoscope.

Conclusion: The gastroduodenoscopic technique is cost-effective in the treatment of gastrointestinal bezoars and has fewer complications for the patient than the surgery.

Cite this Article:

Mehrabani S, Esmailidooki M, Jamshidvand OR, et al. Successful Removal of Large Gastric Bezoar with Gastroduodenoscope: A Case Report in a 7-Year-Old Child. *Caspian J Pediatr* March 2023; 9: e10.

Introduction

Bezoar is a mass or indigestible substance that accumulates in the gastrointestinal tract, especially in the stomach. Bezoar usually contains hair, food, tablets, or an indigestible foreign body. The actual prevalence of bezoar in the pediatric population is unknown; however, it is more common in children, adolescents, and women with a history of gastrointestinal surgery, diabetes, neurologic and psychiatric disorders [1-3]. It is found in less than 1% of patients undergoing gastroduodenoscopy of the upper gastrointestinal tract [1, 4, 5].

Bezoars are mainly classified into four types according to the material that makes up the indigestible mass of the bezoar: Phytobezoars, Trichobezoars, Pharmacobezoars, and Lactobezoars [1]. Currently, bezoars are defined and classified based on their constituents [1, 4]. Phytobezoars are mainly composed of plant substances (vegetables and fruits). Determined the content of plant fibers (cellulose, hemicellulose, lignin and tannins) in phytobezoar was determined, which are converted to polymers in the stomach. Disopyrobezoar is a particular type of phytobezoar formed by the consumption of persimmons [1, 4-8]. Trichobezoar consists of hairs [1]. Pharmacobezoar is formed when drug compounds are combined in the gastrointestinal tract [1]. Lactobezoars are composed of milk protein and are more common in preterm and low birth weight infants. It is not precisely known [1].

The volume of bezoar increases with continued ingestion of indigestible substances, and clinical symptoms worsen. Risk factors for bezoar formation include gastric anatomy and gastric dysfunction (example.g., previous gastric surgery), dental problems, ingestion of indigestible foods, and neurological and psychological problems [5]. Depending on where the bezoars formed, there are different clinical signs. In general, the symptoms include bloating, irritability, nausea, vomiting, early satiety, weight loss, and palpation of the mass on physical examination [1]. Lactobezoar is more common in infants, while trichobezoar and phytobezoar are more common in children and adults [1, 5, 9]. Complications of bezoar, although rare, can be severe and involve gastrointestinal necrosis

(with mucosal compression), ulcers, and gastrointestinal bleeding [5, 6, 9]. In addition, bezoar of the duodenum and bile ducts causes symptoms such as pancreatitis, malabsorption, and protein losing enteropathy [1]. Occasionally, complications such as perforation and gastric ulcers occur after bezoar removal [1].

History, physical examination, and laboratory tests may provide clinical clues to a bezoar diagnosis but are of little value on their own. Laboratory findings of bezoar may include mild microcytic anemia or leukocytosis [1]. In addition to clinical history, gastrointestinal imaging may aid in diagnosis prior to gastroduodenoscopy [7, 10, 11]. Moreover, gastroduodenoscopy is the preferred method for diagnosing bezoar and allows us to intervene therapeutically [1, 3, 12, 13]. To date, there are very few reports on gastric bezoars in children, especially phytobezoars and their therapeutic interventions [5-7, 14]. Treatment options for bezoars vary depending on the composition, location and size of the bezoar. Treatment options include flushing or dissolving the bezoar with chemicals, crushing, or finally surgery [1, 12, 13]. Bezoars can also be detected by laparotomy [1, 2, 12]. This case report represented the successful treatment of large gastric bezoar in a 7-year-old boy by gastroduodenoscopy.

Case Report

The patient was a 7-year-old boy of Afghan origin who was admitted to the pediatric emergency ward of Amirkola Children's Hospital (Northern Iran) with abdominal pain. The patient's pain began 5 days before referral and was persistent and preferential in the left upper quadrant of the abdomen. The patient's pain did not refer to any specific area and subsided with defecation. The patient had eaten large amounts of persimmons and pomegranates in the past six days and had experienced nausea after 24 hours and non-bloody and non-bilious vomiting several times. The patient reported abdominal pain for the past month. This pain was not persistent and healed with defecation. He also visited a local clinic two days before the onset of symptoms. After he did not have a bowel

movement, he was prescribed powdered Pidrrolax (polyethylene glycol). After taking it, the patient had bowel movements, but only once a day and they were hard.

He did not give any information about a specific disease or medication intake. His parents were healthy with no underlying disease, the patient weighed was 20 kg, and his vital signs were stable. Physical examination revealed a hard, mobile mass with definite borders in the left upper quadrant of the abdomen, without tenderness. The other examinations were normal. Laboratory values were unremarkable. Abdominal ultrasonography revealed a mass in the left upper quadrant of the abdomen with a large curved linear echogenic structure approximately 49 mm in size in the gastric lumen. After history and physical examination, bezoar was suspected, and to confirm the diagnosis, a CT abdominal and pelvic examination was requested, which revealed a large mass in the gastric lumen, confirming the diagnosis of bezoar (Figure 1). The patient underwent gastroduodenoscopy (Olympus instrument number GIF-H170- Japan), and in the

first gastroduodenoscopy session, a very large and voluminous multisegmental bezoar image was seen in the gastric mucosa (Figure 2). The esophageal and duodenal mucosas were all normal.

Treatment of the patient included 0.5 mg/kg Plasil (metoclopramide) ampoule every 8 hours and consumption of 1 liter of lemonade or cola daily. In the first session of gastroduodenoscopy, a soft drink injection with a sclerosing needle was introduced into different parts of the mass. Fragmentation was performed with alligator and snare forceps. This procedure was performed in 3 gastroduodenoscopic sessions one day apart. The mass was also cut and fragmented electrically with the snare during dissection. Rigid bezoar pieces were completely removed during the gastroduodenoscopy sessions using a snare and basket. Finally, in the fourth session, all pieces of bezoar (persimmon) were removed and the stomach was cleaned (Figure 3). The patient was discharged one day later, after five days, in good general condition. After one month, he had no more complaints at the follow-up examination.

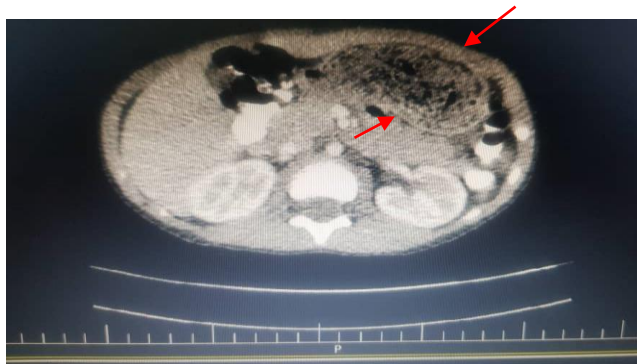

Fig 1. Gastric bezoar presentation in abdominal CT scan with contrast agent

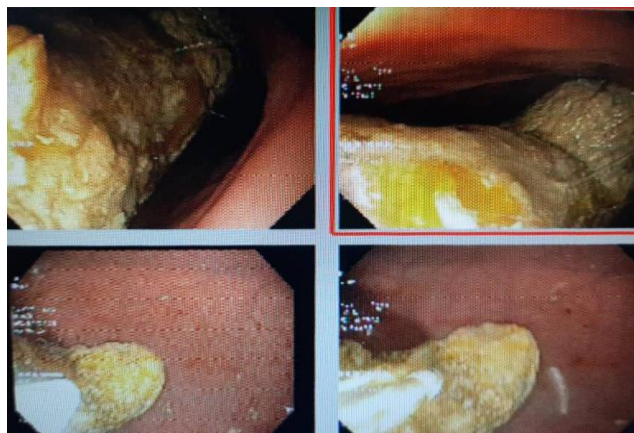


Fig 2. Endoscopic presentation of gastric bezoar; Fragmentation of bezoar with endoscopy

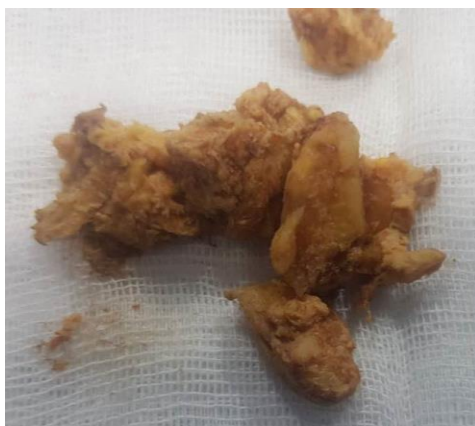

Fig 3. Remnant of removed gastric bezoar (persimmon)

Discussion

A 7-year-old boy with a large gastric bezoar was investigated in this case report. Lee reported changes in gastric function and anatomy as the cause of the bezoar in his case [7], but the case in our study did not have any of the above risk factors. These factors are usually less common in children, so bezoar is rare in this age group [1, 5-7, 14]. Unlike most reported cases [5-7], our patient did not have mental and nervous disorders, he had only consumed large amounts of persimmons and pomegranates, which led to the formation of large and voluminous bezoars. In fact, consumption of persimmons is still the most common cause of bezoars formation in some countries [5, 7]. Diagnosis of phytobezoar in the gastrointestinal tract can be difficult, and usually history and physical examination alone are not sufficient, but gastroduodenoscopic examinations and imaging techniques are required.

The complications of bezoar in children and adults can be severe, and to date a wide range of complications have been reported, including vitamin deficiency, pancreatitis, ulcers or gastritis, bleeding, obstruction or perforation of the gastrointestinal tract. The patient's clinical signs and symptoms may include bloating, irritability, nausea, vomiting, palpation of mass, early satiety, and weight loss. Note that clinical symptoms may vary depending on the location of the bezoar. For example, when it forms in the stomach, symptoms include gastric distention, abdominal pain, gastroesophageal reflux, loss of appetite, nausea, vomiting and weight loss [1]. Azevedo et al. (2011) reported an 8-year-old child diagnosed with bezoar.

The patient presented with symptoms of nausea, vomiting, and premature satiety. Bezoar was diagnosed and treated [3]. In the case of the present study, the patient presented with abdominal pain and nausea, vomiting, and palpation of mass in the abdomen.

Bezoar treatment depends on the type of bezoar and its location in the gastrointestinal tract. Treatment methods include 1. Washing, dissolving or medicating the bezoar, 2. Fragmentation and removal of the bezoar by gastroduodenoscopy, and 3. Open surgery [1]. Some specific treatments are listed here: Technique 1: Resolution with acetylcysteine, which can be performed via a nasogastric tube (NG). The second technique is cellulose ingestion administered orally for 2 to 5 days. The third technique is the use of Coca-Cola, which has been shown to be successful in the treatment of phytobezoar. The fourth technique is the use of polyethylene glycol, which is often used as an additive in treatment. The fifth technique is colonoscopy and enema can be used for colon bezoar. The sixth technique is gastroscopy, in which the bezoars can be cut open and removed. The last technique is laparotomy, which is used for resistant bezoars. [1, 12, 15]

In the study by Koulas et al. [12], 23 patients with upper gastrointestinal bezoars were treated in Greece. Size and location of the bezoar, predisposing factors, clinical symptoms, complications, and mortality were analyzed. Parameters such as conservative treatment, gastroduodenoscopic procedures, and surgical treatment were studied. Nineteen patients had

phytobezoars and four female patients with psychiatric disorders and mental retardation had trichobezoars. More than half of them (57%) had already had a surgical procedure on the stomach. The incidence of surgical complications was 28%, and the incidence of gastroduodenoscopy was 11%. Mortality in the surgical and gastroduodenoscopic groups was 4% and 0%, respectively. The difference in morbidity and mortality between the two groups was not statistically significant [12]. The therapeutic techniques of bezoar can cause complications such as bleeding, perforation, ulceration, hematoma, and gastric obstruction that require trained and experienced specialists. To date, there have been very few reports of phytobezoar in the stomach of children, and no standard treatment approach has been established. Therefore, there is limited experience with the therapeutic techniques to remove bezoars [8,12,13,16].

The technique of excising and dissolving long bezoars by gastroduodenoscopy has not been successful in many cases and requires surgical intervention. There are some very interesting and useful reports on the treatment of bezoars by the oral technique of using Coca-Cola orally or by direct injection into the mass itself. [15,17] Lee et al. reported the evaluation of 17 patients (age range: 48 to 78 years) with symptomatic phytobezoars in the stomach treated with cola and adjuvant gastroduodenoscopy. First, three liters of cola lavage (10 cases) or drink (7 cases) were used, and then gastroduodenoscopic resection with a comminutor basket or polypectomy trap was performed for the remaining bezoars. The overall success rate of resolution of phytobezoars in the stomach by cola and the clinical and gastroduodenoscopic findings were evaluated. Complete dissolution of the bezoar was achieved in four patients (23.5%), while 13 cases (76.5%) were only partially resolved. Bezoar dissolution usually requires a long period of time and may have side effects such as electrolyte imbalance, gastric ulceration, and bleeding [7, 12, 17].

In the present case, our patient consumed 1 liter of soft drink or cola daily. In the first gastroduodenoscopic session, the soft drink was injected into different parts of the mass with a

sclerosing needle. Then, fragmentation was performed with a snare and alligator forceps. This procedure was performed in 3 gastroduodenoscopic sessions. The snare was used to "cut and cotter" by generating an electric current. Completely rigid bezoar pieces were removed during gastroduodenoscopic sessions using a snare, basket, and gastroduodenoscopy. Finally, in the fourth session, all bezoar pieces were removed, and the stomach was cleaned. Dissolution is not without risk, as it requires a variable amount of time, intubation into the nasogastric tube, and ingestion of a significant amount of fluid. However, it may be cost-effective to use cola (or other solubilizing agents) or to perform gastroduodenoscopy. It may also reduce the number of gastroduodenoscopic sessions, accessories used, and hospital days. Although phytozoans in the stomach are very rare in children, their hard consistency and size can make them a therapeutic challenge. As this report shows standard gastroduodenoscopy for the treatment of bezoars, although tedious, can be a safe procedure and can be performed in a reasonable time. Because surgery can be avoided, gastroduodenoscopic procedures for pediatric bezoar treatment may be cost-effective [18].

Limitations of the study

The only limitation of this study is the absence of some endoscopic foreign body forceps, including a knife, to facilitate bezoar removal.

Conclusion

In addition, the present report highlights the importance of the endoscopic technique for the diagnosis and treatment of bezoar fragments and their removal because it has fewer complications and a shorter hospital stay compared with surgical techniques. As with most diseases, the value of prevention should not be underestimated. Patients with these problems should be advised to avoid high-fiber foods.

Acknowledgments

The authors would like to thank the Clinical Research Development Unit of Amirkola Children's

Hospital and the Non-Communicable Pediatric Diseases Research Center of Babol University of Medical Sciences for their contribution to this study.

Ethical approval

The study protocol was approved by the Ethics Committee of Babol University of Medical Sciences (IR.MUBABOL.REC.1400.283). Written informed consent was obtained from all parents.

Funding

This study was self-funded.

Conflict of interest

The authors declare no conflict of interest.

References

1. Mezzoff EA, Mezzoff AG. Bezoars, In: Wyllie R, Hyams JS, Kay M. Pediatric Gastrointestinal and Liver Disease. 5th ed. Elsevier Health Sciences. 2015; pp: 340-3.
2. Nirasawa Y, Mori T, Ito Y, et al. Laparoscopic removal of a large gastric trichobezoar. J Pediatr Surg 1998; 33(4): 663-5.
3. Azevedo S, Lopes J, Marques A, et al. Successful endoscopic resolution of a large gastric bezoar in a child. World J Gastrointest Endosc 2011; 3(6): 129.
4. Vargas JD, Spivak AM. A Perfect Storm. Am J Med 2009; 122(6): 519-21.
5. Choi SO, Kang JS. Gastrointestinal phytobezoars in childhood. J Pediatr Surg 1988; 23(4): 338-41.
6. Koç O, Yıldız FD, Nancı A, Şen TA. An unusual cause of gastric perforation in childhood: trichobezoar (Rapunzel syndrome). A case report. Eur J Pediatr 2009; 168(4): 495-7.
7. Lee J. Bezoars and foreign bodies of the stomach. Gastrointest Endosc Clin N Am 1996; 6(3): 605-19.
8. Lin CS, Tung CF, Peng YC, et al., Successful treatment with a combination of endoscopic injection and irrigation with coca cola for gastric bezoar-induced gastric outlet obstruction. J Chin Med Assoc 2008; 71(1): 49-52.
9. Ventura DE, Herbella FA, Schettini ST, Delmonte C. Rapunzel syndrome with a fatal outcome in a neglected child. J Pediatr Surg 2005; 40(10): 1665-7.
10. Zhang RL, Yang ZL, Fan BG. Huge gastric disopyrobezoar: a case report and review of literatures. World J Gastroenterol 2008; 14(1): 152.
11. El Hajjam M, Lakhloufi A, Bouzidi A, Kadiri R. CT features of a voluminous gastric trichobezoar. Eur J Pediatr Surg 2001; 11(2): 131-2.
12. Koulas SG, Zikos N, Charalampous C, et al. Management of gastrointestinal bezoars: an analysis of 23 cases. Int Surg 2008; 93(2): 95-8.
13. Blam ME, Lichtenstein GR. A new endoscopic technique for the removal of gastric phytobezoars. Gastrointest Endosc 2000; 52(3): 404-8.
14. Heinz-Erian P, Klein-Franke A, Gassner I, et al. Disintegration of large gastric lactobezoars by N-acetylcysteine. J Pediatr Gastroenterol Nutr 2010; 50(1): 108-10.
15. Okamoto Y, Yamauchi M, Sugihara K, et al. Is Coca-Cola effective for dissolving phytobezoars? Eur J Gastroenterol Hepatol 2007; 19(7): 611-2.
16. Chou JW, Lai HC. Obstructing small bowel phytobezoar successfully treated with an endoscopic fragmentation using double-balloon enteroscopy. Clin Gastroenterol Hepatol 2009; 7(9): e51-2.
17. Lee BJ, Park JJ, Chun HJ. How good is cola for dissolution of gastric phytobezoars? World J Gastroenterol 2009; 15(18): 2265.
18. Shah M, Wan DQ, Liu Y, Rhoads JM. Gastric bezoar: retrieve it, leave it, or disbelieve it? J Pediatr Gastroenterol Nutr 2021; 72(2): e31-6.