

Severe hypertriglyceridemia due to subcutaneous fat necrosis in a newborn with asphyxia: A case report

Roya Farhadi (MD)^{1*} 

1. Associate Professor of Neonatology, Pediatric Infectious Diseases Research Center, Communicable Diseases Institute, Mazandaran University of Medical Sciences, Sari, I.R. Iran; rfarhadi@mazums.ac.ir.

Article Info

Article type:

Case Report

Received: 11 Aug 2021

Revised: 17 Sep 2021

Accepted: 20 Sep 2021

Keywords:

Asphyxia,

Hypertriglyceridemia,

Hypoxic-ischemic

encephalopathy,

Neonate,

Subcutaneous fat necrosis

ABSTRACT

Background: Subcutaneous fat necrosis is a rare form of adipose tissue inflammation in neonates that results from certain predisposing factors such as asphyxia at birth.

Case Report: This report introduces a male neonate born at 38 weeks gestation with hypoxic-ischemic encephalopathy. The patient presented with an extensive erythematous skin lesion and subcutaneous nodules on the back and shoulders at four days of life. The baby had severe hypertriglyceridemia (834 mg/dl) after developing the lesion, which raised the diagnostic suspicion of subcutaneous fat necrosis. The hypertriglyceridemia resolved Over the next four and six months (82, 75 mg /dl, respectively). He had no other neurologic or metabolic abnormalities associated with subcutaneous fat necrosis.

Conclusion: Although subcutaneous fat necrosis is self-limited and has a benign course, it can be associated with severe hypertriglyceridemia requiring careful investigation and monitoring.

Cite this article: Farhadi R. Severe hypertriglyceridemia due to subcutaneous fat necrosis in a newborn with asphyxia: A case report. *Caspian J Pediatr* Sep 2021; 7(2): 598-602.



© The Author(s).

Publisher: Babol University of Medical Sciences

Introduction

Subcutaneous fat necrosis is a rare form of panniculitis that is often seen in term neonates during the first month of life [1, 2]. The lesion usually presents as plaques or hard erythematous nodules on bony prominences such as the shoulders, buttocks, hips, and cheeks and the most common site is the dorsal trunk of the infant [3]. Although this lesion is rare and self-limited, it can sometimes be associated with more serious and rare complications such as hypercalcemia, thrombocytopenia, hypertriglyceridemia, and hypoglycemia, which can cause problems such as renal failure in the baby [3, 4].

The etiology of subcutaneous fat necrosis is unknown, but maternal and fetal factors may be associated with this disease. The predisposing risk factors include Rh incompatibility, preeclampsia, cocaine or calcium channel blocker use in the mother, perinatal asphyxia, birth trauma, whole-body cooling, and sepsis [5]. Congenital type of subcutaneous fat necrosis is rarely reported in the literature [6]. Subcutaneous fat necrosis is an uncommon

*Corresponding Author: Roya Farhadi (MD),

Address: Division of neonatology, Department of Pediatrics, BooAli Sina Hospital, Pasdaran Boulevard, Sari, 48158-38477, Iran.

Tel: +98 1133343018

Fax: +98 1133344506

E-mail: dr.royafarhadi@gmail.com, rfarhadi@mazums.ac.ir

inflammatory disorder of adipose tissue and was first defined by McNee and Harrison in 1926. Most cases have been reported in term and post-term infants and are rarely seen in premature infants [71].

In neonates, triglyceride levels above 150 mg/dl are considered as hyperlipidemia and severe hyperlipidemia refers to values above 500 mg/dl [81].

This report describes a neonate with severe hypertriglyceridemia due to subcutaneous fat necrosis following asphyxia.

Case Report

The patient was an 8-hour-old infant boy who was born at 38 weeks of gestation following a difficult normal vaginal delivery. The mother had an uneventful pregnancy. Apgar score was 2 and 3 at 1 and 5 minutes, respectively. The birth weight was 3650 grams. After resuscitation and stabilization of the baby, He was transferred to the NICU of Boo- Ali Sina Hospital in Sari for further management of hypoxic-ischemic encephalopathy. Despite the possibility of head cooling therapy in the mentioned center, cooling therapy was not performed for the baby, because the golden time for this technique had been over. Primary blood gases showed metabolic acidosis with pH=7.14, PaCo2=32mmHg, PaO2= 70 mmHg, Sao2= 94%, HCO3=19 mEq/L and BE=-12 mEq/L.

No clinical seizure was observed and no electrical seizure activity was detected on the baby's amplitude-integrated electroencephalography (aEEG). A diagnosis of mild hypoxic-ischemic encephalopathy which is classified as Sarnat Grade I was made for the neonate according to prenatal and clinical evidence and blood gas results.

Both mother and baby had blood type O and Rh-positive. Parenteral nutrition was not started for the baby. On the third day of birth, breastfeeding was started for the baby because he had a good general and medical condition.

On the fourth day of hospitalization, an erythematous lesion was observed in the shoulders and back of the infant, which was firm to the touch and spread to the neck and occiput of the neonate. Prominent hard nodules were also seen in the erythematous lesion, which had a firm consistency to the touch.

At first, inflammatory lesions such as cellulitis were suspected, but blood culture was negative and the laboratory inflammatory parameters such as acute phase reactants showed no evidence of infection. Prothrombin time and partial thromboplastin time were within the normal range. Ultrasound of the affected area showed an increase in soft tissue thickness and increased echogenicity of subcutaneous tissues without evidence of the abscess or hematoma. Despite proper antibiotic treatment, the lesion did not change much.

Therefore, with clinical suspicion of subcutaneous fat necrosis, the necessary tests were requested for the neonate. The amount of serum triglyceride was reported as 834mg/dl which was obtained 4 hours after feeding in the early morning during routine lab draws. Serum calcium level and 25-OH-D3 were reported 9.5 mg/dl and 30.1 (normal ranges 30-50) ng/ml, respectively. Complete blood count results were normal as well.

A dermatology consult was requested and the above diagnosis was confirmed. Due to the history of the baby and the shape of the lesion and the high level of triglyceride, for a definitive diagnosis, a skin biopsy was requested, but parents refused to perform it. The infant was discharged after ten days of good general condition and recommended following up on an outpatient basis. The triglyceride level at the discharge time was 431 mg/dl.

In the follow-ups, calcium, platelets, blood sugar, and vitamin D were still normal, and the lesion was eliminated one and a half months later, but the infant's triglyceride values were high in the monthly check. The amounts of 231 mg/dl and 180 mg/dl were reported two and three months after birth. Serum triglyceride level normalized at the end of the fourth month (82mg/dl). Figure 1 shows the clinical view and course of the lesion. Figure 2 shows the amounts of serum triglyceride from admission until 6 months of age.

In the examination of the infant in the eighth month of life, the infant was completely normal and no developmental delay was observed. He is socially aware and rapidly responded to visual objects. The independent sitting is accomplished by 6 months and had good sitting posture. The baby was able to pick up an object and had a whole hand grasp. The head circumference was measured and plotted and was within the normal limit.

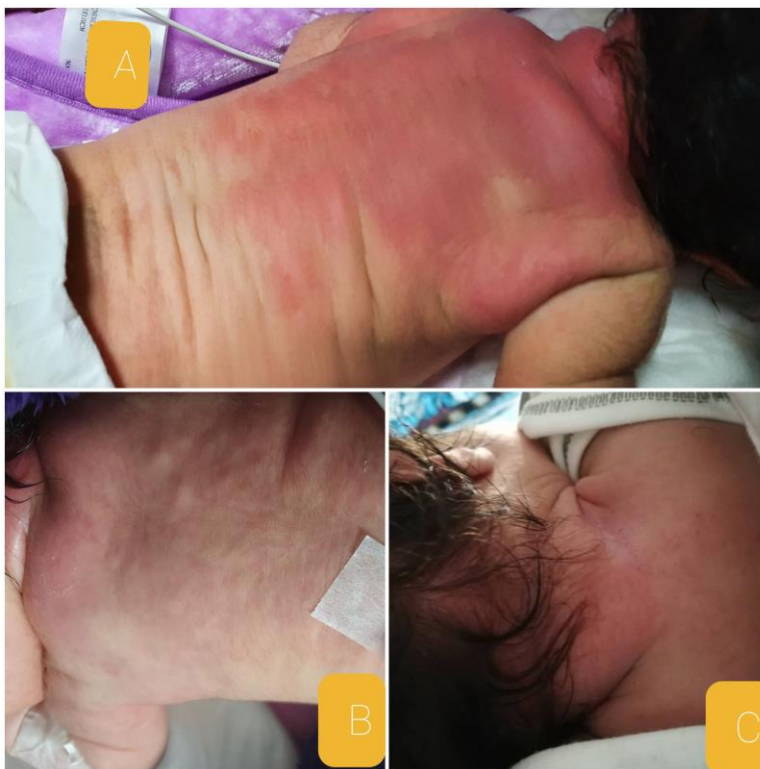

Figure 1. A=Skin lesion caused by subcutaneous fat necrosis on day 4 of life; B: Nodules on the back in the middle of erythematous plaque; C=Significant improvement after 3 weeks

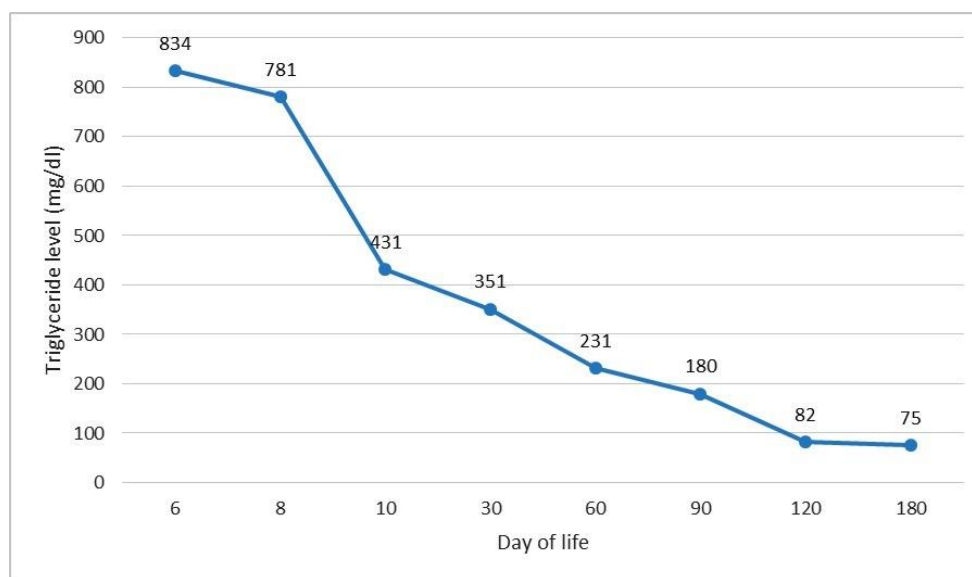


Figure 2: Serum triglyceride levels from admission till 6 months of age

Discussion

In this report, a neonate with mild asphyxia is discussed who develops severe hypertriglyceridemia following subcutaneous fat necrosis.

Although subcutaneous fat necrosis resolves spontaneously and is benign, it requires careful attention. Rare complications such as hypercalcemia, hypoglycemia, hypertriglyceridemia, and thrombocytopenia may be associated with it [6]. In this case report, the complication of hypertriglyceridemia was observed in the infant, who provided a stronger suspicion for the diagnosis of this lesion, but no other complications were observed. It was also noteworthy that according to the definition of hyperlipidemia in neonates [8], the baby had severe hyperlipidemia. Although clinical diagnosis and ruling out of other factors is the essential and primary principle in diagnosing this lesion, definitive diagnosis is confirmed with skin biopsy and pathology that was not possible in the above case due to parental dissatisfaction [9].

In terms of the site of involvement, the most common site of involvement, like the above-presented case, is the trunk and back and is rarely seen in other areas. In a case report, symmetrical and bilateral involvement of the axilla was reported in an infant, but no other complications were seen [10].

Although thrombocytopenia had previously been reported as a complication of this lesion, Sahn et al, reported a case of subcutaneous fat necrosis associated with thrombocytosis instead of thrombocytopenia, which was the first case. The authors stated that the thrombocytosis could be due to the reactive inflammatory response of subcutaneous fat necrosis because inflammatory cells were found in the fat lobule in the patient's skin biopsy [11].

Hypercalcemia is a life-threatening complication of subcutaneous fat necrosis that was not seen in the presented patient despite being checked serially. The time of onset of lesions in subcutaneous fat necrosis is from one day to twenty days after birth, but it can also be seen after discharge and up to 6 weeks after birth [3, 4]. In one article, the clinical signs of subcutaneous fat necrosis were observed 10 weeks after birth in a baby with asphyxia. Calcification of the soft tissue of the lower limbs was seen on plain X-ray at the same time, but no biopsy was performed on this baby and no laboratory abnormalities were seen and the diagnosis was made based on clinical signs same as the presented case in this article [12].

No cooling treatment was performed in the introduced newborn, but in recent years, subcutaneous fat necrosis has been reported as a complication of whole-body cooling for the treatment of asphyxia. On the other hand, subcutaneous fat necrosis has also been reported in asphyxiated infants who have not received cooling therapy. Whether subcutaneous fat necrosis is the primary complication of hypoxia and ischemia, or whether it is caused by skin exposure to low temperatures and cold stimulation, is still unclear and needs further investigation. It also seems that the severity of asphyxia does not affect subcutaneous fat necrosis associated with ischemia [13].

In the presented patient here, the lesion healed two months and hyperlipidemia improved four months after birth. Lara et al in a study with five cases reported an average of 3.2 months for the time of recovery [3]. However, since some complications usually coincide with the onset of the lesion, some complications, such as hypercalcemia, may occur up to 6 months after the onset of the lesion. Therefore, long-term follow-up of these infants for serum calcium level is necessary [3].

The study of this infant had several limitations. First, Given that the umbilical cord blood gases were not examined at the hospital where the baby was born, it remained difficult to make a definitive initial diagnosis of asphyxia and early intervention. Second, the impossibility of performing a biopsy due to parental dissatisfaction limited the definitive and rapid diagnosis of subcutaneous fat necrosis.

Conclusion

Although subcutaneous fat necrosis is a rare disease, it should be considered in infants with asphyxia, even in mild stages. Attention and monitoring of rare short-term and long-term metabolic disorders that can be life-threatening should be considered until the lesion is completely healed.

Acknowledgments

The author of this paper would like to thank the baby's parent who offered informed consent to disclose the clinical information in this paper.

Ethical Code

Ethical approval was obtained for this report from the Research Ethics Committee of Mazandaran University of Medical Sciences (IR.MAZUMS.REC.1400.11538).

Funding

This study was self-funded.

Conflict of interest

There was no conflict of interest

References

1. Kannenberg SM, Jordaan HF, Visser WI, et al. Report of 2 novel presentations of subcutaneous fat necrosis of the newborn. *Dermatopathol* 2019; 6(2): 147-52.
2. Del Pozzo-Magaña BR, Ho N. Subcutaneous fat necrosis of the newborn: a 20-year retrospective study. *Pediatr Dermatol* 2016; 33(6): e353-5.
3. Lara LG, Villa AV, Rivas MM, et al. Subcutaneous Fat Necrosis of the Newborn: Report of Five Cases. *Pediatr Neonat* 2017; 58(1): 85-8.
4. Akcay A, Akar M, Oncel MY, et al. Hypercalcemia due to subcutaneous fat necrosis in a newborn after total body cooling. *Pediatr Dermatol* 2013; 30(1): 120-3.
5. Muzy G, Mayor SA, Lellis RF. Subcutaneous fat necrosis of the newborn: clinical and histopathological correlation. *Bras Dermatol* 2018; 93(3): 412-4.
6. Aye MS, Mahaseth M, Rozzelle A, et al. Newborn With Enlarged Erythematous Mass on Back: Case Report and Review of Medical Literature. *Glob Pediatr Health* 2018; 5: 2333794X18803552.
7. Onyiriuka AN, Utomi TE. Hypocalcemia Associated with Subcutaneous Fat Necrosis of the Newborn: Case Report and Literature Review. *Oman Med J* 2017; 32(6): 518-21
8. Bhatia S, Joshi P, Kishore J, Jha C. A neonatal hypertriglyceridemia presenting with respiratory distress: A rare case report. *Int J Contemp Pediatr* 2018; 5(6): 2347.
9. Lorenzo C, Romana A, Matias J, Calhau P. Subcutaneous fat necrosis of the newborn-An atypical case with typical complications. *Clin Case Rep* 2021; 9(4): 2069-73.
10. Al Shidhani KS, Al Maani AS, Al Jabri AT. A rare presentation of a newborn with subcutaneous fat necrosis. *Oman Med J* 2013; 28(4): e54.
11. Sahni M, Patel P, Muthukumar A. Severe Thrombocytosis in a Newborn with Subcutaneous Fat Necrosis and Maternal Chorioamnionitis. *Case Rep Hematol* 2020; 2020:5742394.
12. Alaoui K, Abourazzak S, Oulmaati A, et al. An unusual complication of subcutaneous fat necrosis of the newborn. *BMJ Case Rep* 2011; 2011: bcr1220103569.
13. Grass B, Weibel L, Hagmann C, Brotschi B. Subcutaneous fat necrosis in neonates with hypoxic ischaemic encephalopathy registered in the Swiss National Asphyxia and Cooling Register. *BMC Pediatr* 2015; 15(1): 1-7.