

Periorbital Edema as the Presentation of COVID-19 in Children: A Case Report

Gholamreza Soliemani¹ , Saeedeh Yaghoubi^{*1} , Elham Shafighi Shahri² , Elnaz Shafighi Shahri³ 

1. Children and Adolescent Health Research Center, Zahedan University of Medical Science, Zahedan, Iran.

2. Department of Pediatric Endocrinology, Zahedan University of Medical Science, Zahedan, Iran.

3. Zabol University of Medical Sciences, Zabol, Iran.

*Corresponding Author: Dr. Saeedeh Yaghoubi (MD);

Address: Department of Pediatrics, Ali Ibn Abitaleb Hospital, Persian Gulf Boulevard, 98167-43111, Zahedan, Iran.

Tel.: +98 5433295571, Fax: +98 5433295563 E-mail: yaghoubimd@yahoo.com, s.yaghoubi@zaums.ac.ir

Article Info.

Article type:

Case Report

Received: 11 Sep 2021

Revised: 20 Nov 2021

Accepted: 29 Dec 2021

Published: 6 March 2022

Keywords:

Child,

COVID-19,

Fever,

Periorbital Edema

ABSTRACT

Background and Objective: COVID-19 is a new respiratory infection caused by the Coronavirus, which the World Health Organization (WHO) declared a global pandemic in 2019. The clinical course of the infection in children differs from adults. With a variety of presentations, COVID-19 poses a great diagnostic challenge for physicians. Here, we present a child with COVID-19, who presented with fever and periorbital edema.

Case Report: A 3-year-old boy came into the hospital with periorbital edema and fever. He had no respiratory and gastrointestinal symptoms, his laboratory tests revealed only hypoalbuminemia and he had no prior history of any other diseases. His nasopharyngeal swab PCR came back positive for Covid-19.

Conclusion: Fever and periorbital edema are rare manifestations of COVID-19 in infected children, further medical research is required to find the cause of this problem. Finding the scientific explanation for this complication can lead to better insight for diagnosis and even reveal possible effective treatments.

Cite this Article:

Soliamani Gh, Yaghoubi S, Shafighi Shahri E, Shafighi Shahri E. Periorbital Edema as the Presentation of COVID-19 in Children: A Case Report. *Caspian J Pediatr* March 2022; 8(1): 679-83.

Introduction

Coronavirus (COVID-19) is a worldwide pandemic that has become one of the greatest challenges of the century. Clinical symptoms vary from asymptomatic to life-threatening in patients [1]. The vast clinical manifestation made it a great challenge for physicians to appropriately diagnose the patients. The most common symptoms are fever, shortness of breath, cough, myalgia, diarrhea and so on. [2]. Children with coronavirus appear to have a mild clinical course, but in some cases, they present in much more severe conditions [3]. Less common clinical signs -particularly in children- include skin lesions such as urticaria and Kawasaki-like manifestations [4].

Generally, periorbital edema is caused by an acute vascular reaction on the dermis and subcutaneous tissue around the eye [5]. This local edema is caused by capillary dilation and permeability due to the outflow of serous fluid. Edema around the eyes can be a symptom of many disorders such as congenital disorders, trauma, renal, hepatic, insect bites, hypersensitivity reactions, orbital neoplasms, orbital cellulitis, and periorbital cellulitis, and even hypothyroidism [6,7].

Albumin is a single-chain protein with a molecular weight of 66 kilodalton (kDa) that makes up more than 50% of serum proteins. Hypoalbuminemia is one of the most prevalent disorders in hospitalized and critically ill patients. Hypoalbuminemia may be a result of decreased production (rare) of albumin or increased loss of albumin via the kidneys, gastrointestinal (GI) tract, skin, or extravascular space or increased catabolism of albumin or a combination of 2 or more of these mechanisms [8].

A COVID-19 infection manifesting itself as fever and periorbital edema is very rare, thus in this case report, we present a child with these manifestations and nothing else but a positive COVID-19 PCR.

Case Report

A 3-year-old boy was referred to the pediatric emergency department of the University Hospital in Zahedan-Iran with a chief complaint of fever and

periorbital edema. The patient was initially visited by a pediatrician.

The fever of 39°C started 4 days before hospitalization. The patient had developed periorbital edema on the day before the visit. He complained of weakness, lethargy, and anorexia. Cough, respiratory symptoms, and gastrointestinal symptoms were not mentioned. He was in good health, had normal development and, denied a history of food and drug allergies, hemorrhagic disease, heart disease, tuberculosis, bronchiolitis, or asthma. The family history for the mentioned conditions was negative as well. The child was vaccinated according to the national vaccination program. He was alert during the examination. He did not have respiratory distress.

Vital signs were evaluated and charted as below: Temperature 39 ° C, Pulse rate 120 times per minute, Respiratory rate 30 times per minute, Blood pressure 95/60 mmHg, SpO2 99% in room air. There were no throat congestions, no swelling of the tonsils, no otitis, no Petechiae and purpura lesions, no Lymphadenopathy and, normal lung and heart sounds were recorded. The patient only had bilateral periorbital edema. Examination of the limbs and abdomen was normal.

The Laboratory data were checked at this center and the results were as below: leukocyte $9.9 \times 10^9/L$, erythrocyte $4.73 \times 10^{12}/L$, neutrophil ratio 83.9%, lymphocyte ratio 9.12%, hemoglobin 13 g/L, platelet $108 \times 10^9/L$, CRP 96, ESR 14, Na 128, K 3.5, Total protein 3.8, Alb 2.4 (Table 1). The patient's Covid-19 PCR test was positive. The chest X-ray of the patient was normal. (Fig.1) Abdominal and pelvic ultrasounds were performed and their results were normal. The patient underwent supportive measures and his fever was controlled.

Other differential diagnoses including renal, hepatic, allergies conditions, insect bites, trauma, orbital cellulitis, and periorbital cellulitis were rolled out. Supportive measures including fever control and serum therapy were performed for the patient and Albumin was administered to the patient at a dose of 1gr/Kg/day for 3 days. Afterward, the patient's symptoms dramatically improved, and on the 5th day of hospitalization, the patient was

discharged in good general condition. The patient's periorbital edema completely disappeared.

Discussion

In the present case report, we described SARS-CoV-2 in a child whose clinical signs at the onset of the disease were fever and periorbital edema associated with hypoalbuminemia with no respiratory complaints.

Periorbital edema is caused by an acute vascular reaction on the dermis and subcutaneous tissue around the eye [5]. This local edema is caused by capillary dilation and permeability due to the outflow of serous fluid. Edema around the eyes can be a symptom of many disorders such as congenital disorders, trauma, renal, hepatic, insect bites, hypersensitivity reactions, orbital neoplasms, orbital cellulitis, and periorbital cellulitis [6, 7].

Greene et al. reported a case of MIS-C (Multisystem Inflammatory Syndrome) in a child who had been to the emergency room twice, and a second visit revealed symptoms of distributed shock, multiple organ damage, and systemic inflammation associated with COVID-19. There was evidence of cardiac and renal dysfunctions, but no liver involvement or hypoalbuminemia. This was the opposite of our patient [9].

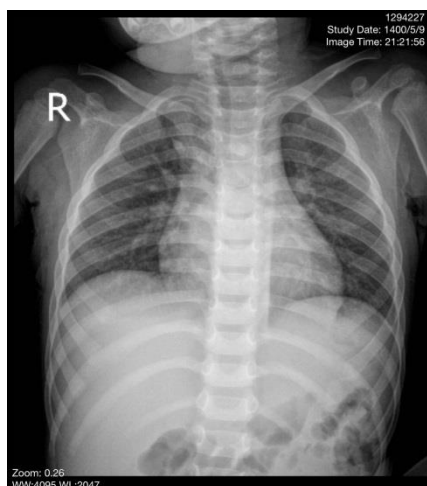


Fig 1. Chest X-ray of the patient; No obvious pathologic findings

Table 1. Laboratory test results plus their normal ranges based on our laboratory kits

Lab test	Results	Normal Range
Leukocyte	$9.9 \times 10^9/L$	$4 \times 10^9/L - 10 \times 10^9/L$
Erythrocyte	$4.73 \times 10^{12}/L$	$4 \times 10^{12}/L - 6 \times 10^{12}/L$
Neutrophil ratio	83.9%	35-40%
Lymphocyte ratio	9.12%	60-65%
Hemoglobin	13 g/L	11-13 g/L
Platelet	$108 \times 10^9/L$	$150-450 \times 10^9/L$
CRP	96	<10
ESR	14	<10
Bun	10	7-20
Cr	0.4	<0.7
Na	128	135-145
K	3.5	3.5-5
Ast	29	17-20
Alt	49	17-20
PT	11	10-12
PTT	21	22-35
INR	1	0.9-1.1
Total protein	3.8	5-7
Alb	2.4	3.5-5
Triglyceride	178	<200
Cholesterol	121	<170

Saeed Amir et al. reported a 3-year-old previously healthy boy who presented with recurrent fevers, seizures, epilepsy attacks. The patient's Covid-19 PCR test was positive, and his brain CT scan showed cerebral edema. 5 days later, intracerebral hemorrhage was observed on an MRI of the brain [10]. With no other explanation but his positive Covid-19 PCR, it was concluded that this was a completely different manifestation of Covid-19.

Another report described a 16-year-old boy with fever, myalgia, and mild shortness of breath and, dark urine. PCR for COVID-19 was positive. There was an increase in creatinine kinase (CK) levels and evidence of rhabdomyolysis [11]. This was a completely different manifestation from Covid 19 but hypoalbuminemia and edema were not reported.

Albumin is a single-chain protein with a molecular weight of 66 kDa that makes up more than 50% of serum proteins. Albumin was first isolated from other plasma components in 1944 by

Edwin Cohn, and serum albumin levels were recognized as an important indicator of liver function [12].

Also, serum albumin is a key nutritional parameter for determining the degree of malnutrition and prognosis in patients with liver cirrhosis. Albumin administration is currently a standard treatment in patients with advanced liver disease and hypoalbuminemia but is prescribed to critically ill patients in the ICU whether or not they have liver disease. This happens to be a currently controversial subject within the field [13].

In COVID-19 infection, we encounter a cytokine storm that can lead to vascular damage and occasionally thrombosis and death. Albumin is an acute-phase protein that is reduced during infection due to its anti-inflammatory and antioxidant effects. On the other hand, hypoalbuminemia can lead to the disruption of the body's inflammatory immune response, thus increasing inflammation and eventually leading to multi-organ damage. Albumin also has anticoagulant and antiplatelet activities, so reducing it may increase the risk of thrombosis [14].

According to previous studies, hypoalbuminemia is more common in cases of moderate to severe COVID-19 infection or in children with life-threatening conditions, such as those with multiple inflammatory system syndromes [15]. But our study results are different.

Another study showed low albumin levels (mean=3.4 g/dL) in children with COVID-19 and multiple inflammatory system syndromes [16].

Liver test abnormalities can be seen in other infections, such as influenza H1N1 in addition to COVID-19 [17]. Our patient had normal liver enzymes and only had hypoalbuminemia.

Limitations of the study

One of the limitations of our study was the absence of any submitted cases similar to ours.

The etiology of periorbital edema is not so clear. It may be related to the direct viral invasion or maybe due to hypoalbuminemia. This question remains to be answered.

More research is required to find the cause of this complication. Finding these causes can lead to

better insight into the diagnosis and treatment of this disease.

Conclusion

A rare and quite new manifestation of Covid-19 in infected children is fever and periorbital edema as presented in this report.

Acknowledgments

We would like to thank all the staff members and employees at Ali-Ebne abitaleb Hospital for their contributions to this study.

Ethical approval

The Ethics Committee of Zahedan University of Medical Sciences approved this study ([IR.ZAUMS.REC.1401.055](https://doi.org/10.21859/IR.ZAUMS.REC.1401.055)).

Funding

The authors received no financial support for the research, authorship, and/or publication of this article.

Conflict of interest

The authors declared no potential conflicts of interest with respect to the research, authorship, and/or publication of this article.

References

1. Guan WJ, Ni ZY, Hu Y, et al. Clinical characteristics of coronavirus disease 2019 in China. *New Engl J Med* 2020; 382(18): 1708-20.
2. Huang C, Wang Y, Li X, et al. Clinical features of patients infected with 2019 novel coronavirus in Wuhan, China. *Lancet* 2020; 395(10223): 497-506. doi:10.1016/S0140-6736(20)30183-5.
3. Jiehao C, Jin X, Daojiong L, et al. A Case Series of children with 2019 novel coronavirus infection: clinical and epidemiological features. *Clin Infect Dis* 2020; 71(6): 1547-51.
4. Recalcati S. Cutaneous manifestations in COVID-19: a first perspective. *J Eur Acad Dermatol Venereol* 2020; 34(5). doi:10.1111/jdv.16387
5. Rafailidis PI, Falagas ME. Fever and periorbital edema: a review. *Surv Ophthalmol* 2007; 52(4): 422-33. doi:10.1016/j.survophthal.2007.04.006

6. Albu CV, Catalin B, Zaharia C. A rare case of ocular myositis. *Curr Health Sci J* 2014; 40(1): 71-4. doi:10.12865/CHSJ.40.01.14
7. Erras S, Benjilali L, Essaadouni L. Periorbital edema as initial manifestation of chronic cutaneous lupus erythematosus. *Pan Afr Med J* 2012; 12(1): 57.
8. Weaving G, Batstone GF, Jones RG. Age and sex variation in serum albumin concentration: an observational study. *Ann Clin Biochem* 2016; 53(1): 106-11.
9. Greene AG, Saleh M, Roseman E, Sinert R. Toxic shock-like syndrome and COVID-19: multisystem inflammatory syndrome in children (MIS-C). *American J Emerg Med* 2020; 38(11): 2492-e5.
10. Saeed A, Shorafa E. Status epilepticus as a first presentation of COVID-19 infection in a 3 years old boy; Case report and review the literature. *IDCases* 2020; 22: e00942.
11. Gefen AM, Palumbo N, Nathan SK, et al. Pediatric COVID-19-associated rhabdomyolysis: A case report. *Pediatr Nephrol* 2020; 35(8): 1517-20.
12. Cohn EJ, Oncley JL, Strong LE, et al. Chemical, clinical, and immunological studies on the products of human plasma fractionation. The characterization of the protein fractions of human plasma. *J Clin Invest* 1944; 23(4): 417-32.
13. Wujtewicz M, Dylczyk-Sommer A, Aszkiełowicz A, et al. COVID-19 - what should anaesthesiologists and intensivists know about it? *Anaesthesiol Intensive Ther* 2020; 52(1): 34-41.
14. Violi F, Pastori D, Cangemi R, et al. Hypercoagulation and antithrombotic treatment in coronavirus 2019: A new challenge. *Thromb Haemost* 2020; 120(6): 949-56.
15. Feldstein LR, Rose EB, Horwitz SM, et al. Multisystem inflammatory syndrome in U.S. children and adolescents. *N Engl J Med* 2020; 383(4): 334-46.
16. Mamishi S, Movahedi Z, Mohammadi M, et al. Multisystem inflammatory syndrome associated with SARS-CoV-2 infection in 45 children: a first report from Iran. *Epidemiol Infect* 2020; 148.
17. Soleimani G, Shahri ES. Liver function tests abnormality in influenza H1N1 in Southeastern of Iran. *Biomed Res India* 2017; 28(3): 1050-3.