

Vomiting recurrence after para-esophageal hernia repair according to foreign body ingestion: A case report

Case Report

Sanaz Mehrabani (MD) ^{1*}
Abbas Hadipour (MD) ²

1. Non-Communicable Pediatric Diseases Research Center, Health Research Institute, Babol University of Medical Sciences, Babol, IR Iran.
2. The Clinical Research Development Unit of Amirkola Children's Hospital, Babol University of Medical Sciences, Babol, IR Iran.

* Correspondence:

Sanaz Mehrabani (MD), Non-Communicable Pediatric Diseases Research Center, No 19, Amirkola Children's Hospital, Amirkola, Babol, Mazandaran Province, 47317-41151, IR Iran.

E-mail: mehrabanisanaz@yahoo.com

Tel: +98 1132346963

Fax: +98 1132346963

Received: 10 Dec 2017

Revised: 9 Jan 2018

Accepted: 6 Feb 2018

Abstract

Background: Foreign body ingestion and food bolus impaction are among frequent causes of mortality in pediatrics.

Case report: An 18-month girl who had foreign body ingestion presenting with recurrent vomiting after para-esophageal hernia repair was referred to Amirkola Children's Hospital. She underwent open surgery, but the symptoms re-occurred. Endoscopic evaluation showed foreign bodies in the esophagus, removed by endoscopic basket.

Conclusions: After hiatal hernia or any esophageal surgery in children with recurrence of vomiting, the foreign body ingestion should be considered.

Key Words: Foreign Body, Para-Esophageal Hernia, Pediatric

Citation:

Mehrabani S, Hadipour A. Vomiting recurrence after para-esophageal hernia repair according to foreign body ingestion: A case report. *Caspian J Pediatr* March 2018; 4(1): 294-6.

Introduction

Prolapse of intra-hiatal organs through the esophageal hiatus is defined as esophageal hiatal hernia ^[1]. Its symptoms contain abdominal pain, nausea, vomiting, poor growth, dark stool, breathing problems, reflux and cough ^[2]. It has four types including a) sliding hiatal hernias (type I) as the most common type (85–95%), b) para-esophageal hernias (type II) which are 3.5% -5% of all types, c) mixed hernias (type III) forming 10%, and d) type IV (complicated form) found in up to 5% ^[3, 4]. Acute dilatation, bleeding, gastric obstruction and perforation are among possible complications of type III and IV ^[1]. The choice of treatment is a laparoscopic repair with fundoplication ^[5]. On the other hand, one of the prominent causes of death in children is foreign body ingestion and food bolus impaction as well as the peak age is from 6 months to 3 years old ^[3]. Foreign body ingestion is associated with higher risk of complications (near 20%), leading to endoscopic or surgical removal ^[4]. Dysphagia, drooling, wheezing, stridor or choking could be clinical manifestations. Here, we present a girl with food impaction and para-esophageal hiatal hernia, who underwent surgical treatment. Food impaction was detected three weeks after surgery due to no clinical improvement and recurrence of symptom.

Case presentation

An 18-month girl with the weight of 11.5 kg was referred to Amirkola Children's Hospital clinic (North of Iran) with recurrent vomiting (sometimes biliary vomiting) and resistant gastro-esophageal reflux disease (GERD) in April 2017. Her parents are relatives. Empirical treatment including ranitidine, omeprazole, and dietary elimination did not improve the clinical symptoms. Liver functional test (LFT), amylase, lipase and abdominopelvic ultrasonography evaluation were all normal.

Barium study showed type III para-esophageal hiatal hernia (figure 1). Endoscopic evaluation revealed para-esophageal hiatal hernia without erosion and ulcer. The patient underwent open trans-abdominal surgery with fundoplication in Amirkola Children's Hospital in May 2017. She became symptom free after surgery. After three weeks, she referred with recurrent vomiting (not biliary) and dysphagia. There was no history of food impaction. It was thought that her symptoms could be due to the surgery complications; thus, the barium study and endoscopic evaluation were considered for her. Endoscopic evaluation revealed food impaction removed by endoscopic basket (Figure 2 and 3). No barium study was done again, since her symptoms cured. The extracted items included loquat peel and seeds, which is a special fruit of Mazandaran province of Iran. Follow-up endoscopy revealed no erosion or ulcer in the esophagus after one month.

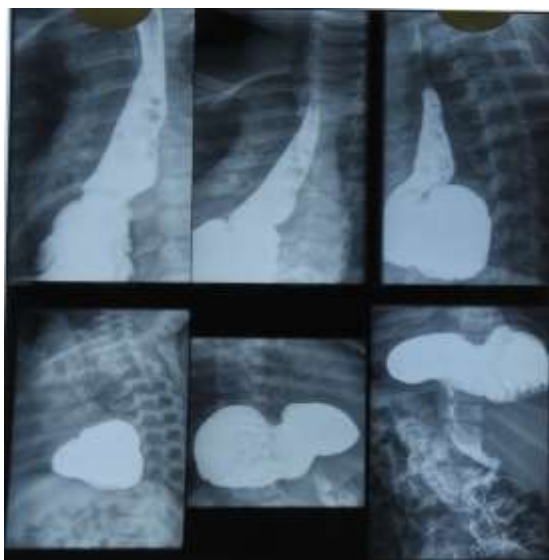


Figure 1: Barium study findings before surgery



Figure 2: Foreign bodies (loquat)

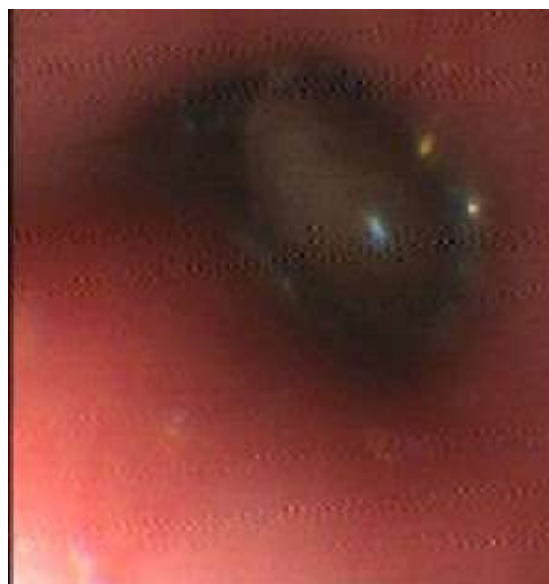


Figure 3: Endoscopic finding (foreign bodies in the esophagus)

Discussion

One of the most common problems in childhood is foreign body ingestion and food impaction, requiring endoscopic therapy [6]. Mental or psychiatric disorders, alcohol consumption, bulimia, prisoners, gastrointestinal anatomical disorders and young age could be predisposing factor for foreign body ingestion [3]. Most foreign bodies pass through digestive-tract and due to size and shape, various range of complications may occur, leading to surgical or endoscopic procedures [4]. Risk of perforation is estimated as 1%, while removal procedures are required in 10-20% [7, 8]. Elongated materials are common foreign bodies in esophagus and stomach that need surgery for removal [9]. Our patient with hiatal hernia swallowed loquat seeds. It seemed that open surgery did not heal the symptoms or complications because her vomiting relapsed. By means of endoscopic basket, the seeds were extracted.

Previously, the rigid esophagoscopy was the treatment of choice, while nowadays, the flexible endoscopy is used for treatment goals [7]. Previous studies illustrated that most patients with food impaction had foreign bodies, who had swallowed objects which were not digestible (in males more than females with ratio of 1.7/1).

Acquired hiatal hernia can be found in children with cerebral paralysis, chronic connective tissue diseases such as Ehlers-Danlos syndrome and Marfan syndrome as well as postoperative complication of anti-reflux surgery [10, 11]. Our patient was an 18-month girl who had failure of anti-reflux medical treatment and underwent

open abdominal surgery. She had swallowed loquat seeds, which is a local fruit of Mazandaran province of Iran. Loquat is an oval, rounded or pear-shaped fruit in yellow color that has one to ten ovules which containing seeds. It is originally from China while it could be found in Georgia, Armenia, Afghanistan, Australia, Azerbaijan, Bermuda, Chile, Kenya, India, Iran, Iraq and South Africa. In different regions, different impactions would be possible. For instance, in Greece, the most common is pork, in USA the most common is meat, in Asia is fish^[12]. Loquat is a local fruit of the North of Iran. Our patient ingested a lot of seeds, which caused food impaction.

After hiatal hernia or any esophageal surgery in children with vomiting symptom recurrence, the foreign body ingestion should be considered.

Acknowledgment

We are grateful to the Clinical Research Development Committee of Amirkola Children's Hospital of Babol University of Medical Sciences for their contribution to this study.

Funding: None.

Conflict of interest: There was no conflict of interest.

References

1. Mattar SG, Bowers SP, Galloway KD, et al. Long-term outcome of laparoscopic repair of paraesophageal hernia. *Surg Endoscop Other Intervention Techniq* 2002; 16(5): 745-9.
2. Muller-Stich BP, Holzinger F, Kapp T, Klaiber C. Laparoscopic hiatal hernia repair: long-term outcome with the focus on the influence of mesh reinforcement. *Surg Endosc* 2006; 20(3): 380-4.
3. Katsinelos P, Kountouras J, Paroutoglou G, et al. Endoscopic techniques and management of foreign body ingestion and food bolus impaction in the upper gastrointestinal tract: a retrospective analysis of 139 cases. *J Clin Gastroenterol* 2006; 40(9): 784-9.
4. Eisen GM, Baron TH, Dominitz JA, et al. Guideline for the management of ingested foreign bodies. *Gastrointest Endosc.* 2002;55(7):802-6.
5. Namgoong JM, Kim DY, Kim SC, Hwang JH. Hiatal hernia in pediatric patients: laparoscopic versus open approaches. *Ann Surg Treat Res* 2014; 86(5): 264-9.
6. Longstreth GF, Longstreth KJ, Yao JF. Esophageal food impaction: epidemiology and therapy. A retrospective, observational study. *Gastrointest Endoscop* 2001; 53(2): 193-8.
7. Webb WA. Management of foreign bodies of the upper gastrointestinal tract: update. *Gastrointest Endoscop* 1995; 41(1): 39-51.
8. Feldman M, Friedman LS, Sleisenger MH. Sleisenger & Fordtran's gastrointestinal and liver disease: pathophysiology, diagnosis, management 10th Ed [CD-ROM] Philadelphia: Saunders. 2016: pp: 426-38.
9. Chang JJ, Yen CL. Endoscopic retrieval of multiple fragmented gastric bamboo chopsticks by using a flexible overtube. *World J Gastroenterol* 2004; 10(5): 769.
10. Khanna A, Finch G. Paraesophageal herniation: a review. *Surgeon* 2011; 9(2): 104-11.
11. Parida SK, Kriss VM, Hall BD. Hiatus/paraesophageal hernias in neonatal Marfan syndrome. *American J Med Genetics* 1997; 72(2): 156-8.
12. Stack LB, Munter DW. Foreign bodies in the gastrointestinal tract. *Emerg Med Clin North Am* 1996; 14(3): 493-521.