

# Lymphoma infectious mononucleosis by Epstein-Barr virus: A case report

## Case Report

Mahmoud Khodabandeh (MD) <sup>1</sup>

Mohsen Mohammadi (MD) <sup>2\*</sup>

Katayoun Borhani (MD) <sup>1</sup>

Elmira Khodabakhsh (MD) <sup>3</sup>

1. Department of pediatrics, School of Medicine, Tehran University of Medical Science, Tehran, Iran.
2. Non-Communicable Pediatric Diseases Research Center, Health Research Institute, Babol University of Medical Sciences, Babol, IR Iran.
3. Department of Surgery, School of Medicine, Mazandaran University of Medical Science, Sari, Iran.

### \* Correspondence:

**Mohsen Mohammadi (MD)** Non-Communicable Pediatric Diseases Research Center, No 19, Amirkola Children's Hospital, Amirkola, Babol, Mazandaran Province, 47317-41151, IR Iran.

**E-mail:** dr.mohamadi61@yahoo.com

**Tel:** +98 1132346963

**Fax:** +98 1132346963

**Received:** 25 June 2017

**Revised:** 22 July 2017

**Accepted:** 18 Aug 2017

### Abstract:

**Background:** Epstein-Bar virus (EBV) causes infectious mononucleosis in more than 90% of children. Rarely, mononucleosis may lead to malignancy. The aim the current study was to introduce a child with mononucleosis and persistent adenopathy.

**Case report:** A 4-year-old male patient presented with complaints of fever, shortness of breath and sore throat. He was treated with antibiotics and prednisolone. Normal flora was grown by pharynx and blood cultures. Due to the high clinical suspicion (persistent large lymph nodes), open biopsy of cervical lymph nodes was done after 3 weeks and Non-Hodgkin lymphoma disease was diagnosed in the biopsy.

**Conclusions:** Atypical presentation should be considered for every child and biopsy is inevitable in larger and persistent lymphadenopathy after 2 weeks. Because of poor prognosis and high mortality rate, early detection of lymphoma is very important.

**Key Words:** Viruses, Epstein-Bar Virus, Lymphadenopathy, Infectious Mononucleosis

### Citation:

Khodabandeh M, Mohammadi M, Borhani K, Khodabakhsh E. Lymphoma infectious mononucleosis by Epstein - Barr virus: A case report. Caspian J Pediatr Sep 2017; 3(2): 257-60.

### Introduction:

Epstein-Barr virus (EBV) which is responsible for more than 90% of infectious mononucleosis in children and known as human herpesvirus 4 (HHV-4) is one of the eight known human herpes types [1, 2]. The triad of sore throat, fever, and lymphadenopathy are the main symptoms in patients with mononucleosis. Abnormality in size, number or consistency of lymph nodes is defined as lymphadenopathy [3]. Lymphadenitis is the swollen lymph nodes which appear as painful lumps in the neck, armpits or groin. A comprehensive medical and social history as well as the history of drug use should be obtained from all patients for lymphadenopathy evaluation. The presence of an enlarged spleen and swollen inguinal, axillary and cervical lymph nodes is most useful for diagnosis of infectious mononucleosis [1, 2]. EBV is an epidemic herpes virus that spreads on a worldwide scale and infects a large proportion globally. Children are infected at a young age (<6 years old), while in developed countries, more than half of the populations are susceptible to the virus, up to the puberty [2, 4, 5]. Non-Hodgkin's lymphoma (NHL) and Hodgkin's lymphoma (HL) are neoplasms arising from cells of the lymphoid lineage. Lymphoma may also result from a variety of the interaction between multiple genes and environmental factors. EBV has been considered a leading candidate as a trigger for several neoplasms [6, 7]. EBV infection enhances an individual's risk of affecting certain types of fast-growing lymphomas like Burkitt lymphoma and nasopharyngeal cancer [8, 9].

Hodgkin lymphoma and some cases of stomach cancer may be associated with EBV infection. Other more "typical" complications comprise rupture of the spleen and hemorrhage, difficulty in breathing and airway obstruction. In general practice, less than one percent of patients affected with LAP have suffered from malignant disease, especially in pediatrics [2, 10]. An infection which spreads from a nose, eye, skin or eye to the lymph nodes causes lymphadenitis. A thorough physical examination and history, and focused laboratory studies usually exclude life-threatening causes of disease [2]. The most common types of malignancy in patients with infectious mononucleosis are leukemia and lymphoma which are less common causes in healthy children [7, 10]. Hence, we report a child with symptoms similar to infectious mononucleosis and lymphoma.

### Case Report:

A 4-year-old boy presented with an acute onset of dyspnea, pharyngitis and fever. He had been admitted earlier to another center. Because of classic triad of fever, adenopathy and exudative pharyngitis, he was treated with antibiotics and corticosteroid. His problem was not resolved at the end of treatment, and he was referred to our center. He was the second child of the family, and there was no history of previous hospitalization. Cervical CT scan indicated multiple adenopathies. He was treated with prednisolone due to the mechanical ventilation for severe airway obstruction (respiratory distress) in ICU. When the clinical conditions were better than initially signs and symptoms, he was discharged from first center after 7 days, and immediately referred to us with persistent cervical lymphadenopathy.

An ENT examination showed that the size of his tonsils was larger than usual compared to other children and enlarged lymph nodes were detected in submandible and posterior cervical.

Vital signs included initially:

BP: 110/75 mmHg, RR: 22/min, PR: 100/min, T: 39°C.

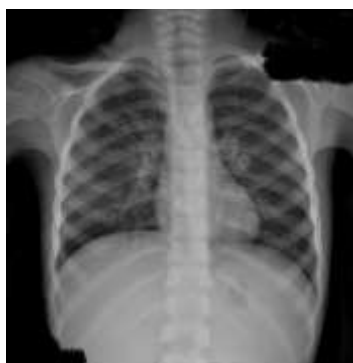The spleen enlarged to several times larger than its normal size and extended into the abdomen. Other examinations were normal.

In primary lab data:

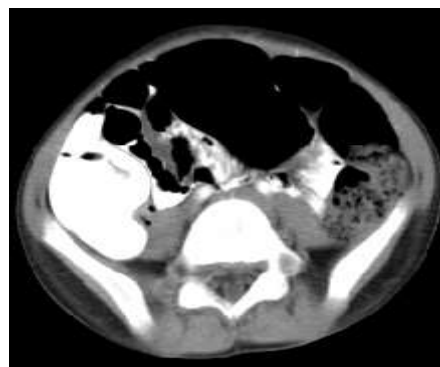
CBC: WBC:  $7.8 \times 10^3/\mu\text{l}$ , POLY: 50%, LYMPH: 40%, MONO: 5.5%, PLT:  $271 \times 10^3/\mu\text{l}$ , BS: 101 mg/dl, BUN: 11 mg/dl, Cr: 0.5 mg/dl, LDH: 100 U/L, Uric Acid: 2.5 mg/dl, ESR: 101 mm/hour, CRP: 8 mg/dl, U/A: NL

Chest X-ray was taken and perihilar adenopathy was seen (fig 1). Peripheral blood smear demonstrated hypochromic microcytosis anemia. Normal flora was grown by pharynx and blood cultures in BACTEC medium. He became stable, his fever was discontinued and prednisolone gradually reduced. Real time PCR and VCA IgM was positive for EBV. Abdominal ultrasound revealed multiple lymph nodes and splenomegaly (13 cm). In the next step, abdominal CT scan was performed and for further studies, bone marrow aspiration and biopsy were carried out, which were normal.

Other investigations included HIV test, immune system evaluation, and CH50, which were negative. The abdominal CT scan illustrated the multiple lesions in the terminal ileum with a pattern of inflammatory diseases (fig 2). Although EBV was the cause of the disease, cervical lymph node biopsy was performed. As a result, Hodgkin lymphoma was found and he was treated with chemotherapy.



**Figure 1. Chest X-ray of our patient**



**Figure 2. Abdominal CT scan of our patient**

## Discussion:

Concurrent lymphoma and EBV infection was important matter in our case. Unusual reaction to EBV is more common in adults than in children [12]. We introduce this rare presentation in our case report.

In some cases, latent virus may be reactivated. "EBV-associated" cancers are determined by the proliferation of monoclonal EBV-infected cells with limited latent viral gene expression. Disturbance of normal growth control mechanisms within a cell may lead to the uncontrolled cell division and cancer development [6, 13, 14].

Evidence has been suggested that the failure of the EBV-specific immunity may play a role in the pathogenesis of EBV-associated tumors, and manifest the immunodeficiencies in patients. Our patient had normal immune system.

Epskamp et al. reported a 50-year-old man with symptoms of fever, lymphadenopathy and splenomegaly and found that PCR was positive for EBV as well as his pathobiopsy indicated B cell lymphoma [15]. However, our patient had two different characteristics: 1) positive serology and 2) he was a child.

Viral pharyngitis is most common in young children and its incidence decreases with age. Often, it is self-limiting and benign, while in our case, the most severe form of the viral pharyngitis has presented as lymphoma [16].

Two cases of adult patients with Hodgkin's lymphoma and Epstein-Barr virus were evaluated and RNA PCR was positive, too [17]. Of course, our patient's presentations were different: 1) they had a manifestation of disease after chemotherapy, caused by a potential impairment of immunity and 2) it occurred after their puberty.

Although prolonged use of corticosteroid may be associated with an increased risk of malignancy in mononucleosis, it has not been proved in recent studies [16, 18]. Moreover, it seemed unlikely that the use of prednisolone could interfere with the process in our patient during these short times.

In 2012, a 15-year-old teenager with Crohn's disease had extensive lymphadenopathies and type B lymphoma [19]. The Epstein-Barr viral load with active disease was found in our case because he was immunocompetent. It is important to say that the virus can also cause lymphoma, in healthy children.

The history may be diagnostic and suggestive cause of lymphadenopathy; thus, the physician should determine whether the lymphadenopathy is evaluated

or not. It is important to know when the patient is referred to general surgeons for diagnostic lymph node biopsy. Generally, sampling is not recommended before 2 weeks. In cases of treatment failure after 2 weeks or persistent size after 4 weeks in referred patients with cervical lymphadenopathy, the excisional biopsy should be considered [1, 4, 5].

In general, EBV is at higher risk for lymphoma in individuals who have compromised immune systems, specific race and older age.

Therefore, although the manifestations of viruses are often very benign and self-limited in childhood, the unusual manifestations in each child should be considered in approach to lymphadenopathy. Early diagnosis because of the mortality reduction and better prognosis is very important [7, 20].

In conclusion, early diagnosis of lymphoma in our immunocompetent patient was very noticeable, because EBV might be malignant in immunocompromised persons. Atypical presentation should be considered for every child and biopsy is inevitable in larger and persistent lymphadenopathy after 2 weeks. Because of poor prognosis and high mortality rate, early detection of lymphoma is very important.

## Acknowledgment:

The author would like to thank the Clinical Research Development Committee of Amirkola Children's Hospital, Non-communicable Pediatric Diseases Research Center (NCPDRC) and Mrs. Sajedeh Hajipour working in NCPDRC for editing and contributing to this study.

**Funding:** None.

**Conflict of interest:** There was no conflict of interest.

## References:

1. Jenson HB, Epstein bar virus In: Kliegman RM, Stanton BMD, Geme JS, et al. Nelson textbook of pediatrics. 20<sup>th</sup> ed. Philadelphia: Elsevier Health Sciences 2015: 1586-90.
2. Maeda E, Akahane M, Kiryu S, et al. Spectrum of Epstein-Barr virus-related diseases: a pictorial review. Japan J radiol 2009; 27(1): 4-19.
3. Friedmann AM. Evaluation and management of lymphadenopathy in children. Pediatr Review 2008; 29(2): 53.

4. Gaddey HL, Riegel AM. Unexplained lymphadenopathy: evaluation and differential diagnosis. *American Family Physician* 2016; 94(11): 896-903.
5. Niedzielska G, Kotowski M, Niedzielski A, et al. Cervical lymphadenopathy in children- incidence and diagnostic management. *Inter J Pediatr Otorhinolaryngol* 2007; 71(1): 51-6.
6. Diepstra A, Niens M, Vellenga E, et al. Association with HLA class I in Epstein-Barr-virus-positive and with HLA class III in Epstein-Barr-virus-negative Hodgkin's lymphoma. *Lancet* 2005; 365(9478): 2216-24.
7. Zareifar S, Kazemi B, Arzanian M, Bandehpour M. Detection of Epstein-Barr virus in pediatric lymphoma: A single center study. *J Leuk* 2016; 4(3): doi:10.4172/2329-6917.1000213.
8. Ansell SM. Hodgkin lymphoma: 2016 update on diagnosis, risk-stratification, and management. *American J Hematol* 2016; 91(4): 434-42.
9. Kapatai G, Murray P. Contribution of the Epstein-Barr virus to the molecular pathogenesis of Hodgkin lymphoma. *J Clin Pathol* 2007; 60(12): 1342-9.
10. Moore S, Schneider J, Schaaf H. Diagnostic aspects of cervical lymphadenopathy in children in the developing world: a study of 1,877 surgical specimens. *Pediatr Surg Inter* 2003; 19(4): 240-4.
11. Higgins CD, Swerdlow AJ, Macsween KF, et al. A study of risk factors for acquisition of Epstein-Barr virus and its subtypes. *J Infect Dis* 2007; 195(4): 474-82.
12. Bolis V, Karadedos C, Chiotis I, et al. Atypical manifestations of Epstein-Barr virus in children: a diagnostic challenge. *J Pediatr* 2016; 92(2): 113-21.
13. Hjalgrim H, Rostgaard K, Johnson PC, et al. HLA-A alleles and infectious mononucleosis suggest a critical role for cytotoxic T-cell response in EBV-related Hodgkin lymphoma. *Proceed National Acad Sci* 2010; 107(14): 6400-5.
14. Urayama KY, Jarrett RF, Hjalgrim H, et al. Genome-wide association study of classical Hodgkin lymphoma and Epstein-Barr virus status-defined subgroups. *J National Cancer Instit* 2012; 104(3): 240-53.
15. Epskamp C, de Man P, Libourel E. Epstein-Barr virus mimicking lymphoma- A case report. *Netherlands J Med* 2015; 73(9): 432-4.
16. Akkoc G, Kadayifci EK, Karaaslan A, et al. Epstein-Barr virus encephalitis in an immunocompetent child: a case report and management of Epstein-Barr virus encephalitis. *Case Report Infect Dis* 2016; <http://dx.doi.org/10.1155/2016/7549252>.
17. Son SM, Choi M, Kim WS, Ko YH. Case report multifocal lymphadenopathy due to cytomegalovirus and Epstein-Barr virus infection in lymphoma patients receiving chemotherapy: a report of two cases. *Int J Clin Exp Pathol* 2016; 9(8): 8745-9.
18. Ambinder RF. Epstein-barr virus and hodgkin lymphoma. *ASH Education Program Book*. 2007; 2007(1):204-9.
19. Altaf S, Atreaga GM, Joshi AY, Rodriguez V. Diffuse large B-cell lymphoma in an adolescent female presenting with Epstein-Barr virus-driven hemophagocytic lymphohistiocytosis: a case report. *J Med Case Report* 2012; 6(1): 141.
20. Alexander F, Jarrett R, Lawrence D, et al. Risk factors for Hodgkin's disease by Epstein-Barr virus (EBV) status: prior infection by EBV and other agents. *British J cancer* 2000; 82(5): 1117.