

Echocardiographic findings in children with osteogenesis imperfecta

Original Article

Mohammad Reza Alaei (MD) ¹

Asieh Mosallanejad (MD) ^{2*}

Shahrazad Fallah (MD) ³

Marjan Shakiba (MD) ⁴

Hedeyeh Saneifard (MD) ⁴

Fariba alaei (MD) ⁵

Reza Shiari (MD) ⁵

Behnam Sobouti (MD) ⁶

1. Department of Endocrinology and Metabolism, Mofid Children Hospital, Shahid Beheshti University of Medical Sciences, Tehran, Iran, [ORCID ID](https://orcid.org/0000-0002-9920-9431) orcid.org/0000-0002-9920-9431
2. Shahid Beheshti University of Medical Sciences, Tehran, Iran, [ORCID ID](https://orcid.org/0000-0001-7926-8218) orcid.org/0000-0001-7926-8218
3. Department of immunology and allergy, Shahid Beheshti University of Medical Sciences, Tehran, Iran
4. Department of Endocrinology and Metabolism, Mofid Children Hospital, Shahid Beheshti University of Medical Sciences, Tehran, Iran
5. Shahid Beheshti University of Medical Sciences, Tehran, Iran
6. Iran University of Medical Sciences, Tehran, Iran

* Correspondence:

Asieh Mosallanejad. MD, Shahid Beheshti University of Medical Sciences, Tehran, 16177-63141, Iran.

E-mail: mosalladr@sbmu.ac.ir

Tel: +98 2177569991

Fax: +98 2177569991

Received: 3 Dec 2018

Revised: 25 Jan 2019

Accepted: 20 Feb 2019

Abstract

Background: Osteogenesis imperfecta (OI) is a group of genetic disorders characterized by significant variation, which is due to qualitative or quantitative defects in the production of collagen. The prevalence of cardiovascular abnormalities in OI patients is unknown. This study aimed at investigating cardiac involvement in OI children using Echocardiography.

Methods: This cross-sectional research was performed on 65 patients diagnosed with OI in a children's hospital in Tehran, Iran, from 2011 to 2012. The classification of OI was based on the Sillence criteria. A consultation with a skilled pediatric cardiologist was scheduled for the subjects, and echocardiography was carried out, using the Samsung HS70 ultrasonography machine (Medison Co., Seoul; South Korea). Data analysis was done using SPSS-22, chi-square and t-tests. The exact P-values were determined and P-values <0.05 were regarded significant.

Results: Sixty percent of patients were male and 40% were female, with an average age of 6.95 ± 4.36 years (ranged from 2 months to 17 years), respectively. Based on the Sillence classification, 20% of the cases were categorized in subtype I, 47.7% in subtype III, and 32.3% in subtype IV. The prevalence of aortic root dilatation, mitral valve prolapse (MVP), mitral regurgitation (MR) and tricuspid regurgitation (TR) were 13.8%, 15.38%, 7.6% and 15.38%, respectively. The MVP and female gender showed a significant relationship, whereas there was no relationship between MVP and patients' subgroups.

Conclusions: Due to the significance of cardiac involvement in OI, echocardiography is recommended for all children with OI.

Keywords: Child, Echocardiography, Osteogenesis Imperfecta

Citation:

Alaei MR, Mosallanejad A, Fallah S, et al. Echocardiographic findings in children with osteogenesis imperfecta. *Caspian J Pediatr* March 2019; 5(1): 329-33.

Introduction

Osteogenesis imperfecta (OI) or "brittle bone disease" is an inherited disease of bone fragility and bone fractures in addition to extra skeletal involvement like musculoskeletal complication, ocular and dental problems, and early hearing loss ^[1-5]. OI is associated with dentinogenesis imperfecta, blue sclera, short stature and sensory neural deafness ^[2, 3]. Proximal muscle weakness, laxity of joints and dental malocclusion are common, as well ^[4, 6]. In 1979, Sillence et al. developed a classification of OI subtypes considering clinical characteristics and OI severity, in which OI type I is mild and common with blue sclera, OI type II is lethal, OI type III is severe and progressive and OI type IV has a moderate severity ^[7]. Defects in collagen type I synthesis or collagen structure lead to OI ^[8]. Collagen type I is one of the most important parts of the bone and other organs such as heart; therefore, a reduction in the amount of

collagen I or changes in its biosynthesis may affect the function or structure of heart in patients with OI [9].

In recent years, the cardiovascular abnormality in OI patients has been more considered; however, there are a few numbers of studies on pediatric population [10,11].

This study aimed at investigating cardiac involvement in OI children.

Methods

The present cross-sectional research was conducted in the Pediatric Endocrinology Clinics of Mofid Children Hospital in a one-year period (2011-2012). Inclusion criterion was Iranian children aged 1 month to 18 years with bone fragility disorder. Totally 70 patients with a history of multiple fractures with minimal trauma were entered into the current study. The patients' history was taken and physical examinations were performed by one endocrine pediatrician. Patients with endocrine disorders or mineral abnormality were excluded from the present study. After excluding other causes of fractures, the diagnosis was made based on clinical manifestations and physical examinations. A total of 65 cases were diagnosed with OI and classified into 3 subtypes according to the Sillence et al.'s classification [7].

Informed consent was obtained from one of their parents, and then demographic information including gender, age, weight, height, the time of first fracture and the number of fractures was collected. The body surface was calculated using the weight/height² formula.

Cardiac examination was performed echocardiographically by an expert pediatric cardiologist using the Samsung HS70 ultrasonography machine (Medison Co., Seoul; South Korea). Transthoracic two-dimensional, M-mode and Doppler-derived echocardiography was done based on the American Society of Echocardiography guidelines [12].

Patients were placed in the left lateral decubitus position, while resting. Images were obtained using standard subcostal four-chamber, apical four-chamber, parasternal long axis and short axis, and suprasternal long-axis views.

All structural and valvular abnormalities were evaluated. Mitral regurgitation (MR) was considered pathologic after observing in at least 2 views with jet velocity of more than 2 cm, peak Doppler velocity of greater than 3m/s and pansystolic jet in at least 1 envelope based on the American Heart Association criteria [13]. The aortic root diameter was measured and

compared with normal values for body surface area [14]. All data were recorded on prepared forms. Data were analyzed using SPSS 22, chi-square and t-test. The exact P-values were calculated whenever needed, and the significance level was considered 0.05.

Results

This study was conducted on 65 patients with OI, of whom 60 and 40% were male were female with the average age of 6.95 ± 4.36 years (ranged, from 2 months to 17 years), respectively. According to the Sillence et al.'s classification [13], 20% of the patients belonged to subtype I, (31) 47.7% to subtype III and (21) 32.3% to subtype IV.

In echocardiography, the mean of aorta root diameter was $11.38 \text{ mm} \pm 4.57$ (ranged from 6 to 30 mm). The mean of aorta root diameter according to the body surface area was $1.55 \pm 0.61 \text{ cm/m}^2$ (ranged from 0.71 to 4.2 cm/m^2).

The Z score for aorta root showed that 13.8% of the patients had Z score >2 , while 19.3% of them with subtype III were suffered from aortic root dilatation (Z score >2). Aortic root dilatation was mild and was slightly more in males (44.4% of the patients were girls and 55.5% were boys).

The prevalence of tricuspid regurgitation (TR) was 16% and 15.8% in boys and girls, respectively. The TR was mild, and no statistically significant difference was found between males and females. No significant difference was found between various subtypes of disease ($p=0.437$).

Only one patient had a history of cardiac surgery due to the ventricular septal defect (VSD). Aortic insufficiency (AI), pulmonary insufficiency (PI), mitral stenosis (MS) and aortic stenosis were not found in our patients.

Of 65 studied children with OI, five cases (7.69%) had MR.

Mitral valve prolapse (MVP) was observed in 10 patients (15.38%): 7 girls (26.9%) and 3 boys (7.6%). ($p=0.039$).

There was no significant difference between various subtypes of disease ($p=0.275$).

Overall, the prevalence of valvular abnormalities (TR, MR, and MVP) in OI patients was 30.7%. Nine girls and 11 boys had a valvular abnormality, and the prevalence of valvular abnormality was not statistically significant between boys and girls ($p=0.583$; Figure 1).

The prevalence of valvular abnormalities in various subtypes of OI indicated no statistically significant difference ($p=0.197$).

The mean thickness of the LV posterior wall was significantly different between patients with and

without valvular disorders (MVP and MR) ($p=0.015$), but there was no significant difference between these two groups in aorta diameter and septal thickness ($p=0.879$ and $p=0.499$, respectively) (Table 1).

Table 1- The left ventricular (LV) posterior wall thickness, interventricular septum (IVS), and aortic diameter according to the valvular heart disorders

Variable	Valvular heart disorders		P value
	No (n=50)	Yes (n=15)	
	mean±SD	mean±SD	
LV posterior wall thickness	7.16±1.10	8.16±1.81	0.015
Aortic diameter	1.56±0.68	1.54±0.46	0.879
Interventricular septum	7.67±1.81	7.98±2.07	0.499

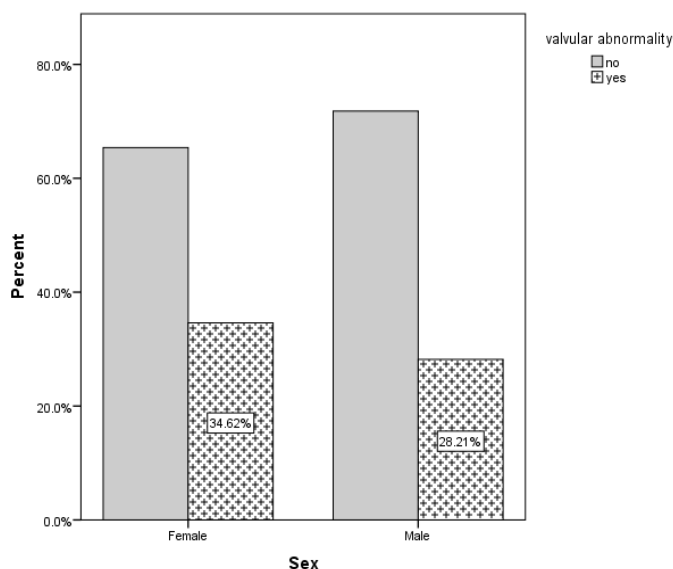


Figure1- The prevalence of valvular abnormality, according to sex

Discussion

The most common echocardiography findings in our patients were aortic root dilatation and MVP. Ashournia et al. reviewed 68 studies and compared the prevalence of cardiac involvement in OI patients. Based on their results, the OI patients were found with a high risk of heart anomaly, according to the biological plausibility [9] and these patients had an elevated chance of heart valvular disorders. Compared with other connective tissue disorders, like Marfan syndrome, the cardiovascular involvement in OI is less common [15, 16]. However, the prevalence of cardiovascular abnormalities in OI has not yet well understood [11]. We reported echocardiographic findings of 65 patients with OI classified into 3 subtypes according to the Silience et al.'s classification [7]. Increased aortic root diameter is the most common

heart anomaly in OI patients [16, 17, 18, 9]. In Hortop et al.'s study, the prevalence of aortic dilatation was 12.1%, which was mild and had no relationship with the patient's age [1]. Aortic root dilatation was identified in 28% of the patients with OI subtype III in a survey done by Vetter et al [10]. Among our patients, the prevalence of aortic root dilatation in cases with OI and subtype III was 13.8% and 19.3%, respectively. These values were calculated based on the Z score >2 . In different studies, a Z score >2 has been considered as the dilatation of aortic root [11]. Similar to other surveys, the mild aortic root dilatation was found in our studied cases.

Collagen type I plays a critical role in the myocardium structure [19, 11]. It is not surprising that the patients with connective tissue disorders (Marfan and

Ehlers-Danlos syndromes and OI) have an increased risk of cardiovascular problems [20].

Valvular dysfunction is more prominent on the left side of the heart [21-24]. Although AI and MR are the most common valvular impairments as noted in most surveys [21, 23, 25], some studies have reported different results. For example, Bonilla et al. found that there was no significant difference between OI patients and control group in valvular disorders [19].

In the study of Karamifar et al, the TR was the most common valvular pathology followed by AI [11]. Like their study, the most common valvular pathology was TR in our samples, as well. In our study, 15.38 and 7.6% of the patients had mild TR and MR, respectively. In contrast to other studies, the AI was not found in our patients. The mean age of our cases was significantly lower than other studies. Moreover, perhaps, the AI is a phenomenon that progresses with aging.

The prevalence of MVP in our subjects was 15.38%, which was significantly higher in girls (p-value=0.039). The MVP impairment has reported differently in different populations; for example, it has reported 4.5% in Ilam (Iran) and more common in women [26]. Sattur et al. studied the prevalence of MVP in healthy teenagers aged 13 to 19 years and found that it was less than 1%. The MVP rate was significantly higher in female teenagers than male ones [27].

The frequency of MVP in our cases was higher than in other relevant studies, which can be due to a higher prevalence of MVP in the Iranian population [26], or because of a higher prevalence of MVP in patients with OI.

Although the most common cardiac manifestations reported in OI are aortic root dilatation and valvular impairment, other anomalies, including aortic dissection, the involvement of the right side of the heart, atrial rupture, MVP, and myocardial involvement have also been reported [6, 11, 18, 22]. Congenital heart disease is not more prevalent in OI patients than normal population [1, 19]. In a study by Vetter et al., four out of 58 patients had the congenital cardiac disease [10, 23]. Karamifar et al. observed a patient with both patent foramen oval (PFO) and patent ductus arteriosus (PDA) and a patient with PFO in 24 cases with OI [11]. Some clinical reports of congenital cardiovascular defects like ventricular aneurysm, VSD and Ebstein's anomaly have been presented [20, 28-30]. In the current study, only one patient had a history of neonatal cardiac surgery due to the VSD. Similar to other

studies, the ongoing study found no a significant frequency of congenital heart disease.

In conclusion, According to the obtained results, though children with OI are not at higher risk for a significant valvular abnormality and aortic root dilatation, more studies are needed to confirm this observation. It can be considered that these patients have an increased risk of developing cardiovascular disease; therefore, echocardiographic evaluation is recommended in follow-up programs for these patients.

Limitations of the study: Although the results were examined, calculated carefully and corrected based on body surface area and Z score, the lack of a control group was a limitation.

Acknowledgement

The authors are grateful to the patients and their families for their collaboration in this study and also thank the Clinical Research Development Unit at the Imam Hossein Medical Center for data analysis.

Funding: This study was self-funded.

Ethical approval: The study was approved by the Ethics Committee of Shahid Beheshti University of Medical Sciences (No. 1399.02.02-0308.872).

Conflict of Interest: The authors declare no conflict of interest.

References

1. Hortop J, Tsipouras P, Hanley JA, et al. Cardiovascular involvement in osteogenesis imperfecta. *Circulation* 1986; 73(1): 54-61.
2. Migliaccio S, Barbaro G, Fornari R, et al. Impairment of diastolic function in adult patients affected by osteogenesis imperfecta clinically asymptomatic for cardiac disease: casualty or causality? *Inter J Cardiol* 2009; 131(2): 200-3.
3. Takken T, Terlingen HC, Helders PJ, et al. Cardiopulmonary fitness and muscle strength in patients with osteogenesis imperfecta type I. *J Pediatr* 2004; 145(6): 813-8.
4. Primorac D, Rowe DW, Mottes M, et al. Osteogenesis imperfecta at the beginning of bone and joint decade. *Croatian Med J* 2001; 42(4): 393-415.
5. Arponen H, Waltimo-Sirén J, Valta H, Mäkitie O. Fatigue and disturbances of sleep in patients with osteogenesis imperfecta—a cross-sectional questionnaire study. *BMC Musculoskeletal Disord* 2018; 19(1): 3.

6. Huber MA. Osteogenesis imperfecta. *Oral Surg Oral Med Oral pathol Oral radiol Endod* 2007; 103: 314-20.
7. Sillence D, Senn A, Danks D. Genetic heterogeneity in osteogenesis imperfecta. *J Med Genet* 1979; 16(2): 101-16.
8. Sam JE, Dharmalingam M. Osteogenesis imperfecta. *Indian J Endocrinol Metabolism* 2017; 21(6): 903.
9. Ashournia H, Johansen FT, Folkestad L, et al. Heart disease in patients with osteogenesis imperfecta- a systematic review. *International J Cardiol* 2015; 196: 149-57.
10. Vetter U, Maierhofer B, Müller M, et al. Osteogenesis imperfecta in childhood: cardiac and renal manifestations. *European J Pediatr* 1989; 149(3): 184-7.
11. Ilkhanipoor H, Karamifar H, Ajami G, et al. Cardiovascular Involvement in Children with Osteogenesis Imperfecta. *Iran J Pediatr* 2013; 23(5): 513-8.
12. Gottdiener JS, Bednarz J, Devereux R, et al. American Society of Echocardiography recommendations for use of echocardiography in clinical trials: a report from the American society of echocardiography's guidelines and standards committee and the task force on echocardiography in clinical trials. *J American Society Echocardiograph* 2004; 17(10): 1086-119.
13. Gewitz MH, Baltimore RS, Tani LY, et al. Revision of the Jones Criteria for the diagnosis of acute rheumatic fever in the era of Doppler echocardiography: a scientific statement from the American Heart Association. *Circulation* 2015; 131(20): 1806-18.
14. Henry WL, Gardin J, Ware J. Echocardiographic measurements in normal subjects from infancy to old age. *Circulation* 1980; 62(5): 1054-61.
15. Pithukpakorn M, Chaowalit N. Clinical presentation and echocardiographic findings of Thai patients with marfan syndrome. *J Med Assoc Thai* 2010; 93 (1): 43-7
16. Schievink WI, Michels VV, Piegras DG. Neurovascular manifestations of heritable connective tissue disorders, A review. *Stroke* 1994; 25(4): 889-903.
17. Bonilla VJ, Saavedra JF, Alberca MV, et al. Cardiac abnormalities in osteogenesis imperfecta, Case-control echocardiographic study. *Medicina clinica* 2010; 135(15): 681-4.
18. Radunovic Z, Wekre LL, Diep LM, Steine K. Cardiovascular abnormalities in adults with osteogenesis imperfecta. *Am Heart Journal* 2011; 161(3): 523-9.
19. Ju H, Dixon I. Extracellular matrix and cardiovascular diseases. *Canadian J Cardiol* 1996; 12(12): 1259-67.
20. Rush ET, Li L, Goodwin JL, et al. Echocardiographic phenotype in osteogenesis imperfecta varies with disease severity. *Heart* 2017; 103(6): 443-8.
21. Najib MQ, Schaff HV, Ganji J, et al. Valvular heart disease in patients with osteogenesis imperfecta. *J Cardiac Surger* 2013; 28(2): 139-43.
22. Radunovic Z, Wekre LL, Steine K. Right ventricular and pulmonary arterial dimensions in adults with osteogenesis imperfecta. *Am J Cardiol* 2012; 109(12): 1807-13.
23. Wong RS, Follis FM, Shively BK, Wernly JA. Osteogenesis imperfecta and cardiovascular diseases. *Ann Thoracic Surg* 1995; 60(5): 1439-43.
24. Stein D, Kloster FE. Valvular heart disease in osteogenesis imperfecta. *Am Heart J* 1977; 94(5): 637-41.
25. Vandersteen AM, Lund AM, Ferguson DJ, et al. Four patients with Sillence type I osteogenesis imperfecta and mild bone fragility, complicated by left ventricular cardiac valvular disease and cardiac tissue fragility caused by type I collagen mutations. *Am J Med Genetics Part A* 2014; 164(2): 386-91.
26. Azami M, Kooshali MHY, Qavam R, et al. Heart Valves Prolapse in Population Referred to Heart Clinic in Ilam, West of Iran. *Crescent J Med Biol Sci* 2017; 4(3).
27. Sattur S, Bates S, Movahed MR. Prevalence of mitral valve prolapse and associated valvular regurgitations in healthy teenagers undergoing screening echocardiography. *Experiment Clin Cardiol* 2010; 15(1): e13.
28. Di Sessa TG, Howard SC, Salim MA. Congenital right ventricular diverticulum associated with a ventricular septal defect: a rare echocardiographic finding. *Echocardiography* 2006; 23(9): 787-9.
29. Taksande A, Vilhekar k. Osteogenesis imperfecta type II with congenital heart disease. *Iran J Pediatr* 2008; 18(2): 175-178.
30. D'Eufemia P, Celli M, Versacci P, Persiani P, Sangiorgi L. Ebstein's anomaly in a child with OI type I. *Clin Causes Miner Bone Metab* 2011; 8(2):50-51.