

Comparison of diagnosis of VUR nephropathy by urinary level of ceruloplasmin with DMSA-Scan in children

Original Article

Mohsen Akhavan Sepahi (MD)^{1, 4}

Mohamad Heidari (MD)²

Mohammad Reza Haeri (PhD)³

Mohammad Ghare Beghloo (MD)⁴

Abolfazl Mohammadbeigi (PhD)⁵

Zahra Movahedi (MD)^{6*}

1. Department of Pediatric Nephrology, School of Medicine, Qom University of Medical Sciences and Health Services, Qom, Iran.

2. Department of Urology, School of Medicine, Qom University of Medical Sciences and Health Services, Tehran, Iran.

3. Department of Biochemistry, School of Medicine, Qom University of Medical Sciences and Health Services, Qom, Iran.

4. Pediatric Medicine Research Center, Qom University Of Medical Sciences, Qom, Iran.

5. Research Center for Environmental Pollutants, Associate professor of Epidemiology, Faculty of Health, Qom University of Medical Sciences, Qom, Iran.

6. Department of Pediatric Infectious Disease, School of Medicine, Qom University of Medical Sciences and Health Services, Qom, Iran.

* Correspondence:

Zahra Movahedi (MD), Department of Pediatric Medicine Research Center, Qom University of Medical Sciences, Imam Blvd, Children Hospital, Qom, Iran.

E-mail: zmovahedi@muq.ac.ir

Tel: +98 2536651801

Fax: +98 2536650806

Received: 22 June 2017

Revised: 15 July 2017

Accepted: 9 Aug 2017

Abstract:

Background: Children with vesicoureteral reflux (VUR) are at risk of recurrent pyelonephritis, kidney scars, hypertension, and renal failure. Currently, VUR complications can be diagnosed by different imaging methods such as sonography, intravenous pyelography and dimercaptosuccinic acid (DMSA) scan, having certain limitations. Urinary level of ceruloplasmin (Cp) might be an effective non-radiological method. The aim of this study was to compare the urinary level of Cp with DMSA scan in the diagnosis of VUR complications.

Methods: The present cross-sectional study was conducted in Pediatric Research Center of Qom University of Medical Sciences and Health Services, Iran. Subjects consisted of 61 children with VUR, diagnosed by voiding cystoureterography (VCUG) and undergone either DMSA scan or urine Cp measurement. VUR stages and complications of the cases were evaluated using serum and urinary renal parameters. Data were analyzed using SPSS 22.

Results: Among them, 80.3% were girls with a mean age of 7.2 ± 3.8 years. Mean Cp urine level was statistically different between VUR sides in DMSA scan (unilateral: 269.56 vs. bilateral: 450.42 $\mu\text{g/dL}$) ($P=0.034$, $r=0.273$), but was not statistically different among various VUR degrees ($P=0.102$, $r=0.211$), different ages and genders ($P>0.05$).

Conclusions: Urinary level of Cp was not statistically different among VUR degrees, but was higher in bilateral VUR cases, indicating Cp can be used as a safe, non-invasive, and cheap measurement tool for screening test. Further studies are required to confirm Cp as an effective method.

Key Words: Children, Urinary tract infection, Ceruloplasmin, Sonography, Vesicoureteral reflux, DMSA

Citation:

Akhavan Sepahi M, Heidari M, Haeri MR, et al. Comparison of Diagnosis of VUR Nephropathy by Urinary Level of Ceruloplasmin with DMSA-Scan in Children. Caspian J Pediatr Sep 2017; 3(2): 234-40.

Introduction:

Vesicoureteral reflux (VUR) is defined as retrograde urine flow from the bladder into the ureter and kidney secondary to a dysfunctional vesicoureteral junction [1, 2]. VUR is the most common congenital urinary tract abnormality in children that usually presents with urinary tract infection (UTI) [2]. VUR is conventionally diagnosed and followed-up by VCUG and classified into five grades (I to V). Grade I is reflux into the ureter, grade II into the renal pelvis and calyces without any dilation of the calyces, grade III into the renal pelvis with mild dilation of the ureter, grade IV into the renal pelvis with greater dilation of the renal pelvis, and grade V into the renal pelvis with ureteral and pelvic dilation [3, 4]. Vesicoureteral reflux is associated with severe complications, especially in children older than 1 year and with higher disease grades [4]. The scars which lie more at the poles are composed preferentially of compound papillae (concave architecture) compared with the middle site of kidneys. The former are more

commonly the site of intrarenal reflux and are the prime regions of susceptibility to scarring [1, 2].

When VUR associated with intrarenal reflux, it decreases the renal function and increases UTI incidence [4, 5]. Vesicoureteral reflux may also resolve spontaneously [6], but complications may occur even after resolution of VUR, one of the most important complications is the renal scarring, also known as reflux nephropathy [6, 7]. Sterile reflux is considered benign, while VUR exploits several conditions that predispose to scarring. Most importantly, reflux provides a mechanical hydrodynamic mechanism which facilitates the ascension of bacteria from the bladder to the kidneys [3, 6].

Therefore, appropriate diagnosis of VUR is essential, not only for the initial diagnosis, but also for occurrence of complications, even in cases with resolved VUR.

Various investigations have tried to determine the diagnostic accuracy of different imaging techniques. As suggested by previous research, ultrasonography has a low sensitivity and predictive value for diagnosis of VUR [8], and renal scars [8, 9]. In addition, ultrasonography, alone or in combination with dimercaptosuccinic acid (DMSA) scan, cannot predict the complication of low grade VUR [10, 11], which has higher probability of spontaneous resolution of VUR and should be considered for occurrence of complications with greater precision [6]. Moreover, although DMSA scan is introduced as the most reliable method for diagnosis of renal scars [12], it has several limitations (it is invasive and expensive) [13]. Therefore, it is essential to find an appropriate diagnostic method for follow-up of patients with VUR.

Ceruloplasmin (Cp) is an acute phase reactant. Cp is an acute-phase glycoprotein that may increase in blood in response to infection, inflammation, some cancers and trauma and acts through interleukin-6. It is expressed in several organs, such as spleen, lung, testis, retina, and brain astrocytes, as well as glomerular parietal epithelial cells and is secreted into urine [14].

Thus, measurement of urinary levels of Cp is suggested for detection of nephropathy and micro-albuminuria in diabetic patients [15]. Increased concentration of Cp has been recently suggested as a marker of endothelial dysfunction and organ damage [16] and kidney protection against iron excess damage [17]. In addition, Cp can be used as a marker of damaged renal cells and may be increased in VUR stages and complications [16].

Due to the complications of VCUG as an invasive method, complexity and possible bias of DMSA scan,

the hypothesis of efficacy of measurement of urinary Cp levels as a simple and inexpensive laboratory method for diagnosis of VUR complications seems valuable to be further studied in children with VUR. Therefore, the aim of the current study was to compare diagnostic accuracy of urinary Cp levels with DMSA scan for VUR complications.

Materials and Methods

Study design

The present cross-sectional study was conducted in Pediatric Research Center and approved by the Ethics Committee of Qom University of Medical Sciences (code: IR.MUQ.REC.1393.121). Children referred to Nephrology Center of Hazrat-e- Masoumeh Hospital from 2015 to 2016 and diagnosed with VUR by VCUG were entered into the study. Any patient with acute urinary infection during the study period, congenital or genetic kidney diseases, and metabolic diseases was excluded from the study population. The study design and objectives were explained to the parents of the children and the written informed consent was obtained from them. All patients with proven VUR were evaluated using DMSA scan, and the urinary Cp level was measured for detecting kidney damage. We selected a group of children with VUR for the assessment of VUR complications 6 months after treatment of UTI.

A blood sample (5 cc) was collected from all participants and taken from median cubital vein of child in sitting position. After sampling, all blood samples were kept in heparinized tubes and directly sent to reference laboratory. Means of serum and urine creatinine were measured for all participants. Mean urinary Cp level was measured in 24-hour urine by Abnova the CP (Human) ELISA Kit made in Taiwan. The samples were stored at -20°C. Urinary Cp concentration on average is 1.25-320 ng/mL.

DMSA scan was performed by one radiologist via injection of 2 mCi ^{99m}Tc- DMSA. Three hours after injection, scanning was performed in multiple projections. All images were reviewed on the monitor's screen. DMSA is currently the accepted gold standard for diagnosing acute pyelonephritis and renal scarring but decreased uptake can be due to dysplasia, cyst and hydronephrosis [18]. In this study, VUR is classified into three grades: mild (Grade 1, 2), moderate (Grade 3, 4) and severe (Grade 5).

Statistical analysis

Analysis included descriptive and inferential analysis; descriptive analysis consisted of mean \pm SD

for quantitative variables and percentage of categorical variables was compared using t-test and chi-square test, respectively. The association of variables was tested by Pearson's correlation coefficient, with the help of Rock's curve. For the statistical analysis, SPSS 16 was used. P values of ≤ 0.05 were statistically considered significant.

Results:

A total of 80 children of this study, 61 patients completed the study protocol, among whom 49 (80.3%) were girls and 12 (19.7%) were boys with a mean \pm SD age of 7.2 ± 3.8 years. The results of creatinine were expressed in mg/dl. Erel's Cp measurement method was used. This method is automated, colorimetric and based on the enzymatic oxidation of ferrous ion to ferric ion. The results were declared in mg/dl, and the precision of this assay is within 3%. Mean \pm SD serum creatinine was 254.723 ± 173.61 mg/dl, and mean urinary Cp level was 352.58 ± 333.41 μ g/dl in all participants. Mean ratio of urine Cp/cr was 1.45 ± 1.14 . Mean urinary Cp level was 371.23 μ g/dl in girls and 276.41 μ g/dl in boys ($P=0.382$).

The degrees of vesicoureteral reflux and scar severity diagnosed by DSMA are shown in Table 1. Mean urinary Cp level was statistically different between uni- and bi-lateral VUR in DMSA scan and was higher in bilateral cases (269.56 μ g/dl in unilateral vs. 450.42 μ g/dl in bilateral) ($P=0.034$, Pearson coefficient: $r=0.273$). However, the mean urinary Cp level was not statistically different among VUR degrees ($P=0.102$, Pearson coefficient: $r=0.211$), or among different ages ($P=0.71$, Pearson coefficient: $r=0.233$). Mean urinary Cp was associated with age, VUR degree, and kidney scar degree, as shown in figures 1, 2, 3. Pearson's coefficient of the association of urinary Cp and scar severity in the study population is illustrated in table 2.

This manuscript in the present form just can represent the association between CP level and DMSA scan. The data do not support the CP level as a screening method. The authors only examined the CP level among patients with VUR. If the CP level was measured among healthy children (no VUR), the specificity of the test would be estimated. Otherwise, the test cannot be considered as screening test.

Table 1. The degree of vesicoureteral reflux and scar severity diagnosed by DSMA scan in the study population

DSMA scan		Frequency (%)
VUR Degree	Mild	29(47.5)
	Moderate	26(42.6)
	Severe	6(9.8)
Uni/bilateral VUR	Unilateral	33(54.1)
	Bilateral	28(45.9)
Renal Scar stage	Stage 1	23(37.7)
	Stage 2	21(34.4)
	Stage 3	14(23.0)
	Stage 4	3(4.9)

Table 2. Pearson's coefficient of the association of urinary ceruloplasmin and scar severity in the study population

DSMA scan	Pearson's coefficient (r)	P-value
Uni/bilateral	0.273	0.034
VUR Degree	0.211	0.102
Renal Scar stage	0.233	0.71

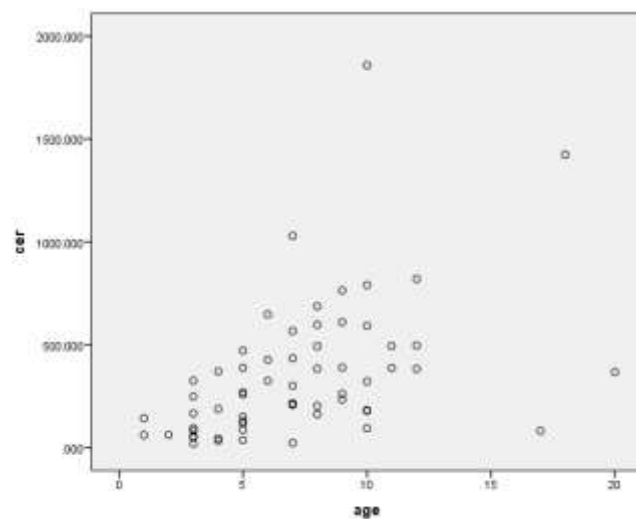


Figure 1. Mean urinary Cp in different ages in the study population

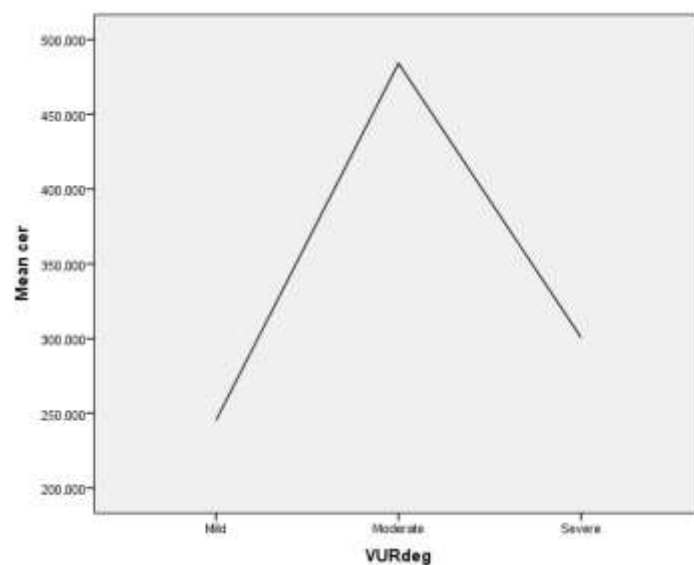


Figure 2. Mean urinary Cp in different stages of VUR in the study population

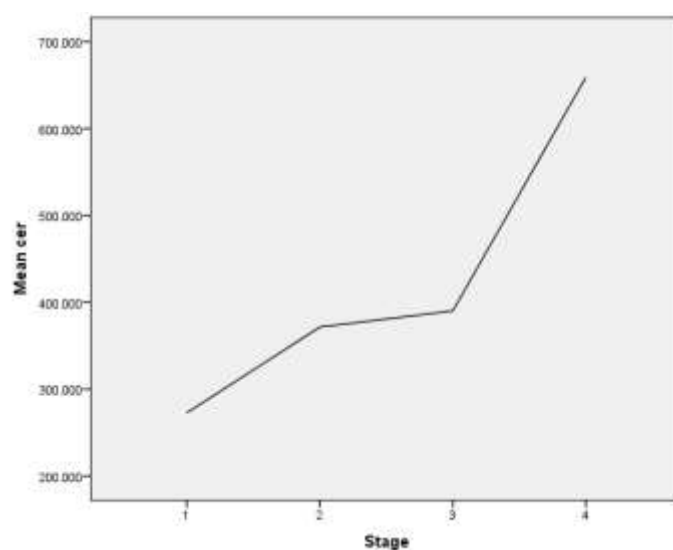


Figure 3. Mean urinary Cp in different stages of scar in the study population

Discussion:

Children with VUR, diagnosed by voiding cystoureterography (VCUG) and undergone either DMSA scan or urine Cp measurement were selected in the present study. VUR stages and complications of the cases were evaluated using serum and urinary renal parameters. In the current study, we examined the hypothesis of renal over-excretion of Cp that has been proven by higher concentration of urinary Cp in children with VUR, statistically higher in bilateral cases. Among all participants, 80.3% were girls with the mean age of 7.2 ± 3.8 years, and the mean level of urinary Cp was 352.58 ± 333.41 $\mu\text{g/dl}$, which was higher than the normal range. Mean Cp urine level was statistically different between VUR sides (unilateral: 269.56 vs. bilateral: 450.42 $\mu\text{g/dl}$) ($P=0.034$, $r=0.273$), but was not statistically different among various VUR degrees ($P=0.102$, $r=0.211$), different ages and genders ($P>0.05$). These results indicate that Cp is excreted more in renal damaged cells, but Cp cannot differentiate VUR stages.

To the best of our knowledge, urinary Cp level was measured for the first time in children with VUR in this study. As Cp is expressed in glomerular parietal epithelial cells and secreted into urine [14], and increased Cp level is also described as a marker of endothelial dysfunction and organ damage [16] previously, we hypothesized that Cp is able to be used as a marker of damaged renal cells and may be increased in VUR stages and complications. Previous studies have suggested urinary Cp increases due to nephropathy and other renal disorders, but have mainly focused on diabetic nephropathy [19]. Narita et al. have also reported increased urinary levels of Cp in diabetic patients with micro-albuminuria [20]. Cp is an anti-oxidant with specific characteristics; for instance, copper is released from Cp under acidic conditions in diabetic patients and higher Cp is filtered through damaged glomerulus [21]. The results of these studies indicated higher urinary concentrations of Cp in patients with damaged kidneys, which is in line with the results of the present study, indicating higher total mean level of urinary Cp than normal range in all participants with VUR. Although the above-mentioned studies focused on patients with diabetes type 2, the study population consisted of children with VUR.

VUR predisposes to urinary tract infection (UTI) through facilitating the transport of pathogen bacteria to the upper urinary tract, also inflammatory reaction caused by UTI can result in reflux nephropathy (RN). RN is a result of abnormal renal development, leading to focal or extended renal dysplasia [21].

As Cp is expressed in several organs such as liver, spleen, lung, testis, retina, and brain [14], researchers have investigated the association of Cp levels with different diseases of these organs and have focused on the significance of detection and prediction of diseases with Cp, hypothesized to act through nitric oxide (NO) activity [22]. Accordingly, serum levels of Cp are related to cardiovascular disorders and play an important iron-mediated injury role [23].

It is supposed to be able to assess vascular inflammation and hence predict acute coronary events [24] and metabolic syndrome in adolescents [25]. Further research has revealed the association of Cp with liver diseases like hepatic steatosis [26]. Also, Cp has been linked with brain diseases such as Alzheimer's [27], Parkinson's disease [28] and psychiatric patients with suspicion of Wilson disease (WD) should be evaluated in a reference center [29].

In one study, a renal-specific excellent novel urine biomarker panel for the recognition of active lupus nephritis (LN) was done. The levels were significantly higher in those patients with active LN than in non-LN patients [all corrected p values (pc) <0.05] across both cohorts [30].

Finally, a number of potential limitations might have affected the results of the present research. First, the considerable percentage of loss to follow-up cases resulted in the investigation of 61, instead of 80 patients. Moreover, the present study assessed children with VUR, referred to one center and the results might not be representative of the whole population. Further multicentric studies with longer follow-up and greater sample size can better illustrate the significance of this hypothesis.

According to the results of the present study, although urinary levels of Cp could not differentiate VUR degrees, its higher concentrations in total population of children with VUR as well as in bilateral than unilateral cases indicated the higher excretion of Cp from damaged renal cells, indicating the use of this simple, easy, and inexpensive laboratory method as an effective measurement tool in complications of VUR. This study can be considered as the initial step to the implementation of urinary measurement of Cp levels as a feasible and easy method, which can be confirmed by future research.

Acknowledgment:

The authors would like to thank Pediatric Research Center of Qom University of Medical Sciences for

designing and performing this study and all patients who participated in the study.

Funding: The present study was financially supported by Pediatric Research Center of Qom University of Medical Sciences.

Conflict of interest: There was no conflict of interest.

References:

1. Elder JS, Vesicoureteral Reflux. In: Elder J, Behrman RE, Kliegman RM, Jenson HB. Nelson textbook of Pediatrics. 17th Ed. Philadelphia: W.B Saunders company; 2016: 2562-4.
2. Akhavan Sepahi M, Sharifiain M, Sadr Moharrerpour S. Pediatric Vesicoureteral Reflux Approach and Management. *Caspian J Pediatr* March 2017; 3(1): 209-14.
3. Sharifian M, Mohkam S, Akhavan Sepahi M. Spontaneous resolution of vesicoureteral reflux (VUR) in Iranian children: a single center experience in 533 cases. *Nephro-Urol Mon* 2011; 3: 191-5.
4. Fukui S, Watanabe M, Yoshino K. Intrarenal reflux in primary vesicoureteral reflux. *Int J Urol* 2013; 20(6): 631-6.
5. Akhavan Sepahi M, Eftekhari SS, Rashidinia Sh, et al. The Relationship between Urinary Reflux and Nephrolithiasis in Children: A Cross-Sectional Study. *Int J Pediatr* 2017; 5(5): 4965-73. DOI: 10.22038/ijp.2017.22728.1898.
6. Schwab CW, Wu H-Y, Selman H, et al. Spontaneous resolution of vesicoureteral reflux: a 15-year perspective. *J Urol* 2002; 168(6): 2594-9.
7. Akhavan Sepahi M, Eftekhari SS, Shahmoradi S, et al. Metabolic and Anatomic Abnormalities Associated with Pediatric Nephrolithiasis: a Cross-Sectional Study. *Int J Pediatr* 2017; 5(5): 4833-38. DOI: 10.22038/ijp.2017.22705.1896.
8. Moorthy I, Wheat D, Gordon I. Ultrasonography in the evaluation of renal scarring using DMSA scan as the gold standard. *Pediatr Nephrol* 2004; 19(2): 153-6.
9. Temiz Y, Tarcan T, Onol F, et al. The efficacy of Tc99m dimercaptosuccinic acid (Tc-DMSA) scintigraphy and ultrasonography in detecting renal scars in children with primary vesicoureteral reflux (VUR). *Int Urol Nephrol* 2006; 38(1): 149-52.
10. Sorkhi H, Nooreddini HG, Amiri M, et al. Prediction of vesicoureteral reflux in children with first urinary tract infection by dimercaptosuccinic acid and ultrasonography. 2013.
11. Lee Hy, Soh BH, Hong CH, et al. The efficacy of ultrasound and dimercaptosuccinic acid scan in predicting vesicoureteral reflux in children below the age of 2 years with their first febrile urinary tract infection. *Pediatr Nephrol* 2009; 24(10): 2009-13.
12. Bhatnagar V, Mitra D, Agarwala S, et al. The role of DMSA scans in evaluation of the correlation between urinary tract infection, vesicoureteric reflux, and renal scarring. *Pediatr Surg Int* 2002; 18(2): 128-34.
13. Mantadakis E, Vouloumanou EK, Georgantzi GG, et al. Acute Tc-99m DMSA scan for identifying dilating vesicoureteral reflux in children: a meta-analysis. *Pediatr* 2011; 128 (1): e169-79.
14. Wiggins JE, Goyal M, Wharram BL, Wiggins RC. Antioxidant ceruloplasmin is expressed by glomerular parietal epithelial cells and secreted into urine in association with glomerular aging and high-calorie diet. *J American Soc Nephrol* 2006; 17(5): 1382-7.
15. Narita T, Hosoba M, Kakei M, Ito S. Increased urinary excretions of immunoglobulin g, ceruloplasmin, and transferrin predict development of microalbuminuria in patients with type 2 diabetes. *Diabetes care* 2006; 29(1): 142-4.
16. Dzugkoeva F, Mozhaeva I, Dzugkoev S, et al. Oxidative Stress and Biochemical Markers of Endothelial Dysfunction and Organ Damage under Conditions of Experimental Nonferrous Metal Intoxication. *Bulletin Experimental Biol Med* 2016; 162(2): 199-202.
17. Mattoo TK, Mathews R, Gupta IR. Vesicoureteral Reflux and Renal Scarring in Children. In: Avner ED, Harmon WE, Niaudet P, et al. *Pediatric Nephrology*. 7th Ed. Baltimore: Lippincott Williams & Wilkins; 2016: 1716-35.
18. Jiang B, Liu G, Zheng J, et al. Hephaestin and ceruloplasmin facilitate iron metabolism in the mouse kidney. *Scientific Rep* 2016; 6: 39470. DOI: 10.1038/srep39470.
19. Yamazaki M, Ito S, Usami A, et al. Urinary excretion rate of ceruloplasmin in non-insulin-dependent diabetic patients with different stages of nephropathy. *Europ J Endocrinol* 1995; 132(6): 681-7.
20. Narita T, Sasaki H, Hosoba M, et al. Parallel increase in urinary excretion rates of immunoglobulin G, ceruloplasmin, transferrin, and orosomucoid in normoalbuminuric type 2 diabetic patients. *Diabetes care* 2004; 27(5): 1176-81.
21. Ito S, Fujita H, Narita T, et al. Urinary copper excretion in type 2 diabetic patients with nephropathy. *Nephron* 2001; 88(4): 307-12.
22. Shiva S, Wang X, Ringwood LA, et al. Ceruloplasmin is a NO oxidase and nitrite synthase that determines endocrine NO homeostasis. *Nature chemical biology* 2006; 2(9): 486-93.

23. Fox PL, Mazumder B, Ehrenwald E, Mukhopadhyay CK. Ceruloplasmin and cardiovascular disease. *Free Radical Biol Med* 2000; 28(12): 1735-44.
24. Daybanyrova L, Shevchenko O. Clinical significance levels of C-reactive protein and ceruloplasmin in patients with ischemic heart disease. *Wiadomosci lekarskie* 2014; 68(4): 517-9.
25. González-Jiménez E, Schmidt-Riovalle J, Sinausfa L, et al. Predictive value of ceruloplasmin for metabolic syndrome in adolescents. *Biofactors* 2016; 42(2): 163-70.
26. France M, Soran H, Williams S, et al. Liver Fat Measured by MR Spectroscopy: Estimate of Imprecision and Relationship with Serum Glycerol, Ceruloplasmin and Non-Esterified Fatty Acids. *Int J Molecul Sci* 2016; 17(7): 1089. doi: 10.3390/ijms17071089.
27. Siotto M, Simonelli I, Pasqualetti P, et al. Association between serum ceruloplasmin specific activity and risk of Alzheimer's disease. *J Alzheimer's Dis* 2016; 50(4): 1181-9.
28. Zhao N, Jin L, Fei G, et al. Serum microRNA-133b is associated with low ceruloplasmin levels in Parkinson's disease. *Parkinsonism Relat Dis* 2014; 20(11): 1177-80.
29. Demily C, Parant F, Cheillan D, et al. Screening of Wilson's disease in a psychiatric population: difficulties and pitfalls. A preliminary study. *General Psychiatr* 2017; 16: 19. DOI: 10.1186/s12991-017-0142-6.
30. Smith EMD, Jorgensen AL, Midgley A, et al. International validation of a urinary biomarker panel for identification of active lupus nephritis in children. *Pediatr Nephrol* 2017; 32(2): 283-95.