

A Late Presentation of Neonatal Axial Hypotonia due to Craniovertebral Anomaly

Harsha Neelam¹ , Rakesh Kotha^{1*} , Alimelu Madireddy¹ 

1. Department of Neonatology, Niloufer Hospital, Hyderabad, India.

*Corresponding Author: Dr. Rakesh Kotha;

Address: Niloufer Hospital, Hyderabad, Telangana -500004, India

Tel.: +91 7207261715 Fax: +91 4023394265, E-mail: dr.rakeshkotha@gmail.com

Article Info.

Article type:
Case Report

Received: 21 April 2024

Revised: 29 Aug. 2024

Accepted: 8 Sep. 2024

Published: 8 Sep. 2024

Keywords:

Craniovertebral Anomalies,
Hypotonia,
Neonate,
Neuroimaging

ABSTRACT

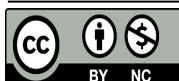
Background and Objective: Basilar invagination and atlas assimilation are significant craniovertebral anomalies that typically present with symptoms in the 3rd and 4th decades of life. These anomalies are concerning because they are in close proximity to the vital structures surrounding the foramen magnum, including the brainstem and spinal cord. However, these conditions are rarely reported in younger populations, making early diagnosis and intervention in such cases particularly difficult.

Case Report: This report presents the case of a term neonate born to a primigravida mother by emergency lower segment cesarean section. The infant, who was initially discharged after resolution of respiratory distress, was readmitted at two weeks of age with generalized weakness. The initial management approach focused on treating the condition as late-onset sepsis and meningitis. However, after ruling out other causes for the generalized hypotonia, subsequent computed tomography (CT) of the head and spine revealed compressive myelopathy secondary to basilar invagination and atlas assimilation, as well as gross hydrocephalus. These findings emphasize the presence of a craniovertebral anomaly at an exceptionally early stage of life..

Conclusions: This study revealed the positive effect of the interventions on most of FMS variables, and the sports game group performing better. Due to the modality of the physical activity interventions, the integration of these two types of interventions may show a better effect.

Cite this Article:

Neelam H, Kotha R, Madireddy A. A Late Presentation of Neonatal Axial Hypotonia due to Craniovertebral Anomaly. *Caspian J Pediatr* March 2024; 10: e9.



Introduction

Hypoxia is one of the most common causes of central hypotonia. Typically, infants with this condition exhibit a reduced level of activity, as the hypoxia primarily impacts the cortical regions [1]. Hypoxia is one of the most common causes of central hypotonia. Typically, infants with this condition have a reduced level of activity, as hypoxia primarily affects the cortical regions [1]. The occipital condyles, the atlas (C1) and the axial vertebrae (C2) together with their joints form the craniovertebral junction (CVJ). Any process that causes a malformation of these structures can lead to an anomaly of the CVJ. Anomalies of the CVJ can be congenital, such as Down's syndrome and mucopolysaccharidoses, developmental, or due to a malformation resulting from an acquired disease process [2]. These abnormalities can lead to compression of the cranial nerves, compression of the vertebral artery and obstructive hydrocephalus. There are many causes of neonatal hypotonia. These include diseases of the central nervous system like hypoxic-ischemic encephalopathy and congenital brain malformations, genetic and metabolic diseases such as Prader-Willi syndrome and Down syndrome, diseases of the spinal cord and peripheral nerves like spinal muscular atrophy, diseases of the neuromuscular junctions, muscle disorders, and systemic diseases like sepsis and hypothyroidism. In this case, we present a craniovertebral anomaly that was overlooked on prenatal scans and initial examinations.

Case Report

A male neonate was delivered by a primigravida in a non-consanguineous marriage at 39 weeks of gestation by emergency lower segmental cesarean section (LSCS) and managed with meconium-stained liquor at a level II hospital. The baby cried immediately after birth and required no resuscitation. The antenatal history was remarkable, with normal 1st and 2nd trimester scans. Targeted imaging for fetal anomalies (TIFFA) was reported as normal. The perception of fetal movements was not diminished. The baby was admitted to the neonatal unit of Niloufer Hospital, Hyderabad, India

in July 2023 due to respiratory distress. The possibility of meconium aspiration syndrome was considered. Gradually, the respiratory distress subsided and the baby was discharged on the 5th day of life. On discharge, the baby was active, hemodynamically stable and breastfed immediately. On the 14th day of life, a baby was brought to our hospital complaining of dull activity and a weak cry (Figure 1). The weight on admission was 3.6 kg and the birth weight was 3.5 kg. The possibility of late-onset sepsis was considered. The baby was not dysmorphic and had no convulsions. On examination, the baby had decreased tone, more axially affected than appendicular tone and absent reflexes. The dorsal curvature of the truncal tone was more severe, indicating central nervous system involvement. Both the active tone and passive tone were reduced in all four limbs and neck. Moro's reflex could not be effectively triggered. The knee reflex was present in both legs; other reflexes could not be elicited. No fasciculations were present in the tongue. All cranial nerves were normal. The sensory system is also normal. Initial sepsis screen was positive (CRP positive, WBC- 25600 cells/mm³). Blood gas levels were normal. Besides, the neurosonogram was normal. Lumbar puncture was suggestive of meningitis (hazy appearance, cells: 100 cells/mm³, lymphocytes: 40%, neutrophils: 60%). The baby was treated with empirical antibiotics and continued to be fed via an orogastric tube feeding. The blood culture and the culture of cerebrospinal fluid (CSF) were negative.

Follow-up course

The baby's ability to perceive, respond to and interact with his environment improved over the following three days with spontaneous opening and normal eye movements, but he remained hypotonic with insignificant spontaneous limb movements, a delay in respiratory effort, and blood gas levels showing mild CO₂ retention, so non-invasive ventilation was required.

The possibility of complicated meningitis was considered and a contrast-enhanced computed tomography (CECT) scan of the head was performed, indicating moderate hydrocephalus with meningitis. The CSF was proved to be sterile and

was also negative when analyzed by the cartridge-based nucleic acid amplification test (CBNAAT). The Mantoux test was negative. The coagulation profile was normal. A comprehensive workup was performed to determine possible causes of the infant's hypotonia. The possibility of misdiagnosis, such as spinal muscular atrophy or congenital myopathy, was considered. Serum creatine kinase-MB (CK-MB) levels were in the normal range (33.5 U/L). The infant had no fasciculations, and there was no history of polyhydramnios. Electrolyte levels were in the normal range (K⁺ 4.8 mmol/L, Ca²⁺ 8.9 mg/dL). Thyroid function tests were also normal. Both tone and strength were decreased in all limbs, ruling out benign hypotonia, although the presence of a normal grasp reflex suggested an intact lower lumbar plexus. The infant had not taken any sedative medications such as phenobarbital, and there was no documented history of honey ingestion. Over the next 5 days, the baby's sensorium continued to deteriorate, associated with increasing head size. The baby continued to be mechanically ventilated (Figure 2). A CECT of the

head and spine was performed. The CECT of the head and spine revealed communicating hydrocephalus (Figure 3) (gross dilatation of the bilateral lateral ventricles, 3rd and 4th ventricles), with assimilation or capitalization of the atlas with basilar invagination (Figure 4) affecting the cervical spinal canal (m/s 3mm in diameter) at the corticomedullary junction.

As revealed by neuroimaging, the sensory deterioration can be attributed to the large communicating hydrocephalus. The initial hypotonia was attributed to a spinal shock period with compressive myelopathy caused by basilar invagination with occipitalization or assimilation of the atlas. The onset at this early age could be triggered by meningitis or impaired blood flow.

A neurosurgical consultation was performed and the baby underwent surgery for hydrocephalus with the right medium-pressure ventriculoperitoneal (MPVP) shunt, after which the sensorium temporarily improved. Finally baby was discharged after 10 days of post operative care

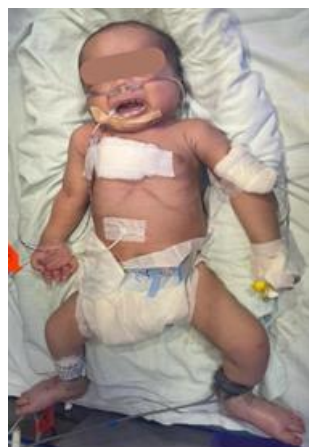


Fig 1. Baby at the time of admission (14th day of life)

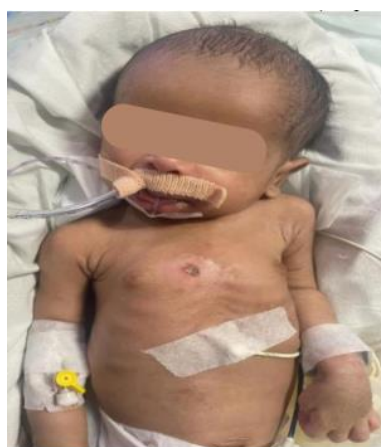

Fig 2. Baby on the 19th day of life ventilated due to deterioration of sensory function

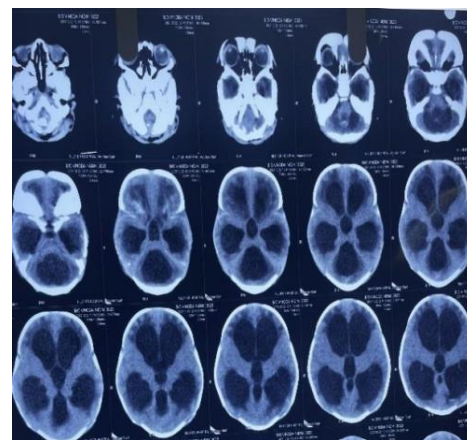


Fig 3. Contrast-enhanced computed tomography showing gross hydrocephalus

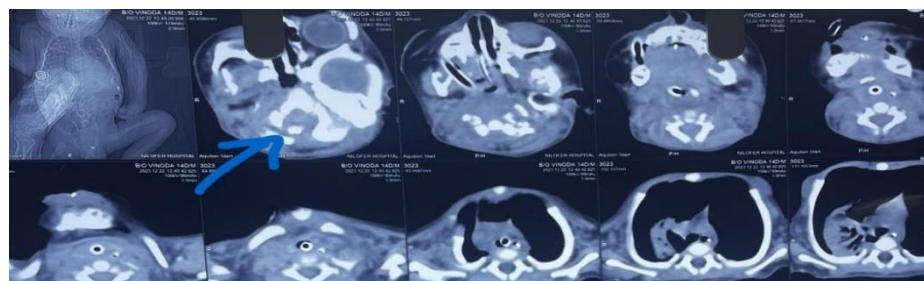


Fig 4. Contrast-enhanced computed tomography of the head and spine indicating capitalization of the atlas with basilar invagination

Discussion

In this case report, a baby presented with generalized weakness, and the CT of the head and spine revealed the presence of assimilation of the atlas with basilar invagination with gross hydrocephalus.

To clarify, basilar invagination is an anomaly at the craniovertebral junction [3]. It can be either congenital or degenerative. The odontoid process of the axis (cervical vertebra C2) protrudes into the limited space of the foramen magnum [3] (Fig. 4). Assimilation of the atlas is also referred to as occipitalization, which can be a partial or complete congenital fusion between the atlas (cervical vertebra C1) and occiput [4].

In a study of craniovertebral anomalies in young people, basilar invagination was found to be the most common (52.3%), followed by atlanto-occipital assimilation (33.3%), with an overall incidence of occipitalization of only 0.08–3% [5]. Commonly documented associations with basilar invagination include Chiari malformation, syringomyelia and Klippel Feil deformity. In our case, no such association was documented in the neuroimaging. Although there is no obvious dysmorphism, an exome sequencing analysis was performed to exclude a genetic cause of Klippel-Feil syndrome in our baby, which revealed no significant mutation. In addition, this was the first case reported in cretins in whom thyroid function tests were performed and found to be normal.

The present case emphasizes the asymptomatic nature of congenital cervical spine anomalies, which typically manifest in the third or fourth decade of life or incidentally by radiography. We looked for other causes of generalized weakness and ruled them out. Therefore, meningitis complicated by hydrocephalus precipitated by basilar invagination with occipitalization and compressive myelopathy explained the baby's course and was thus reported as an early symptomatic presentation of the same. Two cases of abnormal symptoms of the cervical spine in childhood, known as multilevel cervical disconnection syndrome (MCDS), have been reported [6]. These cases were distinguished from basilar intussusception, occipital intussusception and Klippel deficiency by the presence of multilevel

cervical spondylolysis, sagittal deformity and spinal cord compression. Both cases were diagnosed based on clinical symptoms of spinal cord compression in infants. Another such case was also reported in the neonatal period as a case of encephalopathy [7]. Magnetic resonance imaging (MRI) is required to confirm this disease, which could not be performed in our baby. However, the CT scan performed on this baby showed that the rest of the spine was normal.

A wide range of manifestations have been observed in basilar invagination, many of which are specific to the syndrome with which it may be associated, such as Chiari malformation, as this constricts both the foramen magnum and the medulla oblongata [8]. This may obstruct CSF flow, leading to syringomyelia and hydrocephalus, as in our case, in which the sensorium rapidly deteriorates. Additionally, the occipitocervical junction is of great clinical importance due to the proximity of structures such as the vertebral artery and the first cervical nerve, which, if compressed, can impair blood flow to the brain and cause neurological side effects [9]. Atlanto-occipital fusion decreases the foramen magnum dimension, similar to basilar invagination, resulting in muscle weakness, ataxia, and muscle atrophy due to compression of the spinal cord or brainstem. In this way, the generalized weakness of this child can be clarified.

In terms of management, there are various approaches, both for the assimilation of the atlas with or without basilar invagination. Patients who report minimal symptoms or become symptomatic as a result of minor trauma, extensive travel or vigorous activity can be treated non-surgically [9]. If neurological symptoms develop, surgical decompression may be required. In a study of 190 surgically treated cases of basilar invagination [10], treatment was mainly determined by the absence or presence of Chiari malformation. It turned out that transoral surgery for cervical traction was the best option for those without Chiari malformation. Only this group showed clinical and radiologic improvement after traction, indicating that traction helped to pull the odontoid process away from the brainstem. Surgical treatment of basilar

invagination in the presence of Chiari malformation is not well defined. In our patient, a ventricular shunt was primarily applied to relieve the pressure symptoms, which led to a temporary improvement. A definitive operation could not be performed on our baby. However, early diagnosis and awareness of this condition could have led us to better treatment options. This is the limitation of this case report even though we have a large census. A complete and detailed neurological examination is required for every neurological case.

Postoperative extubation failed, and the baby remained on a ventilator for 28 days. A definitive operation could not be performed. The parents subsequently opted for palliative treatment.

Conclusions

In developing countries where sepsis is common, it will overshadow rare diseases, although advanced antenatal scans may miss some congenital anomalies. Investigations cannot replace clinical examination.

Acknowledgments

None.

Funding

There was no financial support for this research.

Ethical considerations

This study was approved by the Ethics Committee of Osmania Medical College University of Medical Sciences (Ethical code: EC/RR/2024/301).

Conflicts of Interest

The authors have declared no conflicts of interest.

Authors' Contributions

All authors contributed equally to the preparation of all parts of the study.

References

1. Sparks SE. Neonatal hypotonia. *Clin Perinatol* 2015; 42(2): 363-71.
2. Pang D, Thompson DN. Embryology and bony malformations of the craniovertebral junction. *Childs Nerv Syst* 2011; 27(4): 523-64.
3. Donnally III CJ, Munakomi S, Varacallo M. *Basilar Invagination*. 1st ed Treasure Island (FL): StatPearls Publishing. 2024.
4. Hensinger RN. Congenital anomalies of the cervical spine. *Clin Orthop* 1991; 264: 16-38.
5. Ravikanth R, Majumdar P. Embryological considerations and evaluation of congenital anomalies of craniovertebral junction: A single-center experience. *Tzu Chi Med J* 2021; 33(2): 175-80.
6. Klimo P Jr, Anderson RC, Brockmeyer DL. Multilevel cervical disconnection syndrome: initial description, embryogenesis, and management. Report of two cases. *J Neurosurg* 2006; 104(3): 181-7.
7. Brady KM, Blau JA, Serras SJ, Neuman JT, Sidlow R. Another Case of Multilevel Cervical Disconnection Syndrome Presenting as Neonatal Encephalopathy. *Case Rep Neurol Med* 2018; 2018(1): 7908753.
8. Piplani S, Kullar JS. Occipitalization of Atlas: A Case Report with its Ontogenic Basis and Review of Literature. *AMEIs Curr Trends Diagn Treat* 2017; 1(1): 34-7.
9. Electricwala AJ, Harsule A, Chavan V, Electricwala JT. Complete Atlantooccipital Assimilation with Basilar Invagination and Atlantoaxial Subluxation Treated Non-Surgically: A Case Report. *Cureus* 2017; 9(6): 1327.
10. Goel A, Bhatjiwale M, Desai K. Basilar invagination: a study based on 190 surgically treated patients. *J Neurosurg* 1998; 88(6): 962-8.