





Severe Bradycardia caused by Octreotide in an Adolescent: A Case Report

Jagadishkumar Kalenahalli ^{1*} , Prajwala Hassan Vasudev ¹ , Manjunath Vadambal Gopalakrishna ¹ ,
Nandish Huchhavanahalli Rudrappa ¹ 

1. Jss Medical College, Jss Academy of Higher Education and Research, Mysore, India.

*Corresponding Author: Dr. Jagadishkumar Kalenahalli;

Address: Professor of Pediatrics, JSS Medical College, JSSHER, Mysore, India. Pin 570004.

Tel.: +91 9844281859,

Fax: +91 08212335556

E-mail: jagdishmandya@gmail.com,

kjagadishkumar@jssuni.edu.in

Article Info.

Article type:

Case Report

Received: 14 Feb. 2023

Revised: 3 April 2023

Accepted: 1 May 2023

Published: 16 Aug. 2023

Keywords:

Bleeding,

Child,

Infusion,

Octreotide,

Severe Bradycardia

ABSTRACT

Background and Objective: Octreotide is a somatostatin analogue used to control upper gastrointestinal (GI) bleeding. Adverse effects observed include hyperglycemia, growth hormone deficiency, hypertension, Q-T interval prolongation, and ventricular fibrillation. In rare cases, mild bradycardia has been reported.

Case Report: A 16-year-old boy was admitted with shock due to hematemesis and melena a bleeding duodenal ulcer. He was treated with an intravenous venous octreotide infusion at a dose of 1 microgram/kg/hour, and bleeding was controlled with coagulation forceps and adrenaline injection. Because of rebleeding, octreotide was increased to 2 micrograms/kg/hour because of bleeding again. After 24 hours, he developed severe bradycardia (pulse rate (PR) 45/minute). His PR increased to 66/minute by 12 hours after octreotide was discontinued.

Conclusion: Octreotide can cause significant cardiovascular side effects. Bradycardia and cardiac conduction blocks may affect the hemodynamics of a child with acute GI bleeding.

Cite this Article:

Kalenahalli JK, Vasudev PH, Gopalakrishna MV, Rudrappa NH. Severe Bradycardia caused by Octreotide in an Adolescent: A Case Report. *Caspian J Pediatr* March 2023; 9: e12.

Introduction

In children and adolescents causes of upper gastrointestinal bleeding (UGIB) include erosive esophagitis, esophageal varices, gastritis, peptic ulcer disease, coagulation disorders, dieulafoy lesions (angiodysplasia), and caustic ingestions [1]. Throughout the world, the mortality rate for UGIB in children can range from 5% to 15% [1]. Initial treatment of UGIB is the stabilization of the general condition which should precede any instrumental investigation (usually endoscopy). The pharmacological treatment of UGIB includes 3 classes of drugs: acid suppression drugs (proton pump inhibitors), vasoactive drugs (terlipressin, somatostatin, and octreotide), and non-selective β -blockers (propranolol, nadolol, and carvedilol) [1]. Octreotide is an analog of somatostatin. It acts on the somatostatin receptors, which couple to phospholipase C via inhibitory G proteins, and causes vascular smooth muscle contraction [2]. It selectively causes splanchnic vasoconstriction and decreases portal blood flow, thereby indirectly decreasing variceal blood flow [1]. In children, intravenously octreotide is effective in decreasing acute gastrointestinal (GI) bleeding in children at dosages of 2-5 mcg/kg per hour administered by continuous infusion [1]. GI side effects are common which include diarrhea, nausea, abdominal discomfort, and gallbladder abnormalities. Other side effects are hypoglycemia, hyperglycemia, itching, headache, and dizziness [2]. Octreotide is used to control UGIB and has been used in many GI disorders [3]. Al-Hussaini observed significant adverse effects in 4 out of 21 children who were treated with Octreotide. They are hyperglycemia, growth hormone deficiency, hypertension, Q-T interval prolongation, and ventricular fibrillation [3]. Infrequently, mild bradycardia has been reported after octreotide administration [4]. Herewith we are reporting an adolescent boy who presented with shock due to a bleeding ulcer in the duodenum posterior wall. He was treated with octreotide infusion and endoscopy revealed an ulcer oozing with the visible vessel, the oozing ulcer was managed with adrenaline 5 ml injection, and the vessel ulcer base was coagulated by using coagulation grasper, which achieved hemostasis

(Forrest 1 b duodenal ulcer). He developed severe bradycardia during octreotide infusion (pulse Rate 45/minute) and the pulse rate increased to 66/minute after stopping the octreotide.

Case Report

A 16-year-old boy presented with hematemesis and melena for one day referred to the district hospital. There was no history of drug ingestion/fever/jaundice. His past medical history and birth history were unremarkable. There was no significant family history. His weight and height were 32.5 kgs and 155 cms (both are less than 3rd centile according to the CDC growth chart), respectively. He was managed there with IV DNS 80 ml/hour, InjOndansetron 4 mg, Inj pantoprazole 30 mg, and Inj Vitamin K 5 mg. After 2 hours, he had one episode of a large amount of melena and developed shock. He was given 3 boluses of 10 ml/kg of NS given, 350 ml of PCV transfusion and referred to our hospital.

When he was admitted to our hospital about 6 hours after the onset of symptoms, the child was in shock. His vital signs were: temperature 99°F, RR 20/minute, pulse rate(PR) 152/minute, low volume with cold peripheries, CFT more than 4 seconds and blood pressure (BP) only systolic 60 mm recordable. The child's shock was managed with two pints of PCV (packed cell volume), 1 FFP (fresh frozen plasma) and a noradrenaline infusion (0.5 microgram/kg/minute). Intravenous octreotide infusion at a dose of 1 microgram/kg/hour was started, along with pantoprazole infusion (1mg/kg/minute). Intravenous administration of the antibiotics InjPiperacillin+Tazobactam and Injamikacin was started. The investigations are depicted in table 1. Abdominal ultrasonography, chest x ray and echocardiography were reported normal.

After 1 hour in our hospital, his vital signs were: temperature 99.4°F, RR 22/minute, PR 150/minute, low volume with cold peripheries, CFT more than 4 seconds and BP 80/30 mm of Hg. His ECHO was normal. The noradrenaline infusion was increased to 0.6 microgram/kg/minute and a dobutamine infusion was added at 10 micro/kg/minute. Endoscopy was performed 9 hours after admission

with Inj Propofol 50 mg and the patient tolerated the procedure. Endoscopy revealed a bleeding ulcer in the posterior wall of the duodenum. Inj adrenaline was injected and hemostasis was achieved.

There was no new bleeding 8 hours after endoscopy. His vital signs were: temperature 99.4°F, RR 18/minute, PR 120/minute, good volume with warm periphery, CFT less than 3 seconds and BP of 96/58 mm Hg. Octreotide and noradrenaline infusions were slowly discontinued. His vital signs were stable. After a 24-hour endoscopy, he had melena again. His vital signs were: temperature 99.6°F, RR 20/minute, PR 140/minute normal volume, CFT less than 3 seconds, and BP 90/60 mm Hg. He was restarted on octreotide 1 microgram/kg/hour and a repeat endoscopy was done under Inj Propofol 50 mg. Endoscopy revealed an oozing ulcer with a visible vessel, which was controlled with adrenaline 5 ml

injection and the vessel base of the ulcer was coagulated with coagulation forceps, achieving hemostasis (duodenal ulcer Forrest 1 b).

After 12 hours after the second endoscopy, he had a small amount of melena. His vital signs were: temperature 99°F, RR 20/minute, pulse rate 120/minute with normal volume, BP of 96/60 mm of Hg. Given the rebleeding, the octreotide infusion rate was increased to 2 micrograms/kg/hour. After a 12-hour infusion of 2 micrograms/kg/hr octreotide, his PR was 62/minute and BP was 102/64 mm Hg. Gradually, the heart rate decreased. After another 12 hours, his PR was 45/minute, regular, with good volume and BP of 110/70 mm Hg (Figure 1A). At this point, we discontinued octreotide, and his heart rate increased to 66/minute within 12 hours. After 3 days, his heart rate was 88/minute (Figure 1B). After 3 days, he was discharged with one tablet of pantoprazole 20 mg OD.

Table 1. Laboratory data of studied patient

Investigations	At admission	Day 2	Day3	Day 6
Hb(g/dl)	6.0	10	6.0	12.8
PCV	17.4	29.3	17.6	37.8
Total Counts (cells/mm3)	38950 (N80%,L16%,M4%)	31200 (N87%,L9%,M%)	15480 (N85%,L10%,M%)	13060, (N66%,L17%,M4%)
Platelets (cells/mm3)	2.13 lakhs	1.55	1.54	2.22
CRP (U/L)	1.9	-	-	-
Blood Urea (mg/dl)	53	-	35	-
Serum Creatinine (mg/dl)	0.82	-	0.73	-
Serum Sodium(mEq/l)	137	-	134	-
Serum Potassium (mEq/l)	5.8	-	3.9	-
Serum Bilirubin (mg/dl)	0.95	-	-	-
AST (U/L)	32	-	-	-
ALT(U/L)	24	-	-	-
Alkaline phosphatase (U/L)	200	-	-	-
PT (seconds)/control, INR	17/13.3, 1.35	-	-	-
APTT (seconds)/control	55/32	-	-	-
Serum Total protein (gm/dl)	3	-	-	-
Serum Albumin(gm/dl)	2.2	-	-	-
d-dimer (FEU/ml)	0.2	-	-	-

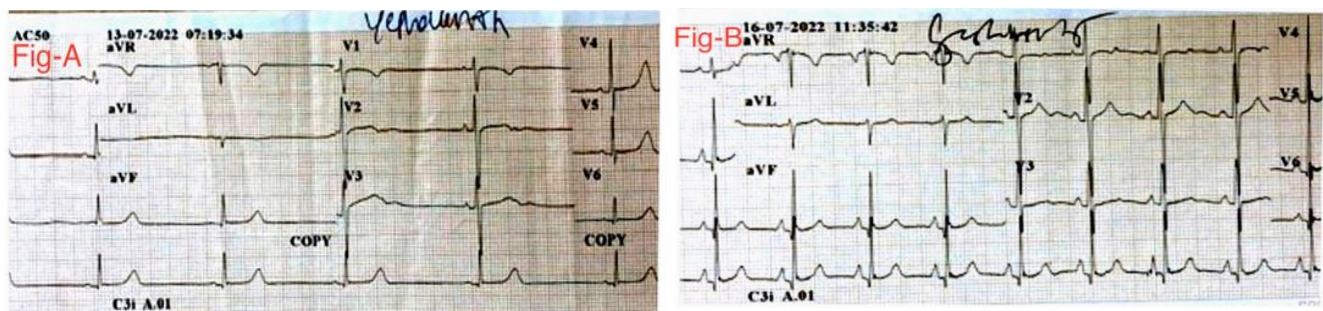


Figure 1. A: ECG indicating Bradycardia (Heart rate 45/minute), B: ECG showing Normal (Heart rate 88/minute)

Discussion

In the current case, severe bradycardia of 45/minute was observed after octreotide infusion for UGIB. Octreotide administration can lead to mild bradycardia infrequently [4]. However, Icen et al. reported a complete heart block during octreotide infusion in a 62-year-old which was reversed by a temporary pacemaker [5]. Tuncer et al. found a complete heart block at the 60th hour of octreotide infusion, which recovered six days after cessation of octreotide [4]. The present case initially had tachycardia, but he developed bradycardia after an octreotide infusion of 2 microgram/kg/hour (65 microgram/hour). The cardiovascular effect appears to occur less frequently at 50 microgram/hour and more frequently at 250 microgram/hour doses [5]. We noticed bradycardia with a low-dose infusion rate of only 60 micrograms/hour. Yuhico et al. also reported multiple asystolic events during an octreotide infusion at a relatively low dose [6]. Out of 21 children on octreotide treatment only one child had cardiovascular adverse effects [3]. An 8-year-old developed bradycardia which progressed into ventricular fibrillation on a high dose of octreotide (4 µg/kg/h). Electrocardiography revealed a prolonged corrected Q-T interval (0.46–0.48 second) (normal, <0.45 second). The patient was successfully resuscitated. During the follow-up after months of discontinuation of octreotide therapy, an electrocardiogram (ECG) showed persistent borderline Q-Tc intervals of 0.44–0.45 seconds, which raised the possibility of pre-existing congenital Q-T prolongation [3]. However, the Q-T interval was normal (0.44 seconds) in the current case. Among 34 children who received octreotide for the treatment of chemotherapy or acute graft versus host disease-induced diarrhea, common adverse effects observed were hyperglycemia, hyperbilirubinemia, nausea/vomiting, and abdominal cramping. The authors have not mentioned any cardiac side effects [7]. In a study by Testoni et al. regarding the safety of octreotide in hospitalized infants, the most common clinical adverse effect was hypotension [8]. Normal ranges of heart rate in children is depicted in the table 2 [9]. The mechanisms of bradycardia in octreotide infusion are not known. Octreotide increases

systemic vascular resistance, and bradycardia may be a reflex response of a baroreceptor to increased systemic vascular resistance caused by octreotide. It may be a direct action of octreotide also [4, 5].

Table 2. Normal ranges of heart rate in children

Age Range [Years]	Heart Rate (Beats/minute)
Neonate	85-205
0-1	100-190
1-2	100-190
2-10	60-140
10-18	60-100

Conclusion

Octreotide can cause significant cardiovascular side effects. Bradycardia may affect the hemodynamics of a child with acute GI bleeding. Cardiac side effects are usually dose-dependent. Octreotide infusion must be started at a lower dose under electrocardiographic monitoring, preferably in an intensive care unit. The treating physician must keep an eye on cardiac side effects to avoid hemodynamic instability.

Acknowledgments

The authors would like to thank the child and the parent of the patient for their participation in this study.

Ethical approval

Parents gave us written informed consent for publication. There were no ethical issues to be addressed in this case report. There was no funding source for our study.

Funding

Not Funded.

Conflict of interest

There was no conflict of interest.

References

1. Romano C, Oliva S, Martellosi S, et al. Pediatric gastrointestinal bleeding: Perspectives from the Italian Society of Pediatric Gastroenterology. *World J Gastroenterol* 2017; 23: 1328-37.

2. Debnath D, Cheriya P. Octreotide. [Updated 2022 May 8]. In: StatPearls [Internet]. Treasure Island (FL): StatPearls Publishing; 2023 Jan-. Available from: <https://www.ncbi.nlm.nih.gov/books/NBK544333/>
3. Al-Hussaini A, Butzner D. Therapeutic applications of octreotide in pediatric patients. Saudi J Gastroenterol 2012; 18: 87-94.
4. Tuncer M, Gümrükçüoğlu HA, Mete R, et al. A case of complete heart block induced by octreotide. Turk J Gastroenterol 2010; 21: 72-3.
5. Icen YK, Urgun OD, Sumbul HE, Koc M. Complete Heart Block due to Octreotide Infusion in Patient with Cryptogenic Cirrhosis. Eurasian J Med 2019; 51: 95-7.
6. Yuhico LS, Gundu V, Lenox R. Octreotide-induced asystolic events in an intensive care unit patient with gastrointestinal bleeding. Heart Lung 2012; 41: e18-20.
7. Pai V, Porter K, Ranalli M. Octreotide acetate is efficacious and safe in children for treating diarrhea due to chemotherapy but not acute graft versus host disease. Pediatr Blood Cancer 2011; 56: 45-9.
8. Testoni D, Hornik CP, Neely ML, et al. Best Pharmaceuticals for Children Act - Pediatric Trials Network Administrative Core Committee. Safety of octreotide in hospitalized infants. Early Hum Dev 2015; 91: 387-92.
9. Fleming S, Thompson M, Stevens R, et al. Normal ranges of heart rate and respiratory rate in children from birth to 18 years of age: a systematic review of observational studies. Lancet 2011; 377(9770): 1011-8.