Aspiration of a sharp metallic pin in a child: A case report

Case Report

Naeimeh Nakhjavani (MD) [*1]
Mohammadreza Esmaeilidooki (MD) [2]
Soheil Osia (MD) [3]
Abbas Hadipour(MD) [3]

1. Assistant Professor of Pediatrics, Non-Communicable Pediatric Diseases Research Center, Health Research Institute, Babol University of Medical Sciences, Babol, IR Iran.
2. Professor of Pediatric Gastroenterology, Non-Communicable Pediatric Diseases Research Center, Health Research Institute, Babol University of Medical Sciences, Babol, IR Iran.
3. Assistant professor of Pediatric Surgery, Health Research Institute, Non-Communicable Pediatric Diseases Research Center, Babol University of Medical Sciences, Babol, IR Iran.

∗ Correspondence:
Naeimeh Nakhjavani,
Non-Communicable Pediatric Diseases Research Center, No 19, Amirkola Children's Hospital, Amirkola, Babol, Mazandaran Province, 47317-41151, IR Iran.

E-mail: nakhjavanimd@gmail.com
Tel: +98 1132346963
Fax: +98 1132346963

Received: 23 April 2015
Revised: 10 May 2015
Accepted: 8 June2015

Abstract

Introduction: Foreign Body Aspiration (FBA) represents a life-threatening emergency. It occurs primarily in children below 3 years. Generally, the most common aspirated FB is organic material such as nuts or beans. Sharp Foreign Bodies (FBs) are of particular concern to the attending clinician, because of their potential to perforate the air passage and cause possible complications. Here in, we report a rare case of sharp metallic pin aspiration in a child.

Case report: A 15-month-old boy was referred to our Emergency Ward due to the sudden onset of chocking and dysphagia which were transient. His mother was a tailor. He had history of ingestion of the similar pin two months ago. Chest radiography identified the radiopaque pin in the left side of chest. Rigid bronchoscopy was done and a sharp metallic pin was removed.

Conclusions: Aspiration of a sharp, metallic FB is a serious injury. Pain X-ray can confirm the diagnosis. FB inhalation is preventable by creating public awareness and parenteral education to keep small objects out of children.

Keywords: Foreign Body, Bronchoscopy, Aspiration, Sharp Metallic Pin, Children

Citation:
Nakhjavani N, Esmaeilidooki MR, Osia S, Hadipour A. Aspiration of a sharp metallic pin in a child: A case report. Caspian J Pediatr March 2016; 2(1): 123-26.

Introduction

FB aspiration remains a common problem among young children and is commonly divided into organic and inorganic FB aspiration. Organic material such as nuts and seeds are the most commonly aspirated while the inorganic material include a wide range of objects such as plastic pieces, toy parts, beads, coins, pins and ect [1-2]. However, the nature of aspirated FB is influenced by many factors, such as age, sex, nutritional habit, geographical area and socioeconomic status [3]. Tracheobronchial aspiration is a worldwide problem which often results in life-threatening complications. It occurs primarily in children below 3 years (approximately 75%) due to the lack of adequate dentition and immaturity of swallowing [3]. On the other hand, infants and toddlers use their mouths to explore their surroundings. Classically, 3 stages of symptoms may result from aspiration of an object into the airway; initially, the patient presents with chocking, gagging, paroxysm of cough or air way obstruction. The second stage is asymptomatic interval which may cause delayed diagnosis. In this stage, the physician may minimize the possibility of FB accident. The third stage is the pictures of complication such as obstruction, infection and atelectasis [3]. Inhalation of FB in children is extremely hazardous, since the caliber of the tracheobronchial tree is small in children and the technique of bronchoscopy extraction may be variable. The problem is even more complicated in handling the unusual FBs. Sharp F.B. aspiration can be found in the literature as a case presentation [4]. In the Middle East, scarf pins aspiration in young female constitutes a community problem. These pins are 3-4 cm in length and have a pearl blind head and sharp pointed end.

[Downloaded from caspianjp.ir on 2024-10-12]
[DOI: 10.22088/acadpub.BUMS.2.1.123]

Sharp and penetrating FBs are of particular concern to the attending clinician because of their potential to perforate the air passage and cause possible complications. Plain X-Ray can confirm its diagnosis and localization [1, 3]. Here, we present a 15-month-old boy with a sharp pin tracheobronchial aspiration.

Case presentation

A 15-month-old boy was brought to emergency department of Amirkola Children's Hospital because he aspirated a sharp metallic pin 4 hours before the admission. According to the information of his mother, he had developed sudden onset of chocking, gagging and vomiting.

After a few minutes, he had dysphagia which was transient. His mother was a tailor and at that time she was sewing. He had history of ingestion of the similar pin which was passed through the stool 2 months prior to admission. On physical examination, he was mentally normal and comfortable. There was no specific finding in chest examination. He gave no history of disturbed consciousness at the time of aspiration and had no neurological predisposing factor.

Chest radiography identified the radiopaque pin in the left side (Fig1). Because, our patient had history of transient dysphagia and there was no symptom of respiratory system, we decided to do esophagoscopy under general anesthesia in the operating room while everything was ready for doing rigid bronchoscopy. No pin was observed during endoscopy.

At the same time, rigid broncoscopy (Karl Storz, Germany) was done and there was a metallic sharp pin in the left bronchus. With a suitable grasping forceps, the pointed end of the pin was dis-impacted first from the mucosa and bended slightly then it was kept protected within tube and the whole system was withdrawn as a unit.

The size of metallic pin was 4cm in length and had a pearl head (Fig2). Chest X-Ray was normal after broncoscopy. He was observed for 24hrs in pediatric intensive care unit (PICU). The patient was discharged without any complication. After one week follow up, he was well and had no sign and symptom of respiratory system.

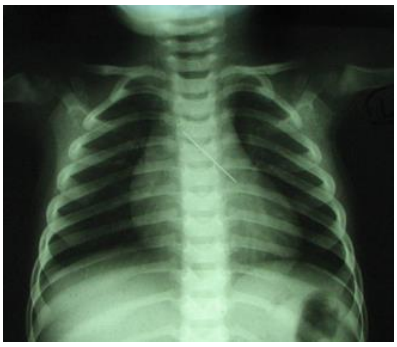

Fig 1: Chest X-Ray; the metallic pin is seen at the mid site of the chest in oblique direction to the left side

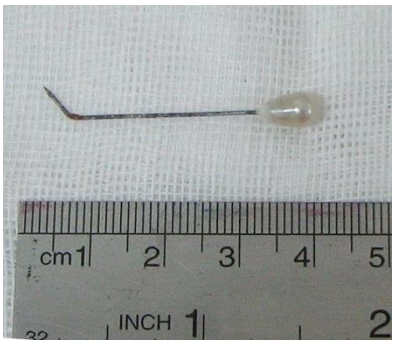

Fig 2: The size of inhaled metallic pin 4cm

Discussion

This case was a sharp metallic pin aspiration which is rare in literature due to small age [5]. FB aspiration in children is a common and serious problem which is associated which significant morbidity.The history of chocking is very important in diagnosis [3]. Chest X-Ray is the first diagnostic modality in patients with suspected FBA. It may identify either radio- opaque FB or sequels of impacted radiolucent ones, e.g. hyperinflation, pneumonia, or atelectasis. Normal chest radiographs can be found in some cases with FBA. Owing to the metallic nature of pins, they can be identified radiologically in all cases [3].

Patient with the suspicion of FBA should undergo broncoscopy for the definitive diagnosis and extraction of FB if it presents [6]. Hongguang pan et al.'s reported 368 cases of aspirated tracheobronchial F.B in patients under the age of 3 years. They found that the majority of FBA cases were caused by organic objects. Five inorganic FB_s were also identified as a pushpin, rubber band, screw, a small stone and a plastic toy.

In addition, they found that FB_S were most frequently localized in the main bronchus (82.3%) and there was no difference between the right and a left

[Downloaded from caspianjp.ir on 2024-10-12]

[DOI: 10.22088/acadpub.BUMS.2.1.123]

side [7]. Abdel-Mohsen M. et al.'s conducted a study on a total number of 843 patients underwent broncoscopy for removal of different aspirated foreign bodies. Seventy- three patients of them had scarf pin aspiration with overall incidence of 8.66%. All patients with aspirated scarf pin were female, with age ranged from 11 to 19 years (mean 13.4±1.1 years). They had no history of disturbed consciousness at the time of aspiration and they did not have any neurological or psychological predisposing factors. The presentation was almost the same in all patients; the pin was aspirated during speaking, laughing or coughing, this was followed by an attack of chocking and paroxysm of severe cough. For religious reasons, girls begin to wear a head scarf from the beginning of puberty. The aspiration is due to a bad habit of holding pins in the mouth and not owing to the neuropsychiatric problems [3].

In our case, because the mother of the child was tailor and sharp metallic pins were available around the child, aspiration was done with the same habit. From February 2003 to April 2008, Ascediojose Rodrigues et al.'s studied on 78 children with AFB, aged 8 months to 14 years old. Thirty-nine cases were aspirated inorganic materials (metallic objects, plastic materials and stone, but there was no sharp pin aspiration in this study [6]. J.P. ludemann and K. H. Riding performed a study on seven patients ranged in age from 11 to 15 years. With aspiration of sharp, metallic bodies secondary to careless behavior. All of their patients were successfully treated by rigid broncoscopy [8].

It is usually believed that FBs are lodged preferentially in the right bronchial tree because of its more vertical disposition [5, 9]. But some recent authors have suggested that the left bronchia may be the one primarily affected by FBs [7]. In our case also it was happened at the left bronchus. Traditionally, rigid broncoscopy has been the procedure of choice for removing of tracheobronchial FB in small children or when the FB is large enough to obstruct a main airway [1- 2, 6, 8].

Tracheostomy is occasionally necessary to remove large FBs form young children. Aspiration of shape metallic pin is a serious injury in patient who is treated in the best form by rigid broncoscopy. There injuries potentially could be prevented through education. [9- 11] Chevalier Jackson noted that the fundamental cause of pins entering the tracheobronchial tree is "carelessness on the behalf of adults in putting pins in the mouth and in children is their imitation of the elders as the bad pattern" and this is still true story today. [8]

Therefore, we recommended health education to the mothers who are sewing, to keep pins out of reach of the children and to avoid the bad habit of placing the pin in their mouth.

Acknowledgment

The author would like to thank the Clinical Research Development Committee of Amirkola Children's Hospital, the Research Council, Non communicable Pediatric Diseases Research Center (NCPDRC) and Health Research Center Babol University of Medical Sciences for their support and cooperation with study and grateful to Miss Fatemeh Hosseinzadeh, Mrs. Sajedeh Hajipour and Faeze Aghajanpour who are the personnel of NCPDRC for editing the manuscript and personnel of emergency and PICU wards of Amirkola children's Hospital for their cooperation.

Funding: This study was self-funded.

Conflict of interest: There was no conflict of interest.

References

1. Al-Sarraf N, Jamal-Eddine H, Khaja F, Ayed AK. Headscarf pin tracheobronchial aspiration: a distinct clinical entity. Interactive cardiovascular and thoracic surgery. 2009;9(2):187-90.
2. Gencer M, Ceylan E, Koksal N. Extraction of pins from the airway with flexible bronchoscopy. Respiration. 2007;74(6):674-9.
3. Hamad A-MM, Elmistekawy EM, Ragab SM. Headscarf pin, a sharp foreign body aspiration with particular clinical characteristics. European Archives of Oto-Rhino-Laryngology. 2010;267 (12): 1957-62.
4. Yen P, Tsai M, Huang T. Retrieval of a pin from the airway: a case report. Changgeng yi xue za zhi/Changgeng ji nian yi yuan= Chang Gung medical journal/Chang Gung Memorial Hospital. 1995;18(3):275-9.
5. Ragab A, Ebied OM, Zalat S. Scarf pins sharp metallic tracheobronchial foreign bodies: presentation and management. International journal of pediatric otorhinolaryngology. 2007;71(5):769-73.
6. Rodrigues AJ, Scussiatto EA, Jacomelli M, et al. Bronchoscopic techniques for removal of foreign bodies in children's airways. Pediatric pulmonology. 2012;47(1):59-62.

[Downloaded from caspianjp.ir on 2024-10-12]

[DOI: 10.22088/acadpub.BUMS.2.1.123]

7. Pan H, Lu Y, Shi L, et al. Similarities and differences in aspirated tracheobronchial foreign bodies in patients under the age of 3years. International journal of pediatric otorhino-laryngology. 2012;76(6):911-4.
8. Ludemann J, Riding K. Choking on pins, needles and a blowdart: aspiration of sharp, metallic foreign bodies secondary to careless behavior in seven adolescents. International journal of pediatric otorhinolaryngology. 2007;71(2):307-10.
9. Tariq P. Foreign body aspiration in children-a persistent problem. Journal-Pakistan Medical Association. 1999;49:33-5.
10. Ezer SS, Oguzkurt P, Ince E, et al. Foreign body aspiration in children: analysis of diagnostic criteria and accurate time for bronchoscopy. Pediatric emergency care. 2011;27(8):723-6.
11. Murthy P, Ingle V, George E, et al. Sharp foreign bodies in the tracheobronchial tree. American journal of otolaryngology. 2001;22(2):154-6.

[Downloaded from caspianjp.ir on 2024-10-12]

[DOI: 10.22088/acadpub.BUMS.2.1.123]