

# Arterial tortuosity syndrome—A case report from Iran

## Case Report

Hassan Zamani (MD)<sup>1</sup>  
Mohammad Goodarzi (MD)<sup>2</sup>  
Kazem Babazadeh (MD)<sup>\*1</sup>  
Mohaddese Mirzapour (MD)<sup>3</sup>

1. Non-Communicable Pediatric Diseases Research Center, Babol University of Medical Sciences, Babol, IR Iran.
2. Gorgan University of Medical sciences, Gorgan, IR Iran.
3. Faculty of Traditional Iranian Medicine, Babol University of Medical Sciences, Babol, IR Iran.

### \* Correspondence:

**Kazem Babazadeh,**  
Non-Communicable Pediatric Diseases Research Center, No 19, Amirkola Children's Hospital, Amirkola, Babol, Mazandaran Province, 47317-41151, IR Iran.

**E-mail:** kbabazadeh@hotmail.com

**Tel:** +98 1132346963

**Fax:** +98 1132346963

**Received:** 25 Jan 2014

**Revised:** 6 March 2014

**Accepted:** 16 April 2014

## Abstract

**Introduction:** Arterial tortuosity syndrome (ATS), an autosomal recessive rare connective tissue disorder characterized by tortuosity, elongation and stenosis in the large and medium sized arteries. Its manifestations include vascular and nonvascular connective tissue related symptoms. In this literature we describe the first cases of ATS from Iran.

**Case report:** A six-months-old female was presented with a heart murmur in the right upper sternal edge that was followed up for diaphragmatic hernia repair. Positive signs include right axis deviation in electrocardiography (ECG), abnormal long and tortuous aortic arch with tortuosity of its branches in angiography, increased right ventricular pressure up to 60 mmHg and slight right ventricular hypertrophy with severe stenosis of pulmonary artery bifurcation.

**Conclusions:** ATS does not present with a unique set of clinical features and its manifestations depend on the mutation type. The most common presentation is tortuous artery and more report of this rare case can help to better diagnosis of ATS.

**Keywords:** Arterial Tortuosity Syndrome, Diaphragmatic Hernia, Axis Deviation

## Citation:

Zamani H, Goodarzi M, Babazadeh K, Mirzapour M. Arterial tortuosity syndrome—A case report from Iran. *Caspian J Pediatr* March 2015; 1(1): 28-30.

## Introduction

Arterial tortuosity syndrome (ATS) is an autosomal recessive rare connective tissue disorder characterized by tortuosity, elongation and stenosis, of large and medium sized arteries<sup>[1]</sup>. ATS is caused by mutations in SLC2A10 gene and may cause defect of collagen structure, fragmentation of the internal elastic lamina of vessel walls, defects in the extracellular matrix, twisting and lengthening of the arteries. Of course, 17 SLC2A10 mutations have been reported in some studies<sup>[2, 3]</sup>. Its manifestations include vascular and nonvascular connective tissue related symptoms like hyper extensible skin (even cutis laxa), joint laxity and hypermobility, arachnodactyly, hernia, skeletal abnormalities, pulmonary artery stenosis and pulmonary hypertension<sup>[1, 2, 4, 5]</sup>. Also ventricular hypertrophy may be seen frequently. Most patients have a large face with micrognathia<sup>[5]</sup>. The first case was described by Ertugrul, in 1967 and then many cases of this disease have been reported but the exact nature of ATS is unknown<sup>[5, 6]</sup>. We didn't find any case report of ATS from Iran in our search and the report of this rare case can help to better diagnosis of various aspects of it in our country.

## Case presentation

A six-months-old female is the firstborn from non-consanguineous unaffected parents. She was born by normal vaginal delivery and birth weight was 2800 gr. At two months old, she had hernioplasty for bilateral congenital inguinal hernia without post-surgery complications.

After 3 months, the child was admitted with recurrent episodes of vomiting and respect to history of previous hernioplasty, work up for rule out intestinal obstruction was done. Chest radiography revealed a left diaphragmatic hernia.

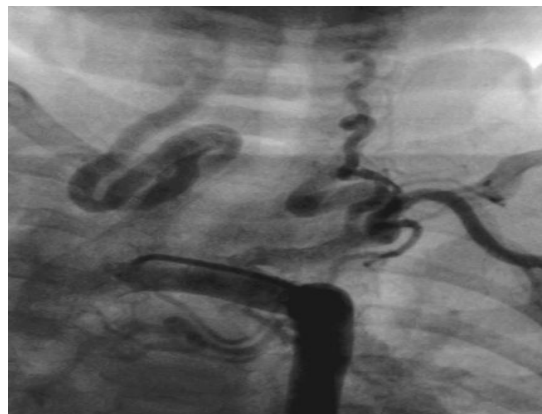After rule out the similar disease (such as eventration by Computed Tomography (CT) Scan and Ultrasonography) she underwent surgical repair. Surgery was done success-fully without any complications but in post-surgery fallow up the surgeon found a heart murmur especially in the right upper sternal edge.

Cardiovascular investigation by a pediatric cardiologist revealed the grade II/IV ejection systolic murmur in left upper sternal border especially at the pulmonary valve area. Peripheral pulse and blood pressure were normal. The size of heart and both lungs vascular shadow were normal in chest radiograph. In ECG, the axis of heart was right deviated and there weren't ventricular hypertrophy.

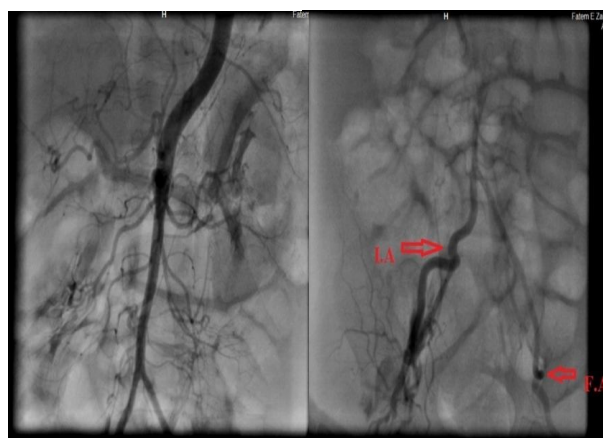
Echocardiography of child was poor view but the stenosis of pulmonary artery bifurcation and abnormally high aortic arch without narrowing were detected. Estimated Gradient of pulmonary bifurcation stenosis was 40 mmHg. Both systolic and diastolic ventricular function was normal.

CT-angiography did not show perfect image therefore angiography was done. Although different catheters sizes were tried process lasted due to difficulties in obtaining appropriate arterial and venous lines. All medium and large size arteries were tortuous that in peripheral branches of femoral and head and neck were clearer. All pressure and arterial oxygen saturation were normal and there weren't any abnormal gradient in left pathway. Left ventricular and aortic root angiography revealed an abnormal long and tortuous aortic arch with tortuosity of its branches includes brachiocephalic artery, left subclavian and carotid arteries (fig 1, 2).

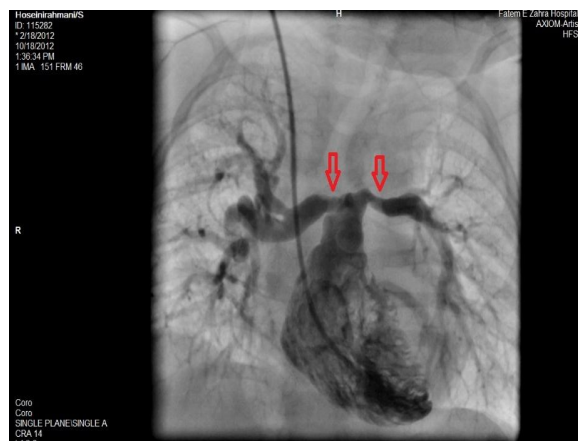Right oxygen saturation was normal but the right ventricular pressure was increased to 60 mmHg. The pressure between pulmonary trunk and it right and left branches was 40 mmHg. There was a slight right ventricular hypertrophy with severe stenosis of pulmonary artery bifurcation site (peripheral pulmonary stenosis, type II-A) (fig 3). The patient is survive after one year follow up and didn't need any intervention for her cardiac problem right now.



**Figure 1: Tortuosity in aortic arch branches (brachiocephalic and carotid)**



**Figure 2: Tortuosity of iliofemoral and abdominal aorta**



**Figure 3: Severe stenosis of pulmonary artery bifurcation site (red arrows)**

## Discussion

ATS does not present with a unique set of clinical features and it seems its manifestation is depend on the mutation type but according our literature review the most common presentation in all children is tortuous artery [2, 5, 7].

We haven't gen analysis in our case but the characteristic angiographic feature in addition to some connective tissue disorder like hernia, the ATS diagnosis seems reasonable. Previously this disease attributed to the 20q13.1 gene but recently the role of other gen are also proven [8, 9]. Some literatures emphasis on an elongated typical face micrognathia, high palate that these was notable in our case [5, 10-12]. Wessels et al.'s believe that approximately 41 percent of patient were dies in first 5 years of life but there is one case that presented in 51 years of old [5, 9] and it seems that it usually missed diagnosed within other connective tissue disorders. Callewaert et al.'s reported 16 cases of ATS in the 12 families that two case were presented with stroke (18 and 23 month years old) and in one case unrelated death occurred [13].

The treatment of disease is dependant to its problem. For example herniorrhaphy, repair of peripheral pulmonary stenosis or reduction of joint dislocation. In this presented case our manage was like this comment. Asymptomatic arterial tortuosity don't need to any intervention unless in the cases of stenosis or aneurism that need to specific intervention. We follow the patients and if the pulmonary stenoses become worsen, appropriate intervention will be done.

In conclusion ATS does not present with a unique set of clinical features and its manifestations depend on the mutation type. The most common presentation is tortuous artery and more report of this rare case can help to better diagnosis of ATS.

### Acknowledgment

We are grateful to the Clinical Research Development Committee of Amirkola Children's Hospital, Non-Communicable Pediatric Diseases Research Center of Babol University of Medical Sciences and Mrs. Faeze Aghajanpour and Fatemeh Almasi for their contribution to this study.

**Funding:** This study was self-funded.

**Conflict of interest:** There was no conflict of interest.

### References

1. Kalfa D, Gronier C, Ly M, et al. Giant aortic aneurysm in an infant with arterial tortuosity syndrome. *Ann Thorac Surg* 2012; 94(2): 51.

- Ritelli M, Drea B, Vicchio M, et al. Arterial tortuosity syndrome in two Italian paediatric patients. *Orphanet Journal of Rare Diseases* 2009; 4(20): 1-4.
- Segade F. Glucose transporter 10 and arterial tortuosity syndrome: The vitamin C connection. *FEBS Lett* 2010; 584(14): 2990-4.
- Gardella R, Zoppi N, Assanelli D, et al. Exclusion of candidate genes in a family with arterial tortuosity syndrome. *Am J Med Genet A* 2004; 30(3): 221-8.
- Wessels MW, Catsman-Berrevoets CE, Mancini GM, et al. Three new families with arterial tortuosity syndrome. *Am J Med Genet A* 2004; 131(2): 134-43.
- ERTUGRUL A. Diffuse Tortuosity and Lengthening of the Arteries. *Circulation* 1967; 36(3): 400-7.
- Loup O, Daubeney PE, Saggar A, et al. Severe arterial tortuosity in an asymptomatic infant with coarctation. *Circ Cardiovasc Imaging* 2013; 6(3): 487-90.
- Lee YC, Huang HY, Chang CJ, et al. Mitochondrial GLUT10 facilitates dehydroascorbic acid import and protects cells against oxidative stress: mechanistic insight into arterial tortuosity syndrome. *Hum Mol Genet* 2010; 19(19): 3721-33.
- Castori M, Ritelli M, Zoppi N, et al. Adult presentation of arterial tortuosity syndrome in a 51-year-old woman with a novel homozygous c.1411+1G>A mutation in the SLC2A10 gene. *Am J Med Genet A* 2012; 158A(5): 1164-9.
- Coucke PJ, Wessels MW, Van Acker P, et al. Homozygosity mapping of a gene for arterial tortuosity syndrome to chromosome 20q13. *J Med Genet* 2003; 40(10): 747-51.
- Coucke PJ, Willaert A, Wessels MW, et al. Mutations in the facilitative glucose transporter GLUT10 alter angiogenesis and cause arterial tortuosity syndrome. *Nat Genet* 2006; 38(4): 452-7.
- Faiyaz-Ul-Haque M, Zaidi SH, Wahab AA, et al. Identification of a p.Ser81Arg encoding mutation in SLC2A10 gene of arterial tortuosity syndrome patients from 10 Qatari families. *Clin Genet* 2008; 74(2): 189-93.
- Callewaert BL, Willaert A, Kerstjens-Frederikse WS, et al. Arterial tortuosity syndrome: clinical and molecular findings in 12 newly identified families. *Hum Mutat* 2008; 29(1): 150-8.