

## Foreign Body Ingestion in Children Admitted to Amirkola Children's Hospital, Iran: An 8-Year Experience

Ali Mahmoudi<sup>1</sup> , Sanaz Mehrabani<sup>2\*</sup> , Mohammadreza Esmaili Dooki<sup>2</sup> , Hoda Shirafkan<sup>3</sup> 

1. Student Research Committee, Babol University of Medical Sciences, Babol, Iran.

2. Non-Communicable Pediatric Diseases Research Center, Health Research Institute, Babol University of Medical Sciences, Babol, I.R. Iran.

3. Social Determinants of Health Research Center, Health Research Institute, Babol University of Medical Sciences, Babol, I.R. Iran

\*Corresponding Author: Dr. Sanaz Mehrabani;

Address: Non-Communicable Pediatric Diseases Research Center, No 19, Amirkola Children's Hospital, Amirkola, Babol, Mazandaran Province, 47317-41151, IR Iran.

Tel-Fax: +98 1132346963

E-mail: s.mehrabani@mubabol.ac.ir

mehrabanisanz@gmail.com

### Article Info.

### ABSTRACT

#### Article type:

Research Article

Received: 10 Dec. 2023

Revised: 18 Jan. 2024

Accepted: 14 Feb. 2024

Published: 12 March 2024

#### Keywords:

Child,

Endoscopy,

Foreign Body

**Background and Objective:** Foreign body ingestion is one of the most common problems and reasons for emergency endoscopy in children. The aim of this study was to determine the type and location of entrapped objects and endoscopic observations in children with foreign body ingestion.

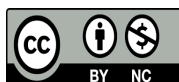
**Methods:** This cross-sectional study was conducted on all children with complaints of foreign body ingestion who underwent upper endoscopy at Amirkola Children's Hospital, north of Iran during 2014-2021. Demographic information, type of foreign body, clinical symptoms, and examinations during hospitalization, endoscopic findings, and short- and long-term outcomes were recorded. A value of  $P < 0.05$  was considered significant.

**Findings:** The mean age of 84 children in the study was  $47.98 \pm 31.51$  months and 56% of them were boys. The most commonly ingested foreign bodies were food (26.2%) and coins (25.0%). The most common location of the foreign body was the upper part of the esophagus (41.7%) and 29.7% of children were without clinical symptoms, and among those with clinical symptoms, vomiting (38.1%) was the most common symptom. The most common endoscopic findings were esophageal ulcer (11.9%). No significant relationship was found between gender and type of ingested foreign bodies ( $p = 0.528$ ).

**Conclusion:** The results of the study showed that the most common foreign bodies were food and coins and that the most common site of injury was in the esophagus, and the incidence of dangerous complications in children was low, with no deaths. Therefore, monitoring of children and providing appropriate treatment based on existing guidelines are helpful.

#### Cite this Article:

Mahmoudi A, Mehrabani S, Esmaili Dooki MR, Shirafkan Sh. Foreign Body Ingestion in Children Admitted to Amirkola Children's Hospital, Iran: An 8-Year Experience. *Caspian J Pediatr* March 2024; 10: e2.



## Introduction

Foreign body ingestion is very common in children and occurs mostly in children aged 6 months to 3 years. Of note, 80-90% of foreign bodies in the gastrointestinal (GI) tract pass spontaneously without complications, 10–20% are removed endoscopically, and 1% require open surgery (secondary to complications) [1]. Of the more than 100,000 cases of foreign body ingestion reported each year in the United States, more than 75% occurred in children younger than 5 years [2].

Fortunately, more than 90% of esophageal foreign bodies are removed spontaneously without complications. However, few can easily pass through the pylorus, stomach, duodenum, ileocecal valve, Meckel's diverticulum, and anus [3], and therefore, 10% of ingested foreign bodies may remain in the gastrointestinal tract [4, 5]. Commonly ingested foreign bodies include coins, toys, button batteries, toy parts, magnets, screws, pins, marbles, bones, and food [6-10].

Patients may be asymptomatic or present with symptoms such as dysphagia, food refusal, drooling, or respiratory symptoms such as wheezing, stridor, or choking [11]. Objects that remain in the esophagus for more than 24 hours lead to complications such as damage to the entire esophageal wall, perforation, fistula, hemorrhage, stricture, and obstruction [12].

Different studies have reported different results on the frequency and complications of foreign body ingestion, and foreign body ingestion has its own characteristics in each region [13- 17]. Therefore, considering the importance of foreign body ingestion in children and the lack of information in this field in recent years in children in this region and the existence of few studies on children in the northern part of the country, the aim of the present study was to investigate the consequences of foreign body ingestion in children referred to Amirkola Children's Hospital.

## Methods

### *Study type and samples*

The current cross-sectional study was conducted on children admitted to Amirkola Children's

Hospital in Babol, northern Iran, with complaints of foreign body ingestion during 2014-2021 who were candidates for upper endoscopy. Sampling was done by census and according to inclusion criteria. The inclusion criteria were all children aged six months to fourteen years with a complaint of a swallowing foreign body. Exclusion criteria included children with unstable vital signs, aspiration of a foreign body, and the presence of a foreign body in the nasopharynx.

### *Data collection*

All children referred to the hospital with suspected foreign body ingestion during the study period were examined by a gastroenterologist and underwent endoscopy after clinical examinations and laboratory results if further investigations were needed. All data were extracted from the patients' hospital records.

### *Endoscopy evaluation*

The foreign body was removed by pediatric gastroenterologists using a flexible esophagogastroscope from Japan and Olympus (GIF-HI70) Pentax (HI20419). Endoscopic manifestations of esophageal lesions were graded according to the criteria of the Zargar classification for corrosive injuries. Grade 0: normal mucosa, Grade 1: hyperemia and mucosal edema, Grade 2A: superficial erosions, hemorrhages, white membrane on mucosa, Grade 2B: deep and annular ulcers on mucosa, Grade 3A: necrotic areas and multiple ulcerations on mucosa, Grade 3B: extensive mucosal necrosis, Grade4: perforation. Endoscopic findings of the stomach included normal mucosa, edema and hyperemia, superficial erosions, ulcers, and necrosis [18].

The location of the foreign body lodged in the esophagus (upper/middle/lower third), stomach, and duodenum was also recorded. All children were followed up as outpatients or by telephone two weeks after the visit. In addition, cases that developed complications were examined by barium examination one month later and monitored for up to 6 months by outpatient visits and phone calls. Interventions performed during hospitalization and short- and long-term outcomes (gastrointestinal

fistula, gastrointestinal hemorrhage, esophageal stricture and rupture, ulceration or erosion in the esophagus, stomach, duodenum, and death) were recorded. The time interval between foreign body ingestion and hospitalization to endoscopy was also recorded.

After the child was admitted to the hospital, laboratory markers were measured. A test tube containing ethylenediaminetetraacetic acid (EDTA) and a Sysmex cell counter were used for complete blood cell count.

Children's plasma samples and electrolyte analyzer were used to measure sodium and potassium. An audit kit was used to measure BUN and Cr. ESR was measured with a sediment pipette (in this method, erythrocyte (RBC) is measured after one hour of sedimentation). The biochemical method and the Biorex kit were used to measure CRP. VBG measurement was performed with the Media device. All tests were performed at Amirkola Children's Hospital<sup>[19]</sup>.

The current study also evaluated demographic information (age and gender), clinical symptoms, and foreign body information. Clinical symptoms such as choking, salivation, fever, pulmonary wheezing, stridor, dysphagia, odynophagia, chest pain, neck pain, abdominal pain, nausea and vomiting, hematoma, and melena, as well as the type of object swallowed (coin/battery/jewelry/magnet/toy/food) were recorded.

### Statistical analysis

After collecting the data, they were entered into SPSS23 and analyzed with descriptive indicators such as frequency, frequency percentage, mean, and standard deviation, where  $p < 0.005$  is considered significant. The chi-square test was used to test for possible associations.

## Results

During the study period, 90 children were referred to the Children's Hospital with complaints of a foreign body, and 6 children were excluded from the study due to the exclusion criteria (including age less than 6 months, hemodynamic

instability and foreign body in the airway). Statistical analysis was performed in 84 children.

The results of the present study showed that the mean age of the patients was  $47.98 \pm 31.51$  months. Of the 84 children, 47 (56.0%) were boys and 32 (38.1%) were children.

The results of the current study indicated that the most common foreign objects swallowed by children were 21 (26.2%) food items, 25.0% coins, and 9 (10.7%) sharps. Regarding the location of the foreign body, most foreign bodies were located in the upper part of the esophagus (41.7%) and in the distal part of the intestine to the duodenum (20 (23.8%)) (Table 1). The mean time from swallowing a foreign body to endoscopy was  $48.18 \pm 105.57$  hours, and the majority of children (82.1%) underwent endoscopy less than 24 hours after swallowing a foreign body. The mean time from hospital admission to endoscopy was  $10.93 \pm 18.46$  hours, and the majority of children (95.2%) underwent endoscopy within 18 hours or less.

The most common findings observed during endoscopy and esophagoscopy in children were esophageal ulcers (11.9%), gastric ulcers (7.1%), and esophageal erythema (6.0%) (Table 2). The results of Fisher's generalized exact test represented that there was no significant relationship between gender and the type of object ingested ( $p=0.528$ ) (Figure 1).

Children were divided into 4 groups according to age (infants, toddlers, preschoolers, and elementary school children). The results of Fisher's generalized exact test demonstrated that there was a significant difference between the different age groups in the type of foreign body swallowed ( $P=0.044$ ), such that infant and elementary school-aged people most frequently complained of food sticking, and preschool-aged people most frequently complained of coin swallowing (Figure 2).

Fisher's generalized exact test revealed that swallowed food and sharps significantly caused esophageal ulceration ( $p=0.036$ ) and gastric ulceration ( $p=0.032$ ), respectively, compared to other foreign bodies. When the other complications were examined, no significant difference was found between the foreign bodies ( $p<0.05$ ).

When examining clinical symptoms in children with foreign body ingestion, 29.7% of children had no clinical symptoms. Among children with clinical symptoms, the most common symptoms were vomiting (38.1%), drooling (16.7%), nausea (15.5%), and coughing (14.3%), respectively. Symptoms such as choking, wheezing, stridor, and abdominal pain were not observed. Regarding short- and long-term outcomes, esophageal-tracheal fistula developed in only one child with disc battery swallows. Other complications such as pneumonia, esophageal stricture and rupture, obstruction, mucosal burns, vocal cord paralysis, peritonitis,

mediastinitis, and death were not observed among the children in the study.

The laboratory results of the patients illustrated that the greatest changes compared with the normal range involved WBC (41.9% higher values than normal), Hb (21.1% increased values), and PMN (12.7% decreased values) (Table 3). Fisher's generalized exact test was used to investigate the relationship between the reporting categories of the tests and the type of foreign body. The results of the present test showed that none of the foreign bodies studied caused a significant difference in the results of any of the tests tested.

**Table 1. Information about foreign body ingestion in children**

	Variables	Number (Percentage)
Type of ingested foreign bodies	Coin	21 (25.0)
	Magnet	3 (3.6)
	Food	22 (26.2)
	Disk battery	8 (9.5)
	Cylindrical battery	3 (3.6)
	Sharps**	9 (10.7)
	Other***	18 (21.4)
Location of the foreign body	Stomach	13 (15.5)
	Rectum	5 (6.0)
	Intestine distal to the duodenum	20 (23.8)
	Duodenum	1 (1.2)
	Upper esophagus	35 (41.7)
	Middle esophagus	7 (8.3)
	Lower esophagus	3 (3.6)

\* Fish blade, chicken bone, meat, date and medlar seeds, sunflower seeds, raspberries

\*\* Nail, needle

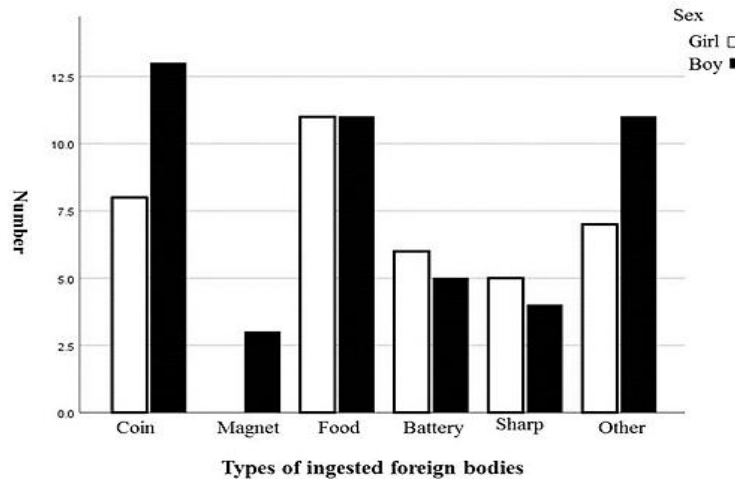
\*\*\* Marble, ring, button, toothpick, belt buckle, metal ball, doll's eye, scarf clip, key, zipper, keychain, lighter's metal head, metal bracelet, stapler, eraser, balloon piece.

**Table 2. Complications observed in patients' endoscopy and esophagoscopy**

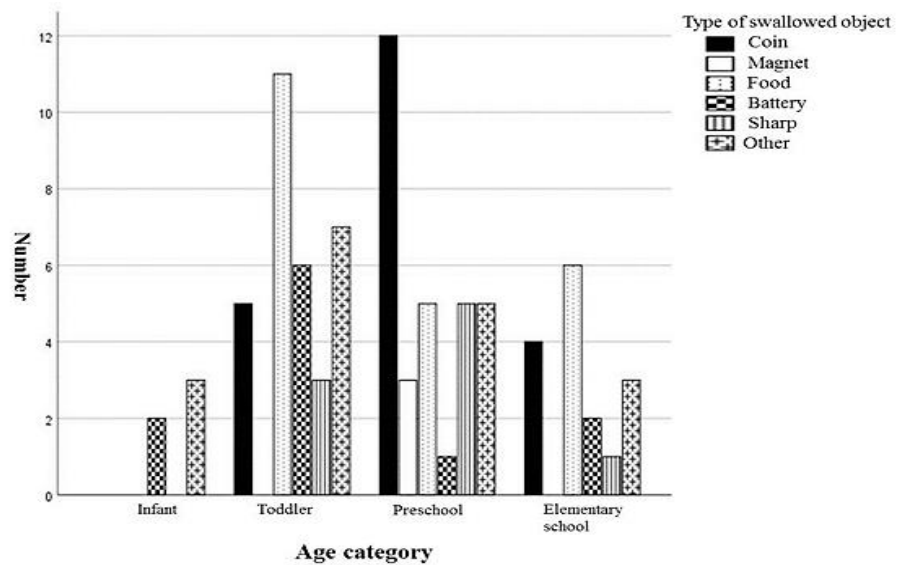
Endoscopic findings	Number (percentage)
Esophageal ulcer	10 (11.9)
Grade 1 esophagitis	2 (2.4)
Grade 2a esophagitis	1 (1.2)
Esophageal edema	1 (1.2)
Esophageal erythema	5 (6.0)
Esophageal stricture	3 (3.6)
Gastric ulcer	6 (7.1)
Stomach necrosis	1 (1.2)
Diffuse gastric nodularity	1 (1.2)

**Table 3. Laboratory parameters of children with foreign body ingestion**

Test	Number	Standard deviation ± mean	Normal number	Increased number	Decreased number
WBC	74	9991.64±3500.72	43 (58.1)	31 (41.9)	0
PLT	74	331716.2±90224.31	67 (90.5)	7 (9.5)	0
PMN	79	49.87±15.27	60 (75.9)	9 (11.4)	10(12.7)
Hb	76	11.91±1.86	60 (78.9)	16 (21.1)	0
BUN	80	12.47±4.70	77 (96.3)	2 (2.5)	1(1.3)
ESR	61	11.14±9.17	55 (90.2)	6 (9.8)	0
CRP	59	3.20±6.29	52 (88.1)	7 (11.9)	0
Na	79	136.95±2.93	79 (100)	0	0
K	79	4.28±0.37	79 (100)	0	0
Cr	80	0.56±0.10	80 (100)	0	0
Bs	66	95.78±38.05	63 (95.5)	1 (1.5)	2(3.0)
FBS	10	83.50±18.96	8 (80.0)	0	2(20.0)
pO2	2	55.00±25.45	1 (50.0)	0	1(50.0)
Saturation	3	71.06±22.33	1 (33.3)	0	2(66.7)
PCo2	3	38.53±7.22	2 (66.7)	0	1(33.3)
Hco3	3	22.06±4.30	2 (66.7)	0	1(33.3)



**Figure 1. Ingested foreign body by gender**



**Figure 2. Types of ingested foreign body by children's age**

## Discussion

Ingestion of a foreign body is one of the most common reasons for emergency consultation and one of the most important reasons for diagnostic and therapeutic endoscopy in children. However, few studies have been conducted on this topic in developing countries. The results of the present study, conducted in 84 children with foreign body ingestion, showed that the most common site of ingested foreign bodies in the study children was the esophagus and the upper third of the esophagus, followed by the stomach.

In agreement with us, Navia-Lopez et al.<sup>[13]</sup> and Khorana et al.<sup>[14]</sup> found that the esophagus was the most common site of swallowed foreign bodies. In contrast to our results, Al Lawati et al.<sup>[20]</sup> found that the most common site where a foreign body was observed was the stomach and small intestine, and only 10.9% of patients had a foreign body in the esophagus. In addition, Kim et al.<sup>[21]</sup> found that in the under 9-year-old age group, the stomach was the most common site for foreign bodies after the tonsils. The aforementioned differences might be related to the study population and the different prevalence of the type of foreign body swallowed.

The most common objects removed during endoscopy were food or coins. In addition, the prevalence of coin ingestion was highest in the preschool age group. In a study by Khorana et al.<sup>[14]</sup>, coins and food were among the most common foreign objects. In other studies, coins were cited as the most common foreign bodies swallowed by children<sup>[13, 15, 20, 22, 23]</sup>.

In contrast, in countries such as Japan, where electronic fund transfers are common, coin ingestion is less common, and substances such as plastic and cigarettes have been reported in Japanese children<sup>[17]</sup>. In the study by Jafari et al.<sup>[16]</sup>, in contrast to our findings and other studies, a disc battery was the most commonly observed foreign object, whereas food was the least common. The prevalence of food obstruction was 25% in our patients, whereas various studies reported between 4.8% and 9.2%, which is lower than our results<sup>[13, 15]</sup>. The difference in prevalence may be attributed to differences in dietary habits between regions.

In the current study, about 29.7% of patients had no clinical symptoms at the time of referral, and the most common clinical symptoms in the other patients were vomiting, drooling, nausea, and cough, respectively. Navia-Lopez et al.<sup>[13]</sup>, like us, observed that about one-third of their patients had no clinical symptoms at the time of referral, and the most common clinical symptom in the other patients was vomiting. Jafari et al.<sup>[16]</sup> in Mashhad, like us, observed that 30% of their patients had no clinical symptoms, but unlike us, they noted that the most common clinical symptom was dysphagia.

On the other hand, Speidel et al.<sup>[14]</sup>, and Fujisawa et al.<sup>[17]</sup> observed that about 50% and 60% of patients were asymptomatic, respectively, which is more than in our study, but like us, they observed that the most common clinical symptom in patients was vomiting. In contrast, the findings of the present study, Dereci et al.<sup>[24]</sup> reported dysphagia as a common clinical sign of foreign body ingestion. Diaconescu et al.<sup>[25]</sup> also found, as we did, that approximately one-third of patients were asymptomatic, but unlike us, they mentioned abdominal pain as the most frequently observed clinical symptom.

Despite the fact that the majority of children presenting with an ingested are asymptomatic, previous studies have cited certain conditions that may be risk factors for complications associated with the discovery of ingested objects in the gastrointestinal tract, including dysphagia, strictures, motility disorders, achalasia, esophagitis (including eosinophilic esophagitis), and congenital esophageal defects requiring surgical repair (eg. E.g., esophageal atresia)<sup>[26, 27, 28]</sup>.

The most common complications observed during endoscopy included esophageal ulcers, peptic ulcers, and esophageal erythema. Esophageal ulcer was significantly associated with food obstruction, and gastric ulcer was significantly associated with swallowing a pointed foreign body. In contrast to us, Jafari et al.<sup>[16]</sup> concluded that the most common complication during endoscopy was mucosal erythema. Endoscopic findings observed by Navia-Lopez et al.<sup>[13]</sup> included erosions, erythema, and ulceration in order of prevalence.

In examining the relationship between clinical symptoms and the type of foreign body, it was found that people who had swallowed sharps were more likely to be asymptomatic. Sharps are usually small, and in order to cause clinical symptoms, the mucosa must be damaged, which is justified given the small number of cases of sharps ingestion and the small number of complications caused by them. On the other hand, individuals who presented with food ingestion were more likely to vomit. This could be because the child or family tried to expel the food by vomiting, but were unsuccessful.

In addition, when examining the laboratory findings of the patients, the most common laboratory change observed was the increase in WBC, which was seen in approximately 40% of the patients. This could be related to the endoscopic findings of the patients such as ulcers and erythema, which may cause mild inflammation leading to an increase in WBCs. On the other hand, this increase may also be due to physiological differences related to age.

### *Limitations of the study*

One of the limitations of the study is the limited sample size and the cross-sectional study, which cannot prove with certainty the association between cause and disability for the study variables with certainty. On the other hand, due to the fact that the hospital studied is a single center affiliated with a university, there may be errors in patient selection.

### *Conclusion*

The findings of the present study showed that the prevalence of foreign body ingestion was higher in boys and in the age group of 1-6 years, and the most common foreign bodies swallowed were food and coins. Most patients presented without clear clinical symptoms, and the upper esophagus was the most common site of foreign body ingestion. Although the incidence rate of dangerous complications is low, it is very helpful to monitor patients and provide appropriate treatment based on existing guidelines.

### **Acknowledgments**

The authors would like to thank the Deputy of Research and Technology of Babol University of Medical Sciences for financial support and the Clinical Research Development Department of Amirkola Children's Hospital for their necessary collaboration.

### **Ethical considerations**

After approving the proposal and obtaining approval from the Ethics Committee of Babol University of Medical Sciences with the code IR.MUBABOL.HRI.REC.1400.025, the information from the patient records was entered into the checklist and kept confidential.

### **Funding**

This article is the result of the dissertation of Ali Mahmoudi, a medical student, and Research Project No. 140012234 at Babol University of Medical Sciences.

### **Conflict of interest**

There is no conflict of interest.

### **References**

1. Seo JK. Endoscopic management of gastrointestinal foreign bodies in children. *Indian J Pediatr* 1999; 66(1 Suppl): S75-80.
2. Kramer RE, Lerner DG, Lin T, et al. Management of ingested foreign bodies in children: a clinical report of the NASPGHAN Endoscopy Committee. *J Pediatr Gastroenterol Nutr* 2015; 60: 562.
3. Lee JH, Nam SH, Lee JH, et al. Spontaneous passage of gastrointestinal foreign bodies in children. *J Pediatr Gastroenterol Nutr* 2007; 10(2): 157-65.
4. Alexander W, Kadish JA, Dunbar JS. Ingested foreign bodies in children, In: Kaufmann HJ, editor. *Progress in pediatric radiology*. 2th ed. Chicago: Yearbook Medical Publishers; 1969; pp: 256-85.
5. Panieri E, Bass DH. The management of ingested foreign bodies in children-a review of 663 cases. *Eur J Emerg Med* 1995; 2(2): 83-7.
6. Waltzman ML, Baskin M, Wypij D, et al. A randomized clinical trial of the management of

- esophageal coins in children. *Pediatrics* 2005; 116(3): 614-9.
7. Athanassiadi K, Gerazounis M, Metaxas E, Kalantzi N. Management of esophageal foreign bodies: a retrospective review of 400 cases. *Eur J Cardiothorac Surg* 2002; 21(4): 653-6.
  8. Shivakumar AM, Naik AS, Prashanth KB, et al. Foreign body in upper digestive tract. *Indian J Pediatr* 2004; 71(8): 689-93.
  9. Kay M, Wyllie R. Pediatric foreign bodies and their management. *Curr Gastroenterol Rep* 2005; 7(3): 212-8.
  10. Sharieff GQ, Brousseau TJ, Bradshaw JA, Shad JA. Acute esophageal coin ingestions: is immediate removal necessary? *Pediatr Radiol* 2003; 33(12): 859-63.
  11. Denney W, Ahmad N, Dillard B, Nowicki MJ. Children will eat the strangest things: a 10-year retrospective analysis of foreign body and caustic ingestions from a single academic center. *Pediatr Emerg Care* 2012; 28(8): 731-4.
  12. Başer M, Arslantuerk H, Kisli E, et al. Primary aortoduodenal fistula due to a swallowed sewing needle: a rare cause of gastrointestinal bleeding *Ulus Travma Acil Cerrahi Derg* 2007; 13(2): 154-7.
  13. Navia-López LA, Cadena-León JF, Ignorosa-Arellano KR, et al. Foreign body ingestion and associated factors in pediatric patients at a tertiary care center. *Rev Gastroenterol Mex (Engl Ed)* 2022; 87(1): 20-8.
  14. Khorana J, Tantivit Y, Phiuphong C, et al. Foreign Body Ingestion in Pediatrics: Distribution, Management and Complications. *Medicina (Kaunas)* 2019; 55(10): 686.
  15. Speidel AJ, Wölfle L, Mayer B, Posovszky C. Increase in foreign body and harmful substance ingestion and associated complications in children: a retrospective study of 1199 cases from 2005 to 2017. *BMC Pediatr* 2020; 20(1): 1-10.
  16. Jafari SA, Khalesi M, Partovi S, et al. Ingested Foreign Bodies Removed by flexible Endoscopy in Pediatric Patients: A 10-year Retrospective Study [corrected]. *Iran J Otorhinolaryngol* 2014; 26(76): 175.
  17. Fujisawa J, Mutoh T, Kawamura K, et al. Age-specific differences in foreign bodies ingested by children: a cohort study of 252 Japanese cases. *Medicina (Kaunas)* 2020; 56(1):39.
  18. Demirören K, Kocamaz H, Doğan Y. Gastrointestinal system lesions in children due to the ingestion of alkali and acid corrosive substances. *Turk J Med Sci* 2015; 45(1): 184-90.
  19. Robert M, Kliegman MD, Geme JS. *Nelson Textbook of Pediatrics*. 21st ed. Elsevier: Amsterdam, The Netherlands. 2020; pp: e6-13.
  20. Al Lawati TT, Al Marhoobi R. Patterns and Complications of Ingested Foreign Bodies in Omani Children. *Oman Med J* 2018; 33(6): 463-7.
  21. Kim SY, Park B, Kong IG, Choi HG. Analysis of ingested foreign bodies according to age, type and location: a retrospective observational study. *Clin Otolaryngol* 2016; 41(6): 640-5.
  22. Oobudi R, Moghtaderi M, Salarian L, Agahi M. Foreign Body Ingestion and Aspiration in Iranian Children: Experience of 369 Cases in a Pediatric Unit. *Int J Pediatr* 2019; 7(6): 9567-76.
  23. Shamsi A, Valizadeh L, Rahkar Farshi M, Asghari Jafarabadi M. Frequency of predisposing factors for the entry of foreign bodies into the ear, ingestion and aspiration in children under five years in Tabriz, 2019. *Hayat* 2021; 27(2): 221-32.
  24. Dereci S, Koca T, Serdaroğlu F, Akçam M. Foreign body ingestion in children. *Turk Pediatry Ars* 2015; 50(4): 234-40.
  25. Diaconescu S, Gimiga N, Sarbu I, et al. Foreign bodies ingestion in children: experience of 61 cases in a pediatric gastroenterology unit from Romania. *Gastroenterol Res Pract* 2016; 2016: 1982567.
  26. Diniz LO, Towbin AJ. Causes of esophageal food bolus impaction in the pediatric population. *Dig Dis Sci* 2012; 57(3): 690-3.
  27. Rybojad B, Niedzielska G, Niedzielski A, et al. Esophageal foreign bodies in pediatric patients: a thirteen-year retrospective study. *Sci World J* 2012; 2012: 102642.
  28. Gatto A, Capossela L, Ferretti S, et al. Foreign Body Ingestion in Children: Epidemiological, Clinical Features and Outcome in a Third Level Emergency Department. *Children (Basel)* 2021; 8(12): 1182.