

Association between iron and zinc deficiency and retinopathy of prematurity: A Narrative Review

Seyed Ahmad Rasoulinejad (MD)¹ , Abolfazl Akbari (PhD)^{2*} 

1. Department of Ophthalmology, Ayatollah Rouhani Hospital, Babol University of Medical Sciences, Babol, Iran; rasolisa2@gmail.com.
2. Department of Physiology, School of Veterinary Medicine, Shiraz University, Shiraz, Iran; a.akbari@shirazu.ac.ir.

Article Info.

ABSTRACT

Article type:

Research Article

Received: 28 June 2021

Revised: 27 July 2021

Accepted: 15 Aug. 2021

Keywords:

Iron Deficiency,
Retinopathy of
Premature,
Zinc Deficiency

Context: Retinopathy of prematurity (ROP) is known as the abnormal growth of retinal blood vessels in premature and very low birth weight (VLBW) infants that can be caused by exposure to high oxygen pressure through oxidative damage and inflammation.

Evidence Acquisition: In this review, the keywords zinc deficiency, iron deficiency, and retinopathy of premature was first searched in databases including Scopus, Google Scholar, and PubMed. There were no time limitations for the search. Full-text articles in the English language were included in this study. Searching with these keywords did not yield any results. In the next step, preterm neonate, preterm infant and VLBW infants were added to the keywords.

Findings: The results showed that iron and zinc deficiencies are very common in premature and VLBW infants. VLBW and preterm birth are also risk factors for ROP. In addition, the use of zinc and iron supplements in low birth weight and premature infants is also commonly necessary to maintain normal growth and development.

Conclusion: It can be concluded that premature infants receiving high doses of zinc and adequate doses of iron inhibited not only inhibit oxidative damage and inflammation caused by hypoxia but also vascular endothelial growth factor (VEGF) expression. In support of this mechanism, our results showed that premature infants receiving high doses of zinc and adequate doses of iron significantly reduce the ROP process. Therefore, monitoring serum zinc and iron levels and normalizing them may play an important preventive role in the development of ROP.

Cite this article: Rasoulinejad SA, Akbari A. Association between iron and zinc deficiency and retinopathy of premature: A Narrative Review. *Caspian J Pediatr* Sep 2021; 7(2): 566-75.



© The Author(s).

Publisher: Babol University of Medical Sciences

Context

Retinopathy of prematurity (ROP) is defined as the irregular growth of retinal blood vessels in premature infants and is the leading cause of visual impairment and in some cases blindness [1, 2]. The growth and formation of new blood vessels during this period depend on the level of oxygen provided naturally or artificially [3]. ROP usually occurs between 28 and 34 weeks of pregnancy. However, in 40 to 50% of ROP patients, the babies are born before the 30th week. Moreover, almost 10% of all births worldwide occur before

*Corresponding Author: Abolfazl Akbari (PhD);

Address: Department of Physiology, School of Veterinary Medicine, Shiraz University, Shiraz, 71946-84334, IR Iran.

Tel-Fax: +98 1135302217

E-mail: a.akbari@shirazu.ac.ir

the 37th week of pregnancy, in other words, they are premature [4]. It is estimated that more than 32,000 visually impaired or blind neonates are born each year due to ROP, 10% of whom are in Latin America and the Caribbean [5]. According to Azimi et al., (2018) the prevalence of ROP in Iran is 23.5% and in premature infants, boys and girls, is 18.3% and 18.9%, respectively. The lowest prevalence of ROP was in Semnan (1.1%) and Zanjan (1.2%) provinces, while the highest prevalence was in Mazandaran (34.8%) and Khuzestan (32%) provinces [6]. In total, about 70,000 children worldwide suffer from ROP-induced blindness [7].

The main strategies of health management to reduce blindness in children due to ROP is to use appropriate screening programs based on two main risk factors, namely birth weight and gestational age [8], and provide adequate care for infants with ROP [9, 10]. Moreover, common ROP treatments are laser photocoagulation and anti-VEGF injections. The onset and development of ROP are very complex and depends on many factors, including maternal factors before pregnancy, during pregnancy and lactation, neonatal factors such as the presence of certain diseases such as respiratory distress syndrome, nutrition and factors associated with keeping a premature infant in intensive care unit include excessive oxygen exposure, hypoxia, and infections [2, 11-14]. However, short gestational age, low birth weight and duration of oxygen therapy are the most important risk factors for ROP (figure 1) [12, 15]. Maternal nutrition before pregnancy, pregnancy and lactation are other risks of ROP that have received much attention in recent years [3]. So that micronutrient deficiencies in mothers, including iron deficiency and zinc deficiency are other factors that have received special attention in the occurrence of this complication in recent years.

Studies have shown that deficiency of iron and zinc is associated with preterm delivery and premature birth [16, 17]. Moreover, several studies showed that iron deficiency and zinc deficiency is common in preterm neonates and is considered one of the pathogens of ROP [14, 18]. However, there are few etiological and pathophysiological studies regarding the role of deficiency of these elements in the incidence of ROP [19-25]. Therefore, the aim of this study was to investigate the status of iron and zinc two elements on the course of ROP (figure 1) [12, 17, 21-25].

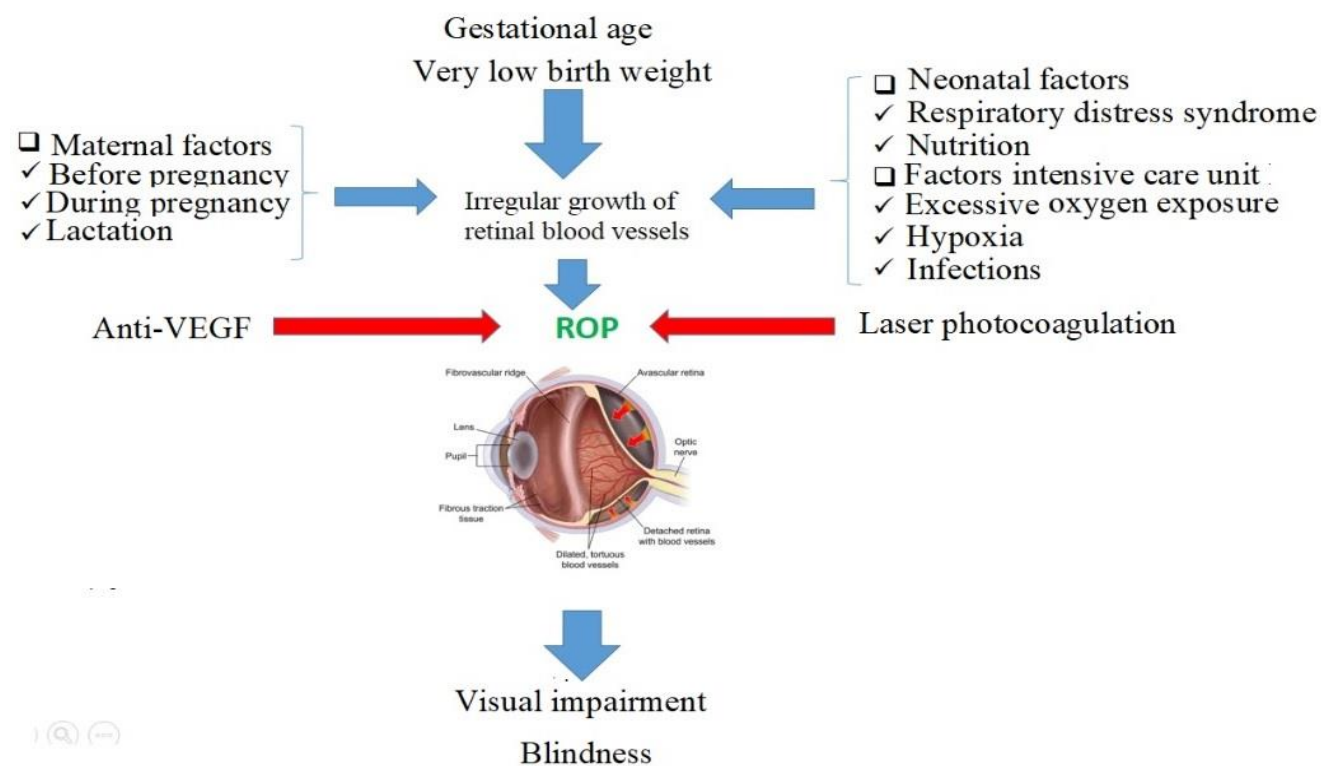


Figure 1. Risk factors for retinopathy of premature

Evidence Acquisition

In this review, the keywords zinc deficiency, iron deficiency, and retinopathy of premature was first searched in databases including Scopus, Google Scholar, and PubMed. There were no time limitations for the search. Full-text articles in the English language were included in this study. Searching with these keywords did not yield any results. In the next step, preterm neonate, preterm infant and VLBW infants were added to the keywords. Our inclusion criteria were zinc deficiency, preterm neonate, VLBW, iron deficiency, comorbid disorders, English language, original articles, and full-text articles. All identified abstracts were assessed by two reviewers.

Findings and Discussion

An initial search of the keywords of zinc deficiency, preterm neonate, VLBW, iron deficiency and retinopathy of premature found more than 463 articles. About 100 articles were selected by title evaluation. The evaluation was then performed based on access to the full text of the article and English language and 8 articles remained (table 1). The results showed that iron and zinc deficiencies are very common in premature and VLBW infants. VLBW and preterm birth are also risk factors for ROP. In addition, the use of zinc and iron supplements in low birth weight and premature infants is also commonly necessary to maintain normal growth and development.

Table 1: Studies and results related to iron and zinc deficiency and their relationship with the incidence of neonatal retinopathy

Study	Results
[20]	The prevention of morbidities, such as bronchopulmonary dysplasia, retinopathy of prematurity, and intraventricular hemorrhage.
[21]	Iron deficiency in preterm infants is positively correlated with very low birth weight and iron deficiency anemia.
[22]	zinc deficiency may have significant subclinical effects, increasing the risk of several complications typical of preterm neonates (i.e., necrotizing enterocolitis, chronic lung disease, and retinopathy)
[23]	Early diagnosis, optimal treatment, and appropriate follow-up of iron-deficient infants are recommended.
[24]	Transfer of sufficient zinc to the fetus is dependent on maintenance of normal maternal serum zinc concentrations.
[25]	Increased oxidative stress and deficiency of micronutrients from fetal life were associated with ROP.
[26]	Infants who take iron supplements have slightly higher hemoglobin levels, better iron stores, and a lower risk of iron deficiency anemia than infants who do not take iron supplements.
[27]	Oral zinc supplementation given at high doses reduces morbidities and mortality in preterm neonates.

Iron and premature infants

Iron is an essential micronutrient for physiological processes and its deficiency is associated with many complications [28]. Iron deficiency is common at all ages and is unfortunately very common in children under 5 years of age [29]. In the under-5 age group, premature infants have the highest iron deficiency, and those who consume breast milk without iron supplements are prone to negative iron balance [30]. Maternal factors such as iron deficiency and blood loss during pregnancy are the main factors that lead to iron deficiency in newborns [31].

Diagnosis of iron deficiency in premature infants is made by an initial assessment that includes birth weight and gestational age. In addition, complete blood count tests [32] and ferritin evaluation [33] are performed to diagnose iron deficiency anemia (IDA), indicating the amount of iron stored in the body. High postnatal growth in premature and low birth weight infants are the main factor that causes iron deficiency and predisposes them to IDA [31, 34]. Iron stores in infants are usually considered proportional to age and birth weight. In the third trimester of pregnancy, there is the highest absorption of iron and the maximum reserves are created in the body. However, due to premature birth, iron reserves are not formed and the infant is exposed to iron deficiency or IDA [35]. In this case, the amount of iron stored is less than normal. In addition, the half-life of red blood cells is

shorter due to neonatal characteristics, and on the other hand, due to rapid growth and low absorption of iron, further depletion of iron stores accelerates the onset of clinical symptoms such as retinopathy [36].

Premature infants often undergo several phlebotomies during their stay in neonatal intensive care units. In addition, babies born to mothers with IDA have low blood indexes, low hemoglobin and ferritin levels [37]. In this case, iron supplementation is recommended to prevent IDA [38]. However, the recommended doses in some studies have been associated with side effects such as diarrhea [39] and weight loss [40]. Moreover, an inappropriate dose of iron supplementation in preterm infants is considered a potential risk factor due to insufficient growth and development in defense systems such as the antioxidant system [41]. A premature infant needs to receive 1.6-2.0 mg/kg of iron daily intravenously or 5-6 mg/kg through the intestine because intragastric absorption is approximately 30% [42]. However, such a supplement soon after birth is neither practical nor physiological. Moreover, it is not possible to feed early after birth in most premature infants with very low birth weight [30]. These results showed that premature infants need to receive an appropriate and accurate dose of iron for proper growth.

Zinc and premature infants

Zinc is one of the essential micronutrients involved in many biological activities. Zinc is an essential component of the expression of members of a multigene family, including hormonal receptors. The DNA binding domain of many proteins contains zinc. Therefore, its deficiency or deletion disrupts the activation of their genes by glucocorticoids or estrogens. Participation in metabolism, enzymatic, regulatory and structural activities are among the activities of this element, so any change in plasma concentration or exposure to its deficiency will affect many normal functions of cells and the body [43].

Zinc homeostasis depends on the balance of zinc absorbed from the intestine and its excretion. Unlike healthy infants, in preterm infants, zinc intestinal absorption is not regulated by serum status. The gastrointestinal tract is the main site of zinc loss due to zinc secretion [44], the amount of which is estimated to be between 50 and 150 µg/kg/day [45]. However, part of the zinc that is excreted in the feces is reabsorbed. However, pathological conditions such as diarrhea and steatorrhea can change this condition [44]. Urinary excretion of zinc in premature infants is very high (35 µg/kg/day). As a result, serum zinc concentrations decrease rapidly in the first months of life. This situation shows the importance of supplementing the baby and paying attention to the breastfeeding mother's nutrition. Zinc deficiency can occur at any age and physiological condition, and children, especially infants, pregnant women, and the elderly, are prone to zinc deficiency [46]. Zinc deficiency in these physiological conditions can seriously damage the processes associated with embryogenesis and change the length of pregnancy. Adequate amounts of zinc during embryogenesis affect the final phenotype of all organs [47]. Maternal zinc deficiency increases mortality and abnormalities such as neural tube defects and growth retardation in the fetus. As the duration of pregnancy increases, the concentration of zinc in the fetus increases, and after 24 weeks of pregnancy, hepatic zinc storage is established by its transfer and accumulation via metallothioneins (MTs).

MTs are the most abundant cysteine-rich proteins containing zinc, which is involved in the hepatic accumulation of zinc in the fetus. Moreover, the MTs have antioxidant activity and stabilize the presence of zinc on cell membranes [48]. In the last trimester of pregnancy, transfer of zinc via MTs plays a very important role in hepatic zinc accumulation, so that up to 1.5 mg/kg/day of zinc is transferred to the fetus [49]. The function of these proteins is an active process and the concentration of zinc in the fetus is always higher than its content in the mother. In addition, consumption of foods containing phytate during pregnancy should be controlled during pregnancy due to limited absorption of zinc.

Zinc deficiency is well shown in premature infants. Inadequate consumption during pregnancy can be one of the main causes of zinc deficiency in fraternal women. Premature birth, like iron, reduces zinc stores in the liver. Zinc deficiency can be due to a lack of transfer of zinc from mother to fetus or due to its internal wastage in

neonates [50]. Zinc transmission from mother to baby is through breastfeeding, which is mainly controlled by vector proteins such as ZnT-1, ZnT-2 and ZnT-4. Impaired expression of any of these carriers leads to impaired zinc secretion in breast milk and reduces its content. The zinc content of breast milk at the beginning of lactation is 0.7 to 1.6 mg/L, which decreases over time. Net absorption of zinc in premature infants from breast milk increased probably due to an increase in intestinal transport proteins. In addition, the concentration of zinc in breast milk can be affected by the status of vitamin A, which regulates the status of zinc carriers in the mammary gland. Moreover, zinc metabolism and vitamin A are interrelated, and severe deficiency of this vitamin can reduce zinc absorption by altering its synthetic protein synthesis.

Measurement of serum zinc concentration is the best indicator for diagnosing zinc deficiency. Typical signs of zinc deficiency in newborns include growth impairment and clinical manifestations are observed only for severe zinc deficiency. Premature babies who do not receive supplements are in a negative zinc and iron balance in the first one to two months of life, which is actually due to reduced gestational age and low birth weight. It has been observed that maternal zinc supplementation from the second trimester of pregnancy to delivery by strengthening the immune system reduces the risk of infectious diseases in the first six months of infancy [51]. In addition, the reduction in preterm delivery in low-income women receiving zinc supplementation supports this view [17]. In another way, the use of micronutrient supplements in poor areas should be a priority. Zinc and iron in premature infants are supplied by injection or fortified milk. The recommended dose for the injection method is 0.5-0.8 mg/Kg/day and oral route 4-5 mg/Kg/day.

Association of zinc and iron deficiency with the incidence of ROP

Although the improper growth of retinal vessels is the main pathophysiological mechanism in the development of ROP, its complications are also involved in its development and growth. Excessive increase in inflammatory cytokines, VEGF, hypoxia-inducing factor (HIF) and insulin-like growth factor-1 (IGF-1) along with overproduction of nitric oxide and free radicals impairs retinal blood vessel function and causes retinal ischemia [52, 53]. In addition, polymorphisms in some VEGF, IGF-1, Frizzled-4 (FZD4), and LDL 5 receptor-associated proteins (LRP5) have been reported as important genetic predictors in disease treatment and management [54].

Oxidative damage and inflammation caused by ischemia and subsequent reperfusion due to compensatory growth of blood vessels [55] can be important factors in impaired vision and blindness due to ROP. Excessive release of superoxide anion and NO can damage retinal arteries and cause retinal ischemia. This condition causes serious damage in premature infants and very low birth weight infants due to the lack of antioxidant protection. Studies have shown that defects in the activity of the antioxidant system in order to clear free radicals play an important role in this disease, part of which may be due to impaired homeostasis of some essential elements such as iron and zinc during this period [56]. Premature infants do not have sufficient antioxidant capacity to inhibit oxidative damage, and improper use of iron as a supplement is one of the risk factors for oxidative damage [57]. In addition, oxidative damage is a common pathogenic mechanism in neonatal diseases [58] such as bronchopulmonary dysplasia, subependymal, intraventricular hemorrhage, and necrotizing enterocolitis [59]. Inhibition of these conditions can be important in improving these diseases.

Studies have suggested an association between zinc and iron deficiency as predisposing factors for oxidative damage [58, 60]. Zinc and iron act as co-factors for antioxidant enzymes. Zinc acts as an antioxidant in the stabilization of membranes by inducing the synthesis of MTs. The MTs inhibit hydroxyl radicals and sequestering ROS damages. Zinc also inhibits the enzyme nicotinamide adenine dinucleotide phosphate oxidase (NADPH-Oxidase) [61] (figure 2). Moreover, zinc acts as a glutathione peroxidase cofactor. Zinc and iron are the structural component of superoxide dismutase and catalase. Catalase has an active center with an iron and a zinc ion. This enzyme promotes the neutralization of ROS [62]. In addition, high concentrations of iron are believed to cause oxidative stress. Therefore, proper concentration is essential. It has been reported that zinc upregulates the

mRNA levels of glutamate-cysteine ligase [63]. Therefore, proper levels of iron and zinc are essential for the proper functioning of the antioxidant defense system.

The role of lactation and its physiological mechanisms on ROP

The importance of maternal health and proper nutrition before pregnancy, during pregnancy and lactation, is one of the effective ways to control the incidence of these diseases in infants [64]. It is revealed that breastfeeding, in addition to other benefits for the baby, reduces the incidence of ROP in premature neonates [65]. The most important physiological mechanisms by which breast milk inhibits the occurrence of ROP are its antioxidant and immune protective properties [64]. Inositol, vitamin C, vitamin E, beta-carotene, secretory immunoglobulin A, lactoferrin, lysozyme, cytokines, oligosaccharides and essential fatty acids such as docosahexaenoic acid (DHA) are the main immune-boosting and antioxidant compounds in breast milk [66, 67]. The DHA is an omega-3 fatty acid and a major component of the retina [68]. Omega-3 long-chain polyunsaturated fatty acids improve ROP [69]. In addition, premature infants who are breastfed have higher serum IGF-1 levels [67]. IGF-1 is very important for the physiological growth of retinal vascularization, and its deficiency can lead to impaired vascular growth and ROP. It was found that premature infants who were breastfed had a reduced risk of developing ROP [70]. In addition, breast milk was found to reduce the risk of ROP at discharge compared with RBC injection. These results suggest that promoting breast milk use and improving RBC injections can help reduce the risk of ROP in premature infants. There is a consensus that breast milk has a protective effect on ROP [71-73]. Zhou et al., (2015) and Miller et al., (2018) demonstrated that breast milk reduces the risk of severe ROP [71, 73]. Therefore, feeding with a mother's milk can decrease the risk of ROP and severe ROP in very preterm infants (figure 2) [27, 35, 41, 65, 71-73].

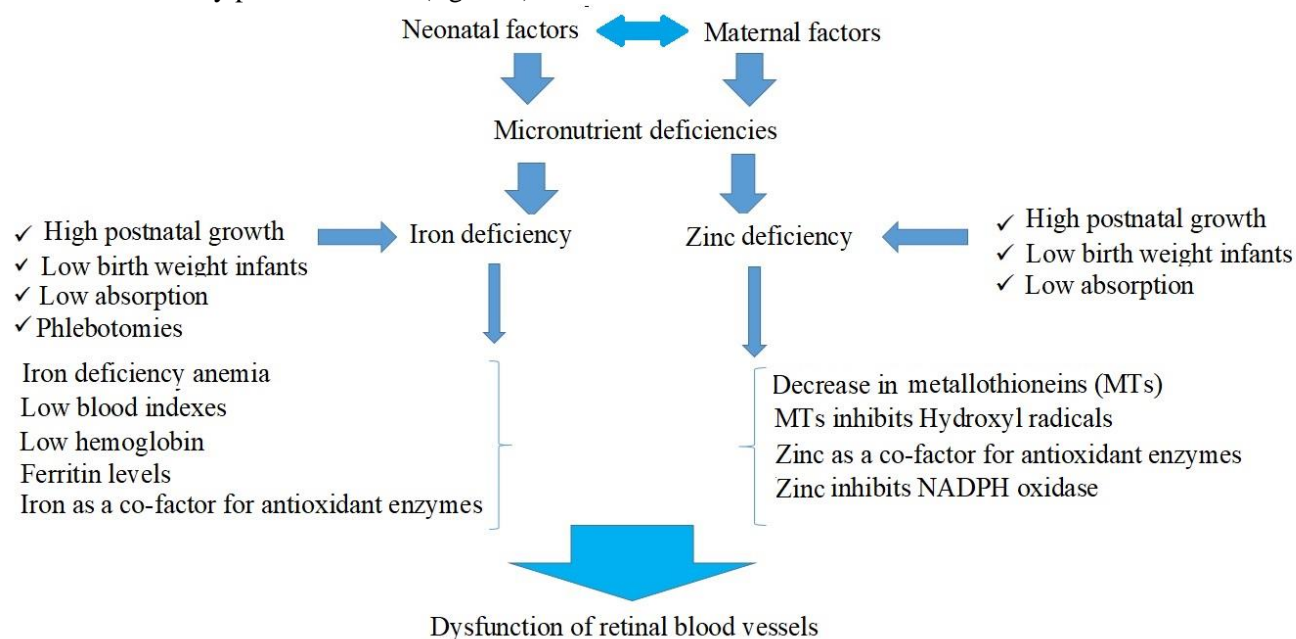


Figure 2: The role of maternal and neonatal factors along with iron and zinc deficiency in the development of retinopathy of premature

Limitations of the study

Preterm infants are at risk of depleting their zinc and iron stores. To prevent the consequences of deficiency of these elements, it is common to supplement them in premature and low birth weight infants. However, iron overload can lead to oxidative damage in premature infants and can cause or exacerbate conditions such as

necrotizing enterocolitis and premature retinopathy. Serum ferritin measurements are used to estimate the body's total iron stores and the risk of iron deficiency or overload. In addition, the optimal dose and time to start and stop iron supplementation are unclear. Therefore, it is necessary to evaluate the serum concentrations of these elements in order to control the damage caused by their deficiency or overload after birth and lactation.

Conclusion

Zinc and iron are key elements for growth and development. Maintaining adequate levels of zinc and iron is very important to prevent the adverse consequences of impaired prenatal and postnatal development. Adequate iron and zinc are essential for embryogenesis and the final phenotype of all organs. Therefore, the restriction of maternal zinc and iron during pregnancy affects fetal growth. Knowing the status of these two elements during this period and taking appropriate supplements not only improve the embryonic process, but also reduce the risk of premature birth. Premature infants are at increased risk for associated diseases including ROP, due to low iron and zinc stores resulting from reduced placental transfer time, increased endogenous losses, and low intake. Early diagnosis of maternal zinc and iron deficiency by measuring serum concentrations is essential to avoid severe prenatal and postnatal consequences. The most common clinical manifestations of iron and zinc deficiency include developmental disorders of important organs such as the retina of the visual system and the differentiation of the nervous system. Thus, moderate zinc and iron deficiency can exacerbate necrotizing enterocolitis, chronic lung disease, and retinopathy. The occurrence of these manifestations despite care during pregnancy and before birth suggests that the current recommended rate should be revised to meet the needs of premature infants.

Acknowledgments

The authors would like to thank the Research Deputy of Babol University of Medical Sciences for financial support and Ms. Reyhaneh Barari for the grammatical editing of this article.

Conflict of interest

The authors declare that there is no conflict of interest.

References

1. Chen J, Smith LE. Retinopathy of prematurity. *Angiogenesis* 2007; 10(2): 133-40.
2. Ahmadpour-Kacho M, Jashni Motlagh A, Rasoulinejad SA, et al. Correlation between hyperglycemia and retinopathy of prematurity. *Pediatr Inter* 2014; 56(5): 726-30.
3. Kim SJ, Port AD, Swan R, et al. Retinopathy of prematurity: a review of risk factors and their clinical significance. *Survey ophthalmol* 2018; 63(5): 618-37.
4. Kemper AR, Wade KC, Hornik CP, et al. Retinopathy of prematurity risk prediction for infants with birth weight less than 1251 grams. *J Pediatr* 2015; 166(2): 257-61.
5. Blencowe H, Lawn JE, Vazquez T, et al. Preterm-associated visual impairment and estimates of retinopathy of prematurity at regional and global levels for 2010. *Pediatr Res* 2013; 74 Suppl 1(Suppl 1): 35-49.
6. Azami M, Jaafari Z, Rahmati S, et al. Prevalence and risk factors of retinopathy of prematurity in Iran: A systematic review and meta-analysis. *BMC Ophthalmol* 2018; 18(1): 1-14.
7. Saeidi R, Taraghi B. Incidence of Retinopathy of Prematurity (ROP) in Low Birth Weight Newborns. *Iran J Neonatol* 2017; 8(4): 102-6.
8. Dai AI, Demiryürek S, Aksoy SN, et al. Maternal iron deficiency anemia as a risk factor for the development of retinopathy of prematurity. *Pediatr Neurolog* 2015; 53(2): 146-50.
9. Hutchinson AK, Melia M, Yang MB, et al. Clinical models and algorithms for the prediction of retinopathy of prematurity: a report by the American Academy of Ophthalmology. *Ophthalmol* 2016; 123(4): 804-16.
10. Carroll L, Owen LA. Current evidence and outcomes for retinopathy of prematurity prevention: insight into novel maternal and placental contributions. *Explor Med* 2020; 1: 4.

11. Alajbegovic-Halimic J, Zvizdic D, Alimanovic-Halilovic E, et al. Risk factors for retinopathy of prematurity in premature born children. *Med Arch* 2015; 69(6): 409-13.
12. Kim SJ, Port AD, Swan R, et al. Retinopathy of prematurity: a review of risk factors and their clinical significance. *Surv Ophthalmol* 2018; 63(5): 618-37.
13. Rasoulinejad SA, Montazeri M. Retinopathy of prematurity in neonates and its risk factors: a seven year study in northern Iran. *Open Ophthalmol J* 2016; 10: 17.
14. Ahmadpour-kacho M, Zahedpasha Y, Rasoulinejad SA, et al. Correlation between retinopathy of prematurity and clinical risk index for babies score. *Tehran Uni Med J* 2014; 72(6): 404-11.
15. Maroufizadeh S, Almasi-Hashiani A, Omani Samani R, Sepidarkish M. Prevalence of retinopathy of prematurity in Iran: a systematic review and Meta-analysis. *Int J Ophthalmol* 2017; 10(8): 1273-9.
16. Symington EA, Baumgartner J, Malan L, et al. Maternal iron-deficiency is associated with premature birth and higher birth weight despite routine antenatal iron supplementation in an urban South African setting: The NuPED prospective study. *PLoS One* 2019; 14(9): e0221299.
17. Terrin G, Berni Canani R, Di Chiara M, et al. Zinc in early life: a key element in the fetus and preterm neonate. *Nutrient* 2015; 7(12): 10427-46.
18. Verner AM, Manderson J, Lappin TRJ, et al. Influence of maternal diabetes mellitus on fetal iron status. *Arch Dis Child Fetal Neonatal Ed* 2007; 92(5): F399-401.
19. Shah PK, Prabhu V, Karandikar SS, et al. Retinopathy of prematurity: Past, present and future. *World J Clin Pediatr* 2016; 5(1): 35-46.
20. Hossain Z, Qasem WA, Friel JK, Omri A. Effects of Total Enteral Nutrition on Early Growth, Immunity, and Neuronal Development of Preterm Infants. *Nutrient* 2021; 13(8): 2755.
21. Ferri C, Procianny RS, Silveira RC. Prevalence and Risk Factors for Iron-Deficiency Anemia in Very-Low-Birth-Weight Preterm Infants at 1 Year of Corrected Age. *J Tropical Pediatr* 2014; 60(1): 53-60.
22. Terrin G, Berni Canani R, Di Chiara M, et al. Zinc in Early Life: A Key Element in the Fetus and Preterm Neonate. *Nutrient* 2015; 7(12): 10427-46.
23. Rao R, Georgieff MK. Iron in fetal and neonatal nutrition. *Semin Fetal Neonat Med* 2007; 12(1): 54-63.
24. King JC. Determinants of maternal zinc status during pregnancy. *American J Clin Nutr* 2000; 71(5): 1334-43S.
25. Agrawal G, Dutta S, Prasad R, Dogra MR. Fetal oxidative stress, micronutrient deficiency and risk of retinopathy of prematurity: A nested case-control study. *Europ J Pediatr* 2021; 180(5): 1487-96.
26. Mills RJ, Davies MW. Enteral iron supplementation in preterm and low birth weight infants. *Cochrane Database of System Rev* 2012(3). <https://doi.org/10.1002/14651858.CD005095.pub2>.
27. Terrin G, Berni Canani R, Passariello A, et al. Zinc supplementation reduces morbidity and mortality in very-low-birth-weight preterm neonates: a hospital-based randomized, placebo-controlled trial in an industrialized country. *American J Clin Nutr* 2013; 98(6): 1468-74.
28. Wang Y, Wu Y, Li T, et al. Iron Metabolism and Brain Development in Premature Infants. *Front Physiol* 2019; 10: 463.
29. Muñoz M, Villar I, García-Erce JA. An update on iron physiology. *World J Gastroenterol* 2009; 15(37): 4617-26.
30. Rao R, Georgieff MK. Iron therapy for preterm infants. *Clinics Perinatol* 2009; 36(1): 27-42.
31. Moreno-Fernandez J, Ochoa JJ, Latunde-Dada GO, Diaz-Castro J. Iron deficiency and iron homeostasis in low birth weight preterm infants: A systematic review. *Nutrient* 2019; 11(5): 1090.
32. Wang M. Iron deficiency and other types of anemia in infants and children. *American Family Physician* 2016; 93(4): 270-8.
33. Sifakis S, Pharmakides G. Anemia in pregnancy. *Annals of the New York Academy of Sciences* 2000; 900(1): 125-36.
34. Domellöf M. Meeting the Iron needs of low and very low birth weight infants. *Annals of Nutrition and Metabolism* 2017; 71(Suppl. 3): 16-23.
35. Fisher AL, Nemeth E. Iron homeostasis during pregnancy. *Am J Clin Nutr* 2017; 106(Suppl 6): 1567-74S.
36. Raffaelli G, Manzoni F, Cortesi V, et al. Iron homeostasis disruption and oxidative stress in preterm newborns. *Nutrient* 2020; 12(6): 1554.
37. Ghadimi R, Esmaili H, Kheirkhah D, Tamaddoni A. Is childhood obesity associated with iron deficiency anemia? *Caspian J Pediatr* 2015; 1(2): 59-66.
38. World Health Organization. Iron deficiency anemia. assessment, prevention, and control. A guide for programme managers 2001: 47-62.
39. Dewey KG, Domellöf M, Cohen RJ, et al. Iron supplementation affects growth and morbidity of breast-fed infants: results of a randomized trial in Sweden and Honduras. *J Nutr* 2002; 132(11): 3249-55.
40. Majumdar I, Paul P, Talib VH, Ranga S. The effect of iron therapy on the growth of iron-replete and iron-deplete children. *J Trop Pediatr* 2003; 49(2): 84-8.
41. Rao R, Georgieff MK. Iron in fetal and neonatal nutrition. *Semin Fetal Neonat Med* 2007; 12(1): 54-63.
42. Fomon SJ, Nelson SE, Ziegler EE. Retention of iron by infants. *Annual Rev Nutrition* 2000; 20(1): 273-90.

43. Nimrouzi M, Ruyvaran M, Zamani A, et al. Oil and extract of safflower seed improve fructose induced metabolic syndrome through modulating the homeostasis of trace elements, TNF- α and fatty acids metabolism. *J Ethnopharmacol* 2020; 254: 112721.
44. Passariello A, Terrin G, Baldassarre ME, et al. Diarrhea in neonatal intensive care unit. *World J Gastroenterol* 2010; 16(21): 2664-8.
45. Roohani N, Hurrell R, Kelishadi R, Schulin R. Zinc and its importance for human health: An integrative review. *J Res Med Sci: Offic J Isfahan Uni Med Sci* 2013; 18(2): 144-57.
46. Biesalski Hans K, Jana T. Micronutrients in the life cycle: Requirements and sufficient supply. *NFS J* 2018; 11: 1-11.
47. Cetin I, Berti C, Calabrese S. Role of micronutrients in the periconceptional period. *Human Reproduction Update* 2010; 16(1): 80-95.
48. Jarosz M, Olbert M, Wyszogrodzka G, et al. Antioxidant and anti-inflammatory effects of zinc. Zinc-dependent NF- κ B signaling. *Inflammopharmacol* 2017; 25(1): 11-24.
49. Donangelo CM, King JC. Maternal zinc intakes and homeostatic adjustments during pregnancy and lactation. *Nutrient* 2012; 4(7): 782-98.
50. Sur D, Gupta DN, Mondal SK, et al. Impact of zinc supplementation on diarrheal morbidity and growth pattern of low birth weight infants in kolkata, India: A randomized, double-blind, placebo-controlled, community-based study. *Pediatric* 2003; 112(6): 1327-32.
51. Ota E, Mori R, Middleton P, et al. Zinc supplementation for improving pregnancy and infant outcome. *Cochrane Database System Rev* 2015; 2015(2): Cd000230.
52. Heidary G, Vanderveen D, Smith LE. Retinopathy of prematurity: current concepts in molecular pathogenesis. *Semin Ophthalmol* 2009; 24(2): 77-81.
53. Luo X-q, Zhang C-y, Zhang J-w, et al. Identification of Iron Homeostasis Genes Dysregulation Potentially Involved in Retinopathy of Prematurity Pathogenicity by Microarray Analysis. *J Ophthalmol* 2015; 2015: 584854.
54. Kondo H, Kusaka S, Yoshinaga A, et al. Genetic variants of FZD4 and LRP5 genes in patients with advanced retinopathy of prematurity. *Molecular Vision* 2013; 19: 476-85.
55. Rasoulinejad SA, Akbari A, Nasiri K. Interaction of miR-146a-5p with oxidative stress and inflammation in complications of type 2 diabetes mellitus in male rats: antioxidant and anti-inflammatory protection strategies in type 2 diabetic retinopathy. *Iran J Basic Med Sci* 2021; 24(8): 1078-86.
56. Widness JA. Pathophysiology of Anemia During the Neonatal Period, Including Anemia of Prematurity. *Neorev* 2008; 9(11): e520.
57. Ozsurekci Y, Aykac K. Oxidative Stress Related Diseases in Newborns. *Oxidat Med Cell Longevit* 2016; 2016: 2768365.
58. Akbari A, Jelodar G, Nazifi S, et al. Oxidative stress as the underlying biomechanism of detrimental outcomes of ionizing and non-ionizing radiation on human health: Antioxidant protective strategies. *Zahedan J Res Med Sci* 2019; 21(4): e85655.
59. Atalay D, Salihoğlu O, Can E, et al. Short-term outcomes of very low birth weight infants born at a tertiary care hospital, istanbul, Turkey. *Iran J Pediatr* 2013; 23(2): 205-11.
60. Akbari A, Jelodar GA. The effect of oxidative stress and antioxidants on men fertility. *Zahedan J Res Med Sci* 2013; 15(7): 1-7.
61. Marreiro DdN, Cruz KJC, Morais JBS, et al. Zinc and oxidative stress: Current mechanisms. *Antioxidants (Basel)* 2017; 6(2): 24.
62. Akbari A, Nasiri K, Heydari M, et al. Ameliorating potential of ginger (*Zingiber officinale* Roscoe) extract on liver function and oxidative stress induced by ethanol in male rats. *Zahedan J Res Med Sci* 2019; 21(2): e86464.
63. Ha KN, Chen Y, Cai J, Sternberg P. Increased glutathione synthesis through an ARE-Nrf2-dependent pathway by zinc in the RPE: implication for protection against oxidative stress. *Investigative Ophthalmol Visual Sci* 2006; 47(6): 2709-15.
64. Gila-Diaz A, Arribas SM, Algara A, et al. A Review of Bioactive Factors in Human Breastmilk: A Focus on Prematurity. *Nutrient* 2019; 11(6): 1307.
65. Manzoni P, Stolfi I, Pedicino R, et al. Human milk feeding prevents retinopathy of prematurity (ROP) in preterm VLBW neonates. *Early Human Develop* 2013; 89: S64-8.
66. Lenhartova N, Matasova K, Lasabova Z, et al. Impact of early aggressive nutrition on retinal development in premature infants. *Physiol Res* 2017; 66(Suppl 2): S215-26.
67. Wilson CB, Ogra PL. Human Milk. *Infect Dis Fetus Newborn* 2011: 191-220.
68. Fares S, Sethom MM, Hammami MB, et al. Increased docosahexaenoic acid and n-3 polyunsaturated fatty acids in milk from mothers of small for gestational age preterm infants. *Prostaglandins, leukotrienes, and essential fatty acids* 2018; 135: 42-6.

69. Harris WS, Baack ML. Beyond building better brains: bridging the docosahexaenoic acid (DHA) gap of prematurity. *J Perinatol* 2015; 35(1): 1-7.
70. Hellström A, Ley D, Hansen-Pupp I, et al. IGF-I in the clinics: Use in retinopathy of prematurity. *Growth Horm IGF Res* 2016; 30: 75-80.
71. Zhou J, Shukla VV, John D, Chen C. Human Milk Feeding as a Protective Factor for Retinopathy of Prematurity: A Meta-analysis. *Pediatr* 2015; 136(6): e1576-86.
72. Bharwani SK, Green BF, Pezzullo JC, et al. Systematic review and meta-analysis of human milk intake and retinopathy of prematurity: A significant update. *J Perinatol* 2016; 36(11): 913-20.
73. Miller J, Tonkin E, Damarell RA, et al. A systematic review and meta-analysis of human milk feeding and morbidity in very low birth weight infants. *Nutrient* 2018; 10(6): 707.