

Spontaneous pneumomediastinum in a child with diabetic ketoacidosis: A rare complication

Masood Kiani (MD)¹ , Morteza Alijanpour (MD)^{2*} , Maedeh Motadel (MD)³ 

1. Non-Communicable Pediatric Diseases Research Center, Health Research Institute, Babol University of Medical Sciences, Babol, IR Iran; m.kiani@mubabol.ac.ir.

2. The Clinical Research Development Unit of Amirkola Children's Hospital, Babol University of Medical Sciences, Babol, IR Iran; m.alijanpour@mubabol.ac.ir.

3. Student Research Committee, Babol University of Medical Sciences, Babol, Iran; maedehmotadel@gmail.com.

Article Info

Article type:

Case Report

Received: 3 Jan 2021

Revised: 20 Feb 2021

Accepted: 7 March 2021

Keywords:

Diabetic Ketoacidosis,
Intrathoracic Pressure,
Pneumomediastinum,
Vomiting

ABSTRACT

Background: Spontaneous pneumomediastinum (SPM) can be due to increased intrathoracic pressure. Its occurrence with Diabetic Ketoacidosis (DKA) is a very rare, but may be caused by severe vomiting or deep, rapid, and labored (Kussmaul) breathing.

Case Report: The patient is a 15-year-old girl with a history of type 1 diabetes mellitus (T₁DM) who has been hospitalized due to nausea, severe vomiting, dyspnea, abdominal and chest pain. Based on physical examination and imaging (CXR and chest CT scan), pneumomediastinum (PM) was confirmed. The patient received conservative treatment for PM and treatment for DKA. The patient finally discharged after 5 days in a good general condition.

Conclusion: SPM is a rare complication of DKA, usually with a good prognosis if diagnosed and treated timely.

Cite this article: Kiani M, Alijanpour M, Motadel M. Spontaneous pneumomediastinum in diabetic ketoacidosis: A rare complication. *Caspian J Pediatr* March 2021; 7(1): 523-7.



© The Author(s).

Publisher: Babol University of Medical Sciences

Introduction

Diabetes mellitus (DM) is a common metabolic disease defined by a high blood level of glucose ^[1]. The most common type of DM in children is type 1 diabetes mellitus (T₁DM) characterized by the destruction of pancreatic β-cells and the consequent severe insulin deficiency ^[1]. Diabetic ketoacidosis (DKA) is one of the most important complications of T₁DM in the acute phase of disease which can be life-threatening ^[1].

The presence of air in the mediastinum is called pneumomediastinum (PM) and it may be spontaneous or traumatic ^[1]. Spontaneous pneumomediastinum (SPM) is an infrequent, benign, and self-limiting condition which categorized into primary (without underlying factor) or secondary ^[1, 2]. Primary SPM can be the result of an increased intrathoracic pressure, which can be seen in various conditions such as Valsalva maneuver, vomiting, weight lifting, and Boerhaave syndrome due to esophageal rupture ^[3, 4]. Common causes of secondary SPM in children include lower respiratory tract infections and asthma attacks ^[1].

***Corresponding Author:** Morteza Alijanpour (MD);

Address: Non-Communicable Pediatric Diseases Research Center, Health Research Institute, Babol University of Medical Sciences, No 19, Amirkola Children's Hospital, Amirkola, Babol, Mazandaran Province, 47317-41151, IR Iran,.

Tel-Fax: +98 1132346963

E-mail: m.alijanpour@yahoo.com, m.alijanpour@mubabol.ac.ir

Due to an acute increase in intrathoracic pressure, vomiting can lead to SPM, although this is a rare complication. On the other hand, vomiting can lead to PM and mediastinitis (Boerhaave syndrome) as a result of esophageal rupture, which should be differentiated from SPM caused by vomiting [5]. Vomiting is a relatively common finding in DKA and Vomiting-induced PM can be a very rare complication of DKA with a limited number of case reports about PM in DKA [2, 6, 7].

SPM is a rare and usually benign condition that often resolves without complications [4]. The mechanism of PM in DKA may include one or more factors. Kussmaul breathing due to acidosis in DKA can increase transalveolar pressure by 20-30 mmHg and lead to rupture of the alveoli. On the other hand, severe vomiting can increase intraalveolar pressure and result in rupture of the alveoli due to contraction of the abdominal muscles against the closed glottis. In addition, vomiting can increase the esophageal intraluminal pressure above the esophageal wall stretching pressure which results in rupture of the esophageal wall (Boerhaave syndrome) [6, 7, 8].

SPM can be asymptomatic, but symptoms such as chest pain, dyspnea, neck pain, and subcutaneous emphysema have been reported. Imaging studies for the diagnosis of PM include CXR and chest CT scans.

The clinical signs of SPM and Boerhaave syndrome may be somewhat similar. Both of these conditions may be associated with a range of symptoms, including chest pain, cough and shortness of breath, sore throat, dysphonia, dysphagia, neck pain, and subcutaneous emphysema. An important finding to distinguish between the two is the patient's clinical condition, in which the patient with mediastinitis secondary to Boerhaave syndrome is usually toxic and may have signs of septic shock. But the patients with SPM are usually well [5].

Treatment is directed primarily at the precipitating condition. Once the diagnosis is confirmed, the SPM can be managed conservatively by treating the underlying condition, together with rest, analgesia and supplemental oxygen [1, 5].

PM can lead to respiratory distress and complicate the diabetic patient's condition and make DKA management more difficult. With respect to the importance of timely diagnosis and treatment of PM in DKA patients which can be life-threatening, we decided to present a diabetic patient with DKA and PM.

Case Report

The patient was a 15-year-old girl with a history of T₁DM from 4 years ago. She had severe and frequent nausea and vomiting from 2 days before hospitalization. The patient had a mild fever, dyspnea and chest pain without cough for the past 2 days. At first, she was admitted to another center, and for arterial blood gas analysis (table 1), lethargy and hyperglycemia (Blood Sugar (BS): 450 mg/dl), the diagnosis of DKA was considered. She was treated for DKA. On the next day, she was referred to our center (Amirkola Children's Hospital-northern Iran). At the time of admission, her vital signs included: BP: 110/70 mmHg, T: 37°C, RR: 18/min, PR: 80/min and SPO₂:96% on room air.

Treatment continued with the DKA protocol (Insulin therapy with a dose of 0.1 U/kg/hr in the form of continuous infusion with half saline serum). The patient's laboratory findings were shown in table 1.

Because of dyspnea and chest pain, the patient underwent pulmonologist consultation. On examination by a pulmonologist, the patient had no respiratory distress and pulmonary sounds were reported to be normal and CXR (figure 1) was requested for the patient, which showed evidence in favor of PM such as air along with mediastinal structures and heart border without subcutaneous emphysema and CT scan (figure 2) was performed to determine the presence of air in the mediastinum and confirm the diagnosis.

Twelve hours after hospitalization in our center, the patient alertness and ABG criteria showed that the patient was out of the DKA phase, so the basal-bolus protocol was started to continue diabetes treatment. In this protocol, insulin Glargine was used subcutaneously every night and insulin Aspart was used subcutaneously with meals and based on carbohydrate-content calculation. The patient also underwent supportive measures for PM, including analgesic (Apotel) and supplemental oxygen. She did not suffer from complications such as

subcutaneous emphysema (SCE) and pneumothorax during hospitalization. She was discharged from hospital after 5 days with acceptable BS and normal CXR, without chest pain, in a good general condition.

Table 1. Patient's laboratory findings

Factor	Admission time level	After 48 hours level
CBC	Hb: 10.7 g/dl	-
	Plt: 184000/ μ L	-
	WBC: 4600/ μ L	-
VBG	PH:7.12	PH:7.48
	PCO ₂ : 22	PCO ₂ : 39
	HCO ₃ : 10	HCO ₃ : 29
CRP	17 mg/L	-

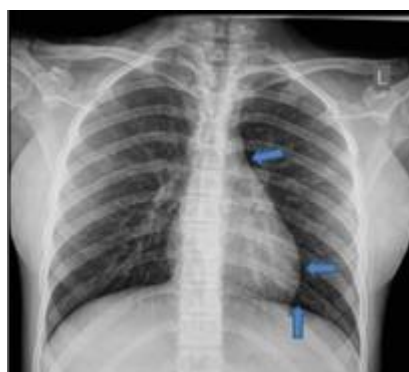

Figure 1. CXR shows lucency (air) along with mediastinum and between the heart and superior surface of the diaphragm

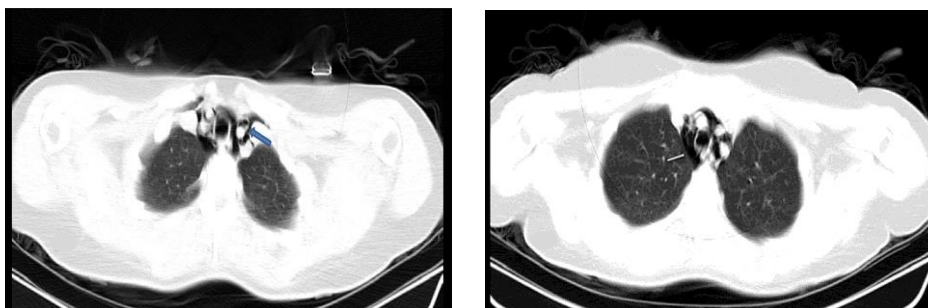


Figure2. CT imaging shows the air in mediastinal space (arrow)

Discussion

Our presentation is about a 15-year-old girl with a history of T1DM who developed PM as a complication of DKA and improved with conservative treatment.

SPM is very rare, with an incidence of about 1 in 7000 to 100,000 reported in various centers. Our patient was female, while according to other studies, there is a male preference ^[2, 4]. Our patient was 15 years old. The

incidence of the disease in children and adolescents includes two peaks, one under 4 years and the other 15-18 years [4].

DKA-related PM is very rare. In a study conducted by Lee et al. in Taiwan between 1997 and 2007, out of a total of 18 patients with SPM, only 1(5.6%) was due to DKA. In this study, the most common etiology in younger children was infectious causes including bronchiolitis and pneumonia, and in adolescents, the most common etiology was idiopathic [4].

The most common symptoms of PM are chest pain and shortness of breath [2, 4, 6] as seen in our patient. Other symptoms may include neck pain, sore throat, back pain, dysphagia and shoulder pain [4]. PM also can be asymptomatic [2].

The most common sign of PM is subcutaneous emphysema (SCE) [4]. Our patient did not develop subcutaneous emphysema during the disease, unlike the study of Rojas et al. [2], where the patient developed subcutaneous emphysema. In the study by Lee et al., 10 of 18 patients (55.6%) had SCE [4].

The initial diagnostic tool includes CXR, which indicates the presence of air in the mediastinum and a more distinct cardiac border [1, 2]. For better evaluation and also in cases where CXR is negative but there is a high clinical suspicion about PM, the CT scan is helpful [2].

Treatment of PM is often conservative and includes rest, analgesics, oxygen and treatment of underlying disease [2, 4]. In cases of PM with DKA, patients should be treated for DKA, including water and electrolyte correction, insulin, acidosis correction, and antibiotics if needed [5, 9]. Like other studies, our patient recovered with DKA treatment and supportive measures without any complications.

Patients with severe PM and SCE may require decompression through subcutaneous drainage or multiple subcutaneous angiocatheters. But most patients with DKA and PM have a good prognosis, mortality is low, and most patients recover in about 1-2 weeks and discharge from the hospital like our patient [9, 10, 11].

Conclusion

SPM with DKA is a very rare complication and should be considered in patients with DKA and dyspnea to avoid underdiagnosis. SPM with DKA usually has a good prognosis and the patient recovers with the treatment of the underlying disease and conservative measures.

Acknowledgment

We are grateful to the Clinical Research Development Committee of Amirkola Children's Hospital, Babol University of Medical Sciences for their contribution to this study.

Ethical Code

This study has been registered with the ethical code of IR.MUBABOL.REC.1400.219 in the Ethics Committee of Babol University of Medical Sciences.

Funding

This study was self-funded.

Conflict of interest

There was no conflict of interest

References

1. Winnie GB, Vemana AP, Haider SK. Pneumomediastinum, In: Kliegman RM, Geme J. Nelson Textbook of Pediatrics. 21th ed. Elsevier. 2020; pp: 2321, 3020.
2. Rojas PG, Agostinho J, Hanna R, Karasik O. Spontaneous pneumomediastinum as a consequence of severe vomiting in diabetic ketoacidosis. *Cureus* 2018; 10(5): e2562.
3. Langwieler TE, Steffani KD, Bogoevski DP, et al. Spontaneous pneumomediastinum. *Ann Thorac Surg* 2004; 78(2): 711-3.
4. Lee CY, Wu CC, Lin CY. Etiologies of spontaneous pneumomediastinum in children of different ages. *Pediatr Neonat* 2009; 50(5): 190-5.
5. Forshaw MJ, Khan AZ, Strauss DC, et al. Vomiting-induced pneumomediastinum and subcutaneous emphysema does not always indicate Boerhaave's syndrome: report of six cases. *Surg today* 2007; 37(10): 888-92.
6. Al-Mufarrej F, Badar J, Gharagozloo F, et al. Spontaneous pneumomediastinum: diagnostic and therapeutic interventions. *J Cardiothoracic Surg* 2008; 3(1): 1-4.
7. Alkhuja S, Gazizov N, Charles G. Pneumomediastinum complicating diabetic ketoacidosis and Boerhaave's syndrome. *Case Report Med* 2013; 2013. <https://doi.org/10.1155/2013/598720>
8. Steenkamp D, Patel V, Minkin R. A case of pneumomediastinum: a rare complication of diabetic ketoacidosis. *Clin Diabet* 2011; 29(2): 76-7.
9. Zhang W, Chen J, Wu X, et al. Analysing the clinical features of pneumomediastinum associated with diabetic ketoacidosis in 79 cases. *Diabet Metab Syndr* 2020; 13: 405-12.
10. Martínez MS, Quintas RD, Velázquez PM. Treatment with subcutaneous drainage in the pneumomediastinum and massive subcutaneous emphysema. *Arch Bronconeumol* 2013; 49(3): 127-8.
11. Robinson B. Rapid resolution of severe subcutaneous emphysema with simple percutaneous angiocatheter decompression. *J Surg Case Report* 2018; 2018(7): rjy173.