

Pneumomediastinum and subcutaneous emphysema: A case report of rare presentations of foreign body aspiration

Case Report

Abbas Hadipour (MD)¹
Masood Kiani (MD)^{2*}

1. The Clinical Research Development Unit of Amirkola Children's Hospital, Babol University of Medical Sciences, Babol, IR Iran.

ORCID ID orcid.org/0000-0003-3804-4634

2. Non-Communicable Pediatric Diseases Research Center, Health Research Institute, Babol University of Medical Sciences, Babol, IR Iran.

ORCID ID orcid.org/0000-0002-2077-0913

* Correspondence:

Masood Kiani (MD)

Non-Communicable Pediatric Diseases Research Center, No 19, Amirkola Children's Hospital, Amirkola, Babol, Mazandaran Province, 47317-41151, IR Iran.

E-mail: kianimasood@yahoo.com

Tel: +98 1132346963

Fax: +98 1132346963

Received: 7 June 2020

Revised: 19 July 2020

Accepted: 18 Aug 2020

Abstract

Background: Pneumomediastinum (PM) is caused by alveolar rupture. If air leak persists, subcutaneous emphysema occurs. The PM and subcutaneous emphysema have various etiologies. Common causes are respiratory tract infections and asthma exacerbations. Rarely, the PM occurs secondary to foreign body aspiration, and the life-threatening complications will occur without proper treatment.

Case report: we report a 2.5- year- old boy who was presented with cough, fever, neck swelling and respiratory distress to Amirkola Children's Hospital. On examination, he had subcutaneous emphysema (SCE) in neck and upper thorax. He had pneumomediastinum in radiography. The patient was treated with oxygen, antibiotic, and due to the suspicious history of foreign body aspiration he underwent bronchoscopy by which pieces of nuts removed from his right main bronchus.

Conclusions: PM and SCE are rare presentations of foreign body aspiration and in such circumstances, the possibility of foreign body should be considered.

Key Words: Child, Foreign Body Aspiration, Pneumomediastinum, Subcutaneous Emphysema

Citation:

Hadipour A, Kiani M. Pneumomediastinum and subcutaneous emphysema: A case report of rare presentations of foreign body aspiration. *Caspian J Pediatr* Sep 2020; 6(2): 426-9.

Introduction

Pneumomediastinum (PM) means the presence of free air in mediastinal space. It is caused by any condition that creates a pressure gradient between intra-alveolar and interstitial perivascular space due to the rupture of the tracheobronchial tree. Subcutaneous emphysema (SCE) occurs when air enters the subcutaneous tissue through the mediastinum [1, 2, 3]. The PM can be primary (due to the increase of intrathoracic pressure like Valsalva maneuver or vomiting) or secondary to an underlying etiology. Common causes of secondary PM in children are respiratory tract infections and asthma exacerbation. Traumatic causes of PM include iatrogenic (dental extractions, adenotonsillectomy and esophageal perforation) and non-iatrogenic (foreign body aspiration, penetrating chest trauma) [4]. Foreign body aspiration is common in children younger than 4 years. Clinical manifestations can include cough, wheezing, respiratory distress and recurrent pneumonia. Rarely, foreign body aspiration presents with PM and SCE. The PM and SCE are rare presentations of foreign body aspiration, and very few cases have been reported till date [1, 5]. Foreign body in the airway increases resistance to expiratory flow, and cough can result in alveolar rupture and progressive emphysema. The PM can occur at the time of aspiration of foreign body or several days later [6]. In this report, we present a case of foreign body aspiration, who manifested with PM and SCE.

Case Report

A 2.5-year-old boy was admitted to our emergency department of Amirkola Children's Hospital with fever, cough, neck swelling and respiratory distress. His symptoms started 2 days ago and got worse gradually.

Patient's vital signs were temperature: 39°C, heart rate: 120 rate/minutes, respiratory rate: 42 rate/minutes and oxygen saturation with pulse oximeter (Spo₂): 94% in room air. On physical examination, he had neck swelling, crepitation in neck and upper thorax, and mild suprasternal retraction. In auscultation, there was decreased breath sound and crackles on upper zone of the right lung. Other physical exams were normal.

Blood gas analysis revealed respiratory alkalosis (PH: 7.44, PCO₂: 29.7, HCO₃: 21), and other laboratory tests were normal. Chest-x-ray showed pneumomediastinum and subcutaneous emphysema (fig-1).

Patient was transferred to PICU, given oxygen 10 L/min with oxyhood and treated with antibiotic (cefotaxime 50 mg/kg per 6 hours and clindamycin 10 mg/kg per 8 hours for one week) because of radiographic findings of pneumonia. He had a suspicious and unclear history of cough after eating nuts 3 weeks ago and thereafter, he was asymptomatic till now. Due to the progressive emphysema and patient's suspicious history of choking, the possibility of foreign body aspiration was considered, and he was candidate for bronchoscopy. Rigid bronchoscopy was performed by surgeon under general anesthesia. On bronchoscopy, pieces of nuts and thick secretions were seen in right main bronchus and then removed.

After bronchoscopy, treatment with O₂ and antibiotic was continued, and bronchodilator and inhaled corticosteroid were started. Patient's symptoms were gradually improved, and subcutaneous emphysema resolved during several days after bronchoscopy. Repeated chest-x-ray (fig-2) after 3 days of bronchoscopy was normal without findings of subcutaneous emphysema or pneumomediastinum. After one week, the patient was discharged from hospital with good general condition and no respiratory distress.

Discussion

This report described a 2.5-year-old child admitted with fever, cough, respiratory distress and subcutaneous emphysema and pneumomediastinum. Because of his progressive symptoms and having an unclear history of foreign body aspiration, the bronchoscopy was performed, and the nut was removed from right main bronchus.

Foreign body aspiration is common in children. About 70% of cases occur in children younger than 4 years. The most common objects which choke children are nuts, seeds, hard candy and bones. There are three stages for aspiration symptoms. First stage includes cough, gagging and possibly airway obstruction that occur immediately after aspiration. In the second stage, the symptoms subside and result in delayed diagnosis, and in the third stage, the complications of obstruction and infection may occur ^[7].

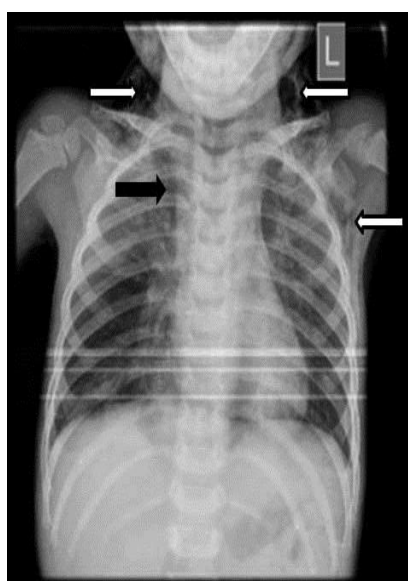


Figure 1. Neck and chest radiograph shows subcutaneous emphysema (white arrow) and pneumomediastinum (black arrow).

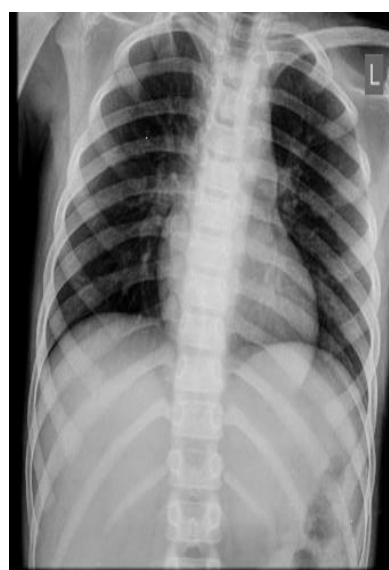

Figure 2. Chest X-ray after three days of bronchoscopy shows normal findings.

The PM and SCE secondary to foreign body aspiration is rare in children [4, 6]. Its incidence is about 1% in reports from the United States (USA) and china [6]. In a study on a Children's Medical Center in china, no cases of PM secondary to foreign body aspiration were found over a period of 10 years [1]. In another study conducted in the USA, only one child of 126 children with foreign body aspiration had PM [1]. The exact mechanism of PM and SCE secondary to foreign body aspiration is unknown, but probably increased pressure in alveolus leads to air leak into mediastinum and subcutaneous tissues [8].

In cases of suspicious and unclear history of foreign body aspiration, high index of suspicion should be considered. Imaging like chest-x-ray is effective tool in diagnosis; however, it may show normal results despite the presence of foreign body [9]. Whether imaging is normal or abnormal, positive history of foreign body aspiration is an indication for bronchoscopy [9,10]. Early diagnosis and proper intervention of PM secondary to foreign body aspiration is critical in preventing life-threatening complications [4].

Spontaneous PM usually resolves with conservative treatments such as O₂, rest and analgesics, but underlying etiologies should always be recognized and treated [1]. Massive PM and SCE with respiratory distress, airway compromise and compression of pulmonary or mediastinal veins require immediate intervention including subcutaneous drains or multiple percutaneous angiocatheters to evacuate the accumulated air [11, 12]. Our patient improved with conservative measures and treatment of the underlying disease, and it was not necessary to use subcutaneous drains or angiocatheters.

In conclusion, our case had PM and SCE that are rare manifestations of FBA. Taking accurate and detailed history for foreign body aspiration is important; hence, the physicians should be aware of these rare presentations and high index of suspicion should be considered for early diagnosis and treatment.

Acknowledgement

We are grateful to the Clinical Research Development Committee of Amirkola Children's Hospital, Babol University of Medical Sciences for their contribution to this study.

Funding: None.

Ethical approval: This study obtained ethics committee of Babol University of Medical Sciences (IR.MUBABOL.REC.1399.220).

Conflict of interest: There was no conflict of interest.

References

1. Bourrous M, Lahmini W, Nouri H, Haimeur N. Subcutaneous emphysema and pneumomediastinum in child with asthma revealing occult foreign body aspiration: a case report. *J Med case report* 2019; 13(1): 1-4.
2. Chiu C-Y, Kin-Sun W, Yao T-C, Jing-Long H. Asthmatic versus non-asthmatic spontaneous pneumomediastinum in children. *Asian Pacific J Allerg Immunol* 2005; 23(1): 19-22.
3. Damore DT, Dayan PS. Medical causes of pneumomediastinum in children. *Clin Pediatr (Phila)* 2001; 40(2): 87-91.
4. Winnie GB, Vemana AP, Haider SK. Pneumomediastinum. In: Kliegman RM, ST Geme JW, Blum NJ. *Nelson Textbook of Pediatrics*. 21th edition. Philadelphia: Elsevier; 2019. 2321.
5. Velecharla MS, Shah KD, Bradoo RA, et al. "AIR LEAK SYNDROME": An Unusual Presentation of Foreign Body in the Airway. *Indian J Otolaryngol Head Neck Surg* 2019; 71(1): 693-5.
6. Yang X-J, Zhang J, Chu P, et al. Pneumomediastinum secondary to foreign body aspiration: clinical features and treatment exploremet in 39 pediatric patients. *Chin Med J* 2016; 129(22): 2691-6.
7. Hammer AR, Schroeder Jr JW. Foreign Bodies in the Airway. In: Kliegman RM, ST Geme JW, Blum NJ. *Nelson Textbook of Pediatrics*. 21th edition. Philadelphia: Elsevier; 2019.2211.
8. Mehta A, Sarin D. Subcutaneous emphysema: an unusual presentation of foreign body bronchus. *Med J Armed Forces India* 2007; 63(1): 71-72.
9. Emami SM, Shurideh Yazdi M, Jafarzadeh Esfehane R. Subcutaneous Emphysema in a Healthy Child: An Unusual Clue for the Diagnosis of Foreign Body Aspiration. *Iran J Neonatol* 2017; 8(3): 75-77.
10. Soysal O, Kuzucu A, Ulutas H. Tracheobronchial foreign body aspiration: a continuing challenge. *Otolaryngol Head Neck Surg* 2006; 135(2): 223-6.
11. Santalla MM, Dacal QR, Velázquez PM. Treatment with subcutaneous drainage in the

pneumomediastinum and massive subcutaneous emphysema. Arch bronconeumol 2013; 49(3): 127.

12. Robinson B. Rapid resolution of severe subcutaneous emphysema with simple

percutaneous angiocatheter decompression. J Surg Case Report 2018, 2018. 7: rjy173.