

A rare presentation of actinomycosis: case report

Case Report

Ahmad Tamaddoni (MD)^{1, 2*}
Sedighe Norouzian (MD)³
Ali Mohammadpour Mir (MD)²
Seyedmohamadreza Tabatabaie (MD)²

1. Associated Professor of Pediatrics
Hematology and Oncology, Non-
Communicable Pediatric Diseases Research
Center, Health Research Institute, Babol
University of Medical Sciences, Babol, IR
Iran.

ORCID ID orcid.org/0000-0002-3684-8754

2. The Clinical Research Development Unit of
Amirkola Children's Hospital, Babol
University of Medical Sciences, Babol, IR
Iran.

3. Resident of Pediatrics, Student Research
Committee, Babol University of Medical
Sciences, Babol, Iran.

* Correspondence:

Ahmad Tamaddoni (MD)
Non-Communicable Pediatric Diseases
Research Center, Health Research Institute,
Babol University of Medical Sciences,
Babol, IR Iran.

E-mail: drtamaddono@yahoo.com

Tel: +98 1132346963

Fax: +98 1132346963

Received: 10 June 2019

Revised: 17 July 2019

Accepted: 25 Aug 2019

Abstract

Background: Anaerobic, nonsporulating, Gram-positive bacteria groups called actinomyces organisms are responsible for the so called actinomycosis. This chronic disease is rare in children and has tendency to mimic many other diseases. It also has wide variety of manifestations and non-specific symptoms. As a result, it is difficult to diagnose before the biopsy and microscopic examination. Although infection may involve any organ in the body, the significant sites of actinomyces infection include cervicofacial, abdominal, pelvic and pulmonary tissues.

Case report: Here, we describe one case of unusual presentation; an 11-year-old girl with a soft tissue mass in the left lower lateral chest wall which was finally diagnosed actinomycosis based on the pathological findings.

Conclusions: Actinomycosis may rarely present with chest wall mass.

Key Words: Actinomyces, Child, Microscopic Examination, Soft Tissue

Citation:

Tamaddoni A, Norouzian S, Mohammadpour-mir A, Tabatabaie SMR. A rare presentation of actinomycosis: case report. *Caspian J Pediatr* Sep 2019; 5(2): 358-61.

Introduction

Anaerobic, nonsporulating, Gram-positive bacteria groups called actinomyces organisms are responsible for the so called actinomycosis. These organisms with filamentous and branching structure are part of the normal flora of the human mouth. Actinomycosis is a chronic, granulomatous and suppurative disease [1]. Actinomycosis usually involves the cervicofacial, thoracic, abdominal or pelvic regions. Actinomycosis occurs among people of all ages, it is more common in males as a result of increased trauma or poorer dental hygiene. In a review of 85 cases of actinomycosis, 27% of them were younger than 20 years of age, and 7% were younger than 10 yrs old [1]. Endogenous flora is almost always the source of human infections. Risk factors in children include local tissue damage caused by trauma, recent surgery (splenectomy) or irradiation, renal or/and lung transplants, alcoholism, use of steroids, HIV, diabetes and leukemia with chemotherapy [2]. Cervicofacial, abdominal, pelvic and pulmonary tissues are the significant sites of actinomyces infection, although may involve any organ in the body [3]. Gram staining of pus of infected tissue is usually more sensitive than culture; therefore it is most commonly used for the diagnosis of actinomyces. After the invasion of actinomyces species to the tissues, they develop a chronic granulomatous inflammation characterized by the formation of tiny clumps with yellow colors, called sulphur granules. These formations have the diameter of about 0.1 to 1mm and are composed of internal tangle of filaments about 1micrometer in diameter and a rosette of peripheral clubs. They are stabilized by a protein-polysaccharide complex that provides a resistance mechanism to host defenses by inhibiting phagocytosis [4-7]. Necrosis and yellowish Sulphur granules as well as filamentous gram positive like fungal pathogens are usual finding in microscopic assessment. Aggregation of bacteria trapped in biofilm formed yellowish Sulphur [8].

These microorganisms are not virulent; therefore, mucosal disruption facilitates invasion of actinomyces. The actinomyces has the capacity to invade surrounding tissues and form masses; hence, it is characterized by a tendency to mimic malignancy [9-10].

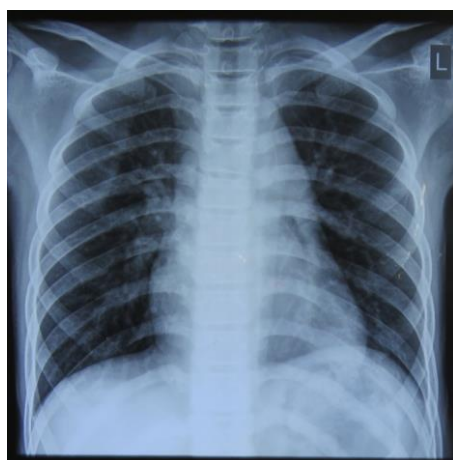
Primary skin and soft-tissue actinomycosis are poorly described [11]. We decided to report a rare presentation of actinomycosis with chest wall mass.

Case Report

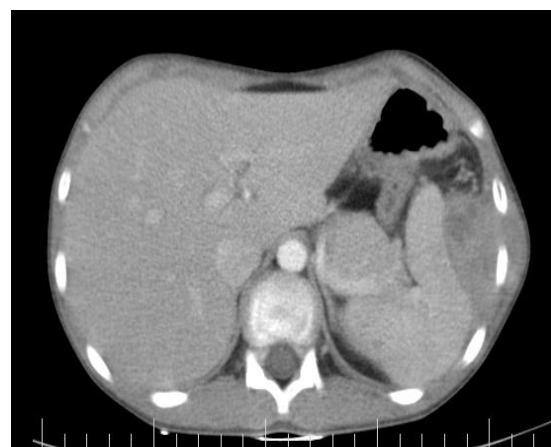The patient was an 11-year-old girl whose parents noticed a mass on her upper left flank 10 days ago. This area has been painful for 2-3 months and there is no history of trauma in this area. She had no fever, night sweats and no tangible weight loss during this period. She was the second child of three children. She was born full term and did not have a specific problem at birth. Her vaccination was done according to the recommended immunization schedule. She had no illness and admission in her past medical history except the forearm fracture following the fall off a bike about 5 years ago. Her parents had no kinship and two other children were healthy. On physical examination, there was a mass with dimensions of 3×4 cm in the left 10th intercostals space at the anterior axillary line, that had no erythema and tenderness and without any secretory discharge. The mass was fixed and firm. There was no lymphadenopathy and organomegaly.

Cardiopulmonary examination was normal. In the paraclinical data, white blood cells count was 10200/mm³ with 67% polymorphonuclear leukocytes, hemoglobin was 11.5 g/dl and platelet was 328000/mm³. Moreover, she had a high ESR (130

mm/h) and high CRP (78 mg/dl). Other biochemistry tests were normal. Her chest radiograph (chest x-ray) was normal. The ultrasound reported a hypoechoic lesion with a size of 3.5 cm×4 cm×5 cm, a smooth and regular border, a parallel placement of the skin surface, a source of intercostal tissue without bone destruction and a compressive effect on the spleen. The performed chest CT scan with contrast showed a mass with heterogeneous density containing hypodensity (possibly necrosis) at the lower part of the left hemithorax, below the lower rib at the anterior axillary line with a compressive effect on the spleen without adhesion to the pleural space and any damages in the adjacent rib(figure 1). PPD (mantoux) test was done to rule out mycobacterium tuberculosis, and the result was negative. The resectional biopsy was conducted to determine the histology. The Pathologist reported a fibro-muscle tissue along with the muscles, which was a fragment of fibrinoleukocytic tissue containing inflammatory cells of lymphocytes and plasma cells as well as a large number of neutrophils and debris. Radial design of acidophilic sections suggested actinomycosis. The evidence of actinomycosis was confirmed by another pathologist who reported the same result. After the resectional biopsy and the report of pathology, she was treated with penicillin G (250000 U/Kg/day divided q 4h) for 2 weeks through IV infusion and then with penicillin V (100 mg/kg/day divided q 6h) orally for 3 months. She was evaluated for rheumatoid arthritis and SLE by ANA. All above tests were negative. At the time of writing this paper and after 12-month follow-up after discharge, no relapse has been seen since completion of treatment course.



a)



b)

Figure 1. a) Chest X ray, b) thoracic computed tomography showing a lesion with heterogeneous density containing hypodensity at the lower part of the left hemithorax, below the lower rib at the anterior axillary line with a compressive effect on the spleen without adhesion to the pleural space.

Discussion

Actinomycosis is rare in children, but we must consider this diagnosis in patients with pseudo-tumor or any inflammation, especially, in chest wall as well as pathological and microbiological studies should be done to prove it [12].

The site of infections is usually at the cervicofacial, thoracic and abdominopelvic and CNS regions [13] In this article, a case of soft-tissue actinomycosis is reported in chest wall. The primary involvement of this anatomical site of lesion in this case was unusual for actinomycosis, while mucosal disruption or tissue damage was needed to lead infection by these microorganisms.

Actinomycosis has been searched in different studies [14-16]. Gomez-Garces JL et al. have reported that the soft-tissue infections include two cases of actinomyces neuii. Both cases were older than 25 yrs. One of them was a 48-year-old woman with an extremely painful mass in the left breast and with 4-day fever before admission. The mass was fluctuating and was associated with skin erythema on physical examination. Ziehl-Neelsen and modified Ziehl-Neelsen stains of samples obtained during surgery were negative. After 48 h of incubation in the special conditions, the microorganism was identified in both cases by staining characteristics as well as morphological and biochemical reactions as Actinomyces neuii [14].

Valour F et al. had ten cases of actinomycosis and found different species of actinomyces, the patients suffered from different clinical features and they had various bacterial cultures and pathologic results for diagnosis. For example, a 61-year-old woman with paraplegia was admitted with a chronic and big scar on her back. MRI indicated soft-tissue infection of the L2 and L4 vertebral bodies. Actinomyces meyer was grown in sample cultures obtained during excision of necrotic tissue by laminectomy [15].

Web WR et al. investigated the CT scan of two patients with actinomyces infection on their chest wall. One case was a 7-year-old girl with a painful mass in her upper right back. Her mother noticed during her bath. This girl had fatigue and loss of appetite in two weeks before admission. Her chest radiography illustrated a large right lower lobe density, and the lung CT scan was performed to evaluate chest wall mass and represented a large homogeneous pulmonary mass with destruction of an adjacent rib, indicating a large lung abscess containing pus and necrotic material.

Actinomyces naeslundii was grown in culture of the lung abscess obtained through open lung biopsy [16].

In the present study, an 11-year-old girl with a mass in left lower lateral chest wall was reported, and the diagnosis was performed based on histopathological findings. However, there was no positive culture of actinomyces which may be due to inappropriate culture conditions or lack of adequate knowledge and skills among the laboratory personnel. Finally, since there are various anatomical sites and manifestations of actinomycosis, further studies on actinomycosis should be done to obtain more knowledge about it and can effectively prevent misdiagnosis.

In Conclusion, as presentation of actinomycosis with soft-tissue mass is a rare in the chest wall; therefore, a mass in an unusual anatomical site, especially, in chest wall should be considered as actinomycosis.

Acknowledgement

We are grateful to the Clinical Research Development Committee of Amirkola Children's Hospital, Babol University of Medical Sciences for their contribution to this study.

Funding: None.

Ethical approval: This study obtained ethics committee of Babol University of Medical Sciences (IR.MUBABOL.REC.1398.031).

Conflict of interest: There was no conflict of interest.

References

1. Jacobs RF, Schutze GE. Actinomyces. In: Kliegman R, Stanton B, Geme J, et al, editors. Nelson textbook of Pediatrics. 20th ed. Philadelphia: Elsevier Saunders; 2016. p. 1352.
2. Procop GW, Pritt B. Pathology of Infectious Diseases E-Book: A Volume in the Series: Foundations in Diagnostic Pathology: Elsevier Health Sciences; 2014.
3. Jacobs RF, Schutze GE. Actinomyces. In: Kliegman R, Stanton B, Geme J, et al. Nelson textbook of Pediatrics. 19th ed. Philadelphia: Elsevier Saunders; 2011. p. 929.
4. Brown JR. Human actinomycosis. A study of 181 subjects. Human Pathol 1973; 4(3): 319-30.

5. Mabeza G, Macfarlane J. Pulmonary actinomycosis. *Europ Respirat J* 2003; 21(3): 545-51.
6. Leo P. Recent developments on the nature of the anaerobic actinomycetes. *Ann Soc belge Méd trop* 1963; 3:247-58.
7. Hotchi M, Schwarz J. Characterization of actinomycotic granules by architecture and staining methods. *Arch Pathol* 1972; 93(5): 392-400.
8. Heffner JE. Pleuropulmonary manifestations of actinomycosis and nocordosis. *Semin Respir Infect* 1988; 3(4): 352-61.
9. Sehouli J, Stupin JH, Schlieper U, et al. Actinomycotic inflammatory disease and misdiagnosis of ovarian cancer. A case report. *Anticancer Res* 2006; 26(2C): 1727-31.
10. Malik A, Papagrigoriadis S, Leather A, et al. Abdominopelvic mass secondary to *Actinomyces israelii* mimicking cancer: report of two cases. *Techniq Coloproctol* 2005; 9(2): 170-1.
11. Veenakumari L, Sridevi C. Actinomycosis in histopathology- Review of literature. *Inter Arch Integrat Med* 2017; 4(9): 195-206.
12. Benammar S, Helardot P, Sapin E, et al. Childhood actinomycosis: report of two cases. *Europ J Pediatr Surg* 1995; 5(3): 180-3.
13. Acevedo F, Baudrand R, Letelier LM, Gaete P. Actinomycosis: a great pretender. Case reports of unusual presentations and a review of the literature. *Inter J Infec Dis* 2008; 12(4): 358-62.
14. Gómez-Garcés JL, Burillo A, Gil Y, Sáez-Nieto JA. Soft tissue infections caused by *Actinomyces neuii*, a rare pathogen. *J Clin Microbiol* 2010; 48(4): 1508-9.
15. Valour F, Sénéchal A, Dupieux C, et al. Actinomycosis: etiology, clinical features, diagnosis, treatment, and management. *Infec Drug Resist* 2014; 7: 183-97.
16. Webb W, Sagel S. Actinomycosis involving the chest wall: CT findings. *American J Roentgenol* 1982; 139(5): 1007-9.